

## Cost-effective-training device for micro-foam Ultrasound-Guided-Sclerotherapy [UGS] for varicose veins.

### Entraînement à la sclérothérapie échoguidée.

Wulf J.<sup>1\*</sup>, Sica M.<sup>2</sup>

#### Résumé

La sclérothérapie échoguidée nécessite de s'entraîner pour traiter les patients avec sécurité et précision tout en respectant leur confort [1]. L'injection échoguidée est un geste qui demande une bonne coordination des mouvements car avec une main il faut tenir la sonde et avec l'autre main, il faut cathétériser la veine à traiter. Il faut faire de nombreuses injections avant d'acquiescer une bonne pratique et sécurité du geste.

Afin d'éviter des accidents en particulier pendant la période d'apprentissage, il faut, tout d'abord, suivre une formation spécifique en phlébologie et en sclérothérapie et ensuite mettre en pratique. Le recours à l'entraînement sur simulateur (poster page de gauche) constitue la manière la plus efficace d'acquiescer les bons gestes. De nouveaux modèles de simulateurs, de plus en plus abordables, arrivent sur le marché. Ils permettront aux étudiants et ou aux spécialistes qui souhaitent se former ou se perfectionner à l'échoguidage de le faire dans des conditions très proches de la réalité.

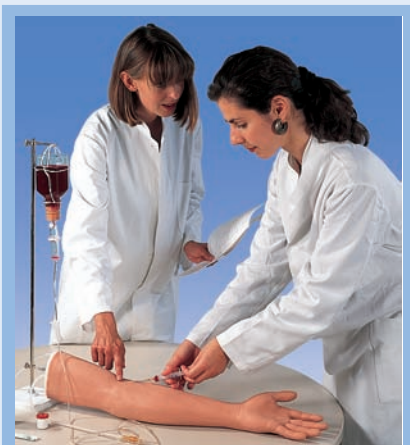Le modèle de simulateur présenté sur le poster n'est pas encore commercialisé car il s'agit d'un prototype [2].

#### Introduction

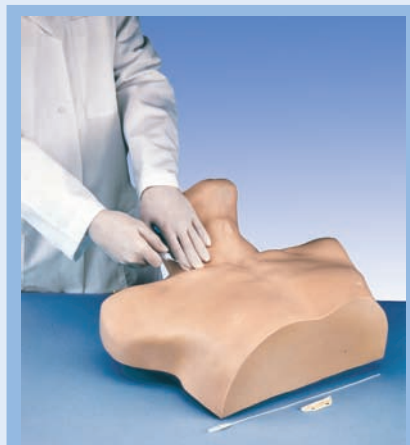Actually in a lot of clinical therapies and diagnoses, percutaneous intravascular techniques are required. For this purpose thin vascular devices (e.g. needles and catheters) are inserted into the soft tissue (skin) in order to reach adjacent anatomical targets (e.g. vessels).

In the clinical practice several applications and techniques occur, where percutaneous insertion is to be performed, such as blood sampling [1], central vein cannulation [2] and ultrasound guided sclerotherapy [3]. Needle misplacement may be due to anatomical uncertainty and human errors (inexperience, lack of skill). In percutaneous intravascular procedures the target (vein) might be situated very close to other anatomical structures like arteries and nerves hence misplacement may result in fatal complications [4].

According to the current literature there is evidence that UGS with foam was effective in the treatment of complicated and uncomplicated varicose veins [5]. This technique is minimal invasive, save and cost-effective. However in order to achieve an optimal outcome and to minimize complications an appropriate amount of skill and training is required. The use of ultrasound guidance improves the accurate placement of the needle in the desired vein by mapping of the vessels including arteries located close to the target vein.



**FIGURE 1 :** Simulator for training of blood sampling.



**FIGURE 2 :** Simulator for training of central vein cannulation.

1. 3B Scientific GmbH, Hamburg, Germany.

2. Deputy General Secretary of French Society of Phlebology, 5, rue de Crussol, 75011 Paris.

\* Corresponding author contact : [Joerg.Wulf@3bscientific.com](mailto:Joerg.Wulf@3bscientific.com)

Cost-effective-training device for micro-foam Ultrasound-Guided-Sclerotherapy [UGS] for varicose veins.

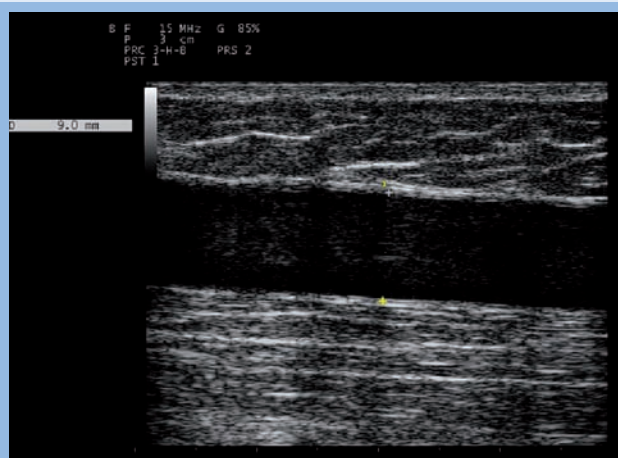
For this purpose a high frequency probe (10-13 MHz) is required with echographic sections either transversal or longitudinal. However, effective application of ultrasound guided techniques requires knowledge and experience of ultrasonography and furthermore a good hand-eye coordination. The aim of this project was to develop a cost-effective training device to improve the acquisition of pre-clinical skills of trainees for micro-foam ultrasound guided sclerotherapy for varicose veins.

### Method

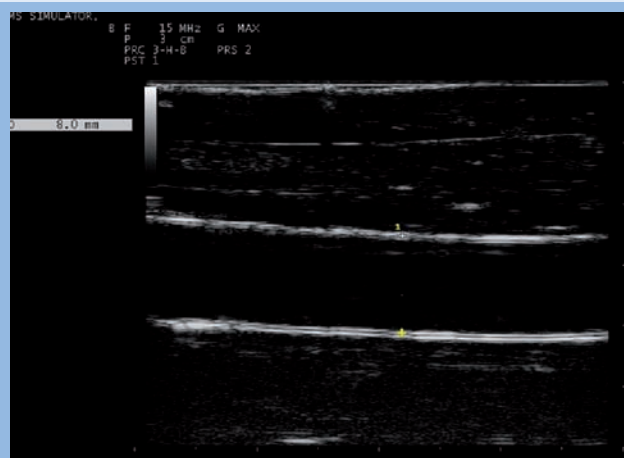
To meet the requirements of appropriate commercially available material that mimics the ultrasound specific echogenic characteristics of soft tissues (skin, veins), laboratory investigation was performed. Furthermore mechanic properties were taken into account with respect to resilience and elasticity of anatomical areas of interest dedicated for simulation of UGS procedure. The development process of training device was supervised by a clinically experienced phlebologist (20 years of experience, about 40000 UGS procedures performed in his career). For the training device commercially available thermoplastic elastomeric tubes with an outer diameter of ~ 9 mm and thickness of wall of ~ 0, 2 mm are used (for simulation of the vessel). Furthermore a two component low viscous elastomeric silicone is used as embedding compound for the tubes. For this purpose the two components are thoroughly mixed using a low speed pneumatic mixer to minimise the introduction of air according to the specifications of the manufacturer. The different diameter elastic tubes are attached to the board of a mold by pins, which are to be removed after polymerisation of the silicon. When the silicone is ready for pouring, it is transferred into the mold as mentioned above. In the training device the embedded elastic tubes allow fluid flow through the model. At the end of the elastic tubes standard infusion lines with three-way stopcocks are connected. An infusion bag is filled with artificial blood and venous blood simulation can be performed. This device was used to verify its value of the hands on training of USG and furthermore to estimate the need and feasibility of a commercially available cost-effective-training device.

### Results

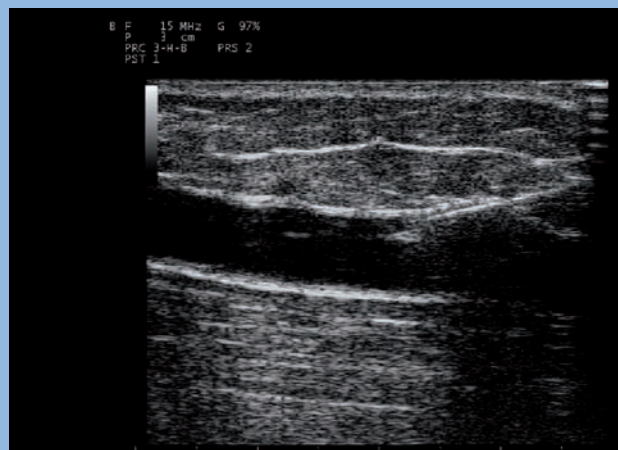
According to the assessment of an experienced phlebologist, who performed simulated UGS on the training device, ultrasound appearance of the target vein was represented well and realistic in the transversal as well as in the longitudinal scan.



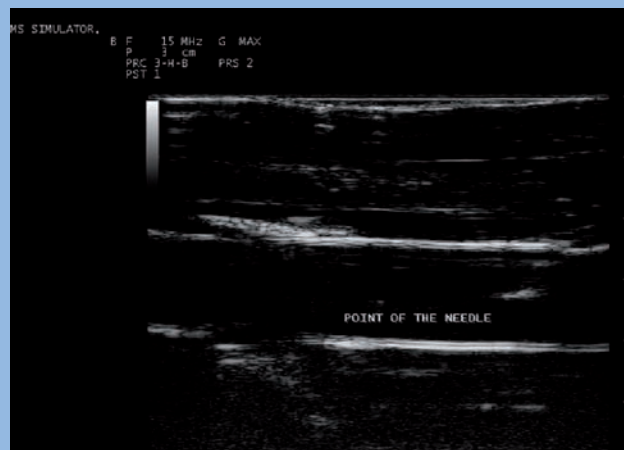
**FIGURE 3 :** Ultrasound appearance of great saphenous vein (GSV), longitudinal scan.



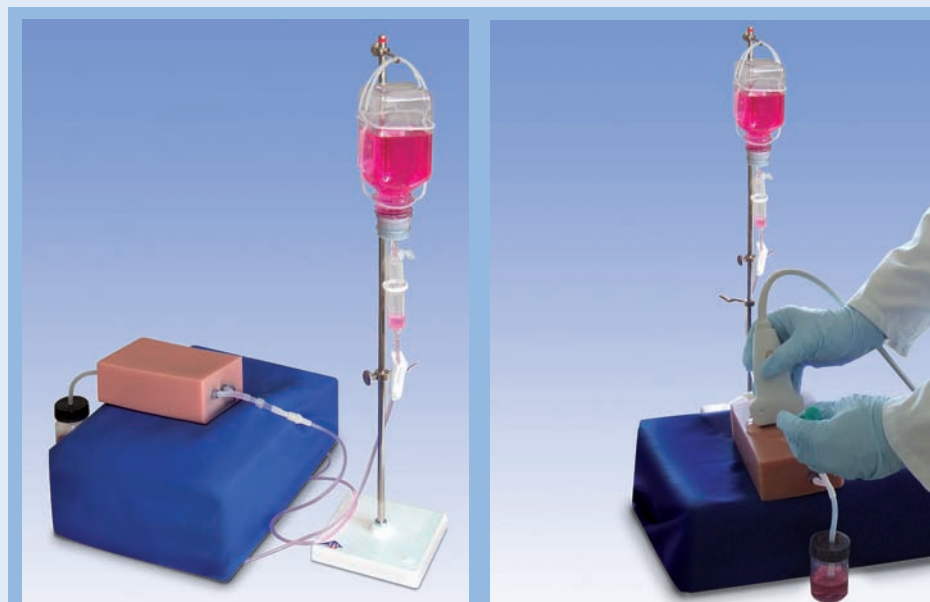
**FIGURE 4 :** Ultrasound appearance of simulated vessel (tube) within the training device, longitudinal scan.



**FIGURE 5 :** Ultrasound appearance of tip of needle within the lumen of great saphenous vein (GSV), longitudinal scan.



**FIGURE 6 :** Ultrasound appearance of tip of needle within the lumen of simulated vessel (tube), longitudinal scan.



**FIGURE 7 :** *Prototype of a simulator for ultrasound-guided sclerotherapy.*

The needle insertion into the lumen of target vein could be performed successfully. It was inserted into the middle of the probe from various angles the surface of the training device. The position of the tip was assessed by raking the needle back and forth and moving the probe in various directions.

The correct position was verified by visible reflux of fluid (artificial Blood) through the needle into the syringe during performed aspiration. Furthermore after the injection of sclerosing agent micro bubbles of foam were hyperechogenic and represented a good contrast in the ultrasound scans, and appeared as a «cloud» in the simulated vessel. The training device was cleaned by a flow of water (filled into the infusion bag) through the infusion line and embedded tubes, to be ready for the next training session.

## Conclusion

Skill in ultrasonography is a condition sine qua non in the technique of ultrasound guided cannulation of vessels [6]. The visualisation of the needle provides control of the tip position of the needle, whereas inaccurate puncture may cause major complications. In the training of UGS an affordable and appropriate training device may help to improve basic procedure before it is performed on a patient. Further validation and evidence of how simulator based training of UGS will improve skills of trainees in supervised training sessions, will be the focus of further investigation.

## References

1. Sica M. Guide pratique illustré pour réussir les traitements par sclérothérapie échoguidée à la mousse. Éditions Editcrea, 2009.
2. Wulf J., Sica M. Cost-effective-training device for micro-foam Ultrasound Guided Sclerotherapy [UGS] for varicose veins. Poster presentation in XVIth World Congress of the International Union of Phlebology. Monaco. August 31st -September 4th, 2009.
3. Zivanivic A., Davies B.L. A robotic system for blood sampling. IEEE Trans. Inform. Technol. Biomed. 2000 ; 4 (1) : 8-14.
4. Di Domenico S., Santori G., Porcile E. Inexpensive homemade models for ultrasound guided vein cannulation training. Journal of Clinical Anesthesia 2007 ; 19 : 491-6.
5. Barret J.M., Bruce A., Ockelford A., et al. Microfoam Ultrasound- Guided Sclerotherapy of Varicose Veins in 100 legs. Dermatol. Surg. 2004 ; 30 : 6-12.
6. Kohn L.T. et al. To Err is human: building a safer health system. New York : Nat. Acad ; 2000.
7. O'Hare A., Parkin D., Vandebroek C.P., Earnshaw. Mid Term Results of Ultrasound guided Foam Sclerotherapy for Complicated and Uncomplicated Varicose Veins. Eur. J. Vasc. Endovasc. Surg. 2008 ; 36 : 109-13.
8. Mey U., Glasmacher A., Hahn C., et al. Evaluation of an ultrasound-guided technique for central venous access via internal jugular vein in 493 patients. Support. Care Cancer 2003 ; 11 : 148-58.

Nous remercions la société 3B Scientific d'Hambourg (Allemagne) et en particulier le D<sup>r</sup> J. Wulf de nous avoir permis de publier ce poster et leur prototype de simulateur, présenté lors du XVI<sup>e</sup> Congrès Mondial de Phlébologie de l'UIP à Monaco.