



Chapitre 16



EHITs and thrombotic extensions

Matthieu Josnin

Summary

The thrombotic extensions after sclerotherapy or thermal removal of varicose veins are known for a long time but to date there is no real standard of practices regarding their treatment. This chapter aims at, after a summary of the recommendations, describing the ultrasonic aspects of these extensions as well as their becoming and treatment.

Thrombotic extension from the great saphenous vein (GSV) into the common femoral vein (CFV), or from the small saphenous vein (SSV) into the popliteal vein, is a known complication in patients treated by endovenous thermal ablation (Radiofrequency or Laser) for varicose veins of the lower extremities; this extension is referred to in the literature by Kabnick in 2005 as Endovenous Heat-Induced Thrombosis (EHITs) [1].

After ultrasound-guided sclerotherapy treatment, thrombotic extensions into the deep venous segment in continuity with the treated segment are also likely to occur, they are called Endovenous Foam-Induced Thrombosis (EFITs) [2].

The pathophysiology and risk factors leading to these thrombotic extensions are yet to be fully defined.

A retrospective study by O'Donnel, published in 2015, showed that thrombotic complications occurred in:

- 4.4% of patients treated with radiofrequency (RF)
- 3.1% with Endovenous Laser (EVL)
- 0.8% by sclerotherapy
- and 2.4% by surgery [3].

Recommendations

Thermal Ablation

- Following a thermal endovenous procedure, the Haute Autorité de Santé (French health Authority abbreviated HAS), report of April 2008 on radiofrequency occlusion of the great saphenous vein states: "According to the members of the working group, ultrasound examination is recommended within 10 days after the occlusion procedure of the GSV by

radiofrequency (high approval). The objective of this ultrasound examination is to check the effectiveness of the endovascular procedure and to ensure the absence of thrombotic phenomena" [4].

- Recommendations for EVL and RF thermal ablation have been published in the United Kingdom and the United States [5, 6, 7, 8]:
 - Only the American recommendations propose performing a low-grade ultrasound check 24 to 72 hours after the procedure to eliminate any thrombotic complications (grade 2C).
 - The NICE (United Kingdom) does not specifically address this subject.
- The Guidelines of the First International Consensus Conference on Endovenous Thermal Ablation for Varicose Vein Disease - ETAV Consensus Meeting 2012, recommend [9]:
 - A "security" check-up 10 days after the procedure,
 - A second check 3 to 6 months after the procedure for evaluation of the results.

Recommendation 25:

- We recommend at least two follow-up visits (GRADE 1C):
- A clinical follow-up and a DVT scan within 10 days.
 - A clinical and duplex review of treatment results within 3-6 months.

Marsh et al. reported that the rates of deep vein thrombosis (DVT) and EHITs are similar and low in patients treated with RF or EVL, but post-procedural ultrasound monitoring is still required for these patients as long as knowledge on EHITs remains limited [10].

Gillet et al. showed that the level of DVT after ultrasound guided foam sclerotherapy of the small saphenous vein was low and that ultrasound monitoring remained

EHITs and thrombotic extensions.

justified 1 to 2 weeks after the procedure only in patients with medial gastrocnemius vein perforators and those whose small saphenous vein was directly connected to the popliteal vein [11].

Lawrence suggests a systematic ultrasound exam to be performed 48/72 hours after surgery, except for patients with no history of DVT, or whose GSV diameter is less than 8 mm at the saphenofemoral junction (SFJ) [12].

For Jones and Kabnick, performing an ultrasound examination on the days following endovenous thermal treatment of the saphenous veins is not justified in asymptomatic patients [13].

Sclerotherapy

There are no international recommendations for systematic DUS examination [14].

In France, the Agence Nationale de Sécurité du Médicament (National Agency for Drug Safety abbreviated ANSM), in the Summaries and Product Characteristics (SPC) of Aetoxisclérol® and Fibrovein®, recommends a clinical and DUS examination at least one month after the procedure.

For the ANSM, the objective of this check-up is twofold: to check the result of the effectiveness of the procedure but also the absence of side effects, including of course DVT [15-16].

Endovenous Heat-Induced Thrombosis (EHIT)

This chapter describes the ultrasound diagnosis of EHITs in patients consulting 8 to 10 days after a thermal venous ablation procedure for GSV or SSV.

The ultrasound examination is preferably performed with a high frequency linear probe, (a microconvex probe may also be used), in a patient lying (GSV/SSV) or sitting (SSV) position.

EHITs after thermal ablation of the Great Saphenous Vein

Kabnick was, in 2005 [1], the first to introduce and classify EHITs into 4 classes.

This description applies to the saphenofemoral junction (SFJ) (Table 1, Fig. 1).

In 2010 Peter F. Lawrence [12] proposed a classification according to 6 occlusion levels, taking into account the relationship with the epigastric vein and the common femoral vein (CFV) (Fig. 2).

Table 1: Endovenous heat-induced thrombosis classification according to Kabnick.

Class	Thrombus extension
1	At the deep and superficial venous network junction.
2	Extension beyond the junction with a cross-section diameter of less than 50%.
3	Extension beyond the junction with a cross section diameter greater than 50%.
4	Deep vein thrombosis occlusive.

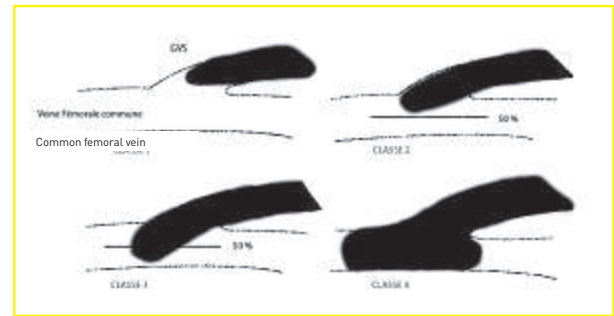


Fig. 1: Illustrating the classification of EHITs according to Kabnick.

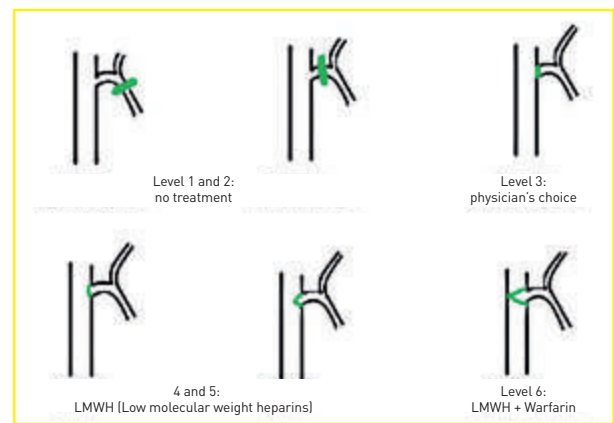


Fig. 2: Classification of the occlusion level of the great saphenous vein with corresponding treatment according to Lawrence.

The following picture (Fig. 3) illustrates, according to Lawrence's classification, a level 4 with thrombus protrusion in the FV, less than 50% (red squares); note the position of the thrombus in relation to the epigastric vein (arrow).

In the Kabnick series, the incidence of EHITs is 2.9%, while it is 2.6% for Lawrence.

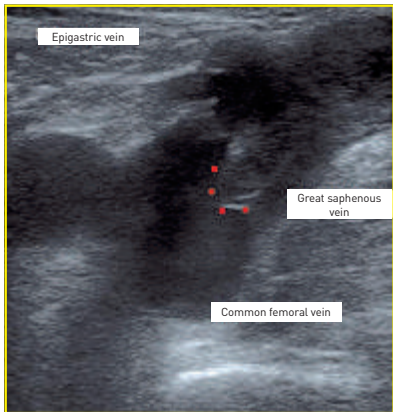


Fig. 3: EHIT level 4 according to Lawrence, check-up 8 days after endovenous thermal ablation of GSV.

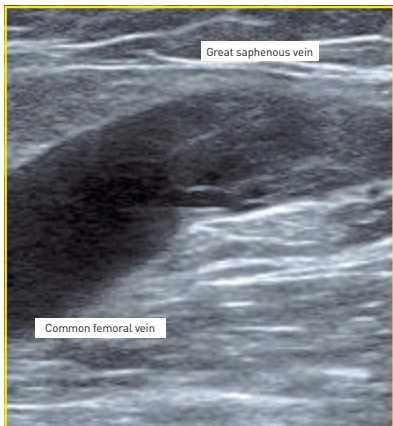

Fig. 4: EHIT level 1, check-up 10 days after endovenous thermal ablation of GSV.

© Docteur Sébastien Gracia

Sufian [17] demonstrated a 2.9% prevalence of EHITs in a series of 6,707 patients treated with RF. In 58.7% of the cases, the EHITs were class 1 (Kabnick classification), 32% were class 2, 9% were class 3 and only 0.5% were class 4.

The photo below (**Fig. 4**) shows a type 1 EHIT, there is no heat-induced thrombus protrusion in the femoral vein.

EHITs after thermal ablation of the Small saphenous vein

There are numerous publications concerning EHITs following the treatment of GSV; on the other hand, few publications are found for SSV. Harlander-Lock et al. described a classification and algorithm for monitoring and processing the saphenopopliteal junction [18] (**Fig. 5**).

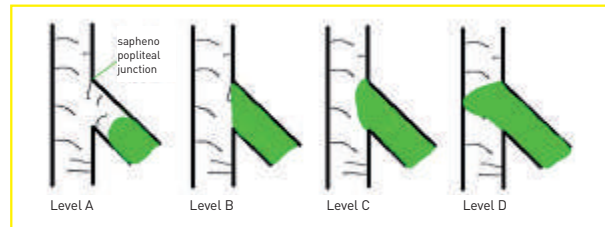


Fig. 5: Classification of the occlusion level at the sapheno-popliteal junction following radiofrequency treatment of SSV according to Harlander-Lock.
 - Level A and B: no treatment;
 - Level C: physician's choice;
 - Level D: LMWH : low molecular weight heparins + Warfarin

Drawing a parallel with SFJ and the consideration of the epigastric vein in the occlusion level, Gibson suggests that the presence of a Giacomini vein could protect against heat-induced thrombus development in the popliteal vein [19].

EHITs: evolution and treatment

Evolution

For Kabnick, in a short time (less than 24 hours), the heat-induced thrombus quickly becomes echogenic, whereas a thrombus found during spontaneous DVT is rather hypo to isoechoic for several days or weeks [20]. He also notes that induced thrombus rapidly becomes stable and usually regresses in 10 to 14 days.

In 2006 Kabnick had already reported this notion of more echogenic thrombus when it came to EHITs. At that time Kabnick noted the lack of systemic coagulation activation in these patients [21]. EHITs become echogenic in less than 24 hours according to him.

The following figures (**Figs. 6 and 7**) clearly show this difference in echogenicity. Figure 6 corresponds to a segment treated by radiofrequency; the control having been carried out 8 days after the procedure whereas Figure 7 shows a thrombus clearly more hypo-echogenic found in a patient who had had calf pain for 10 days following a prolonged trip by car and for whom a gastrocnemius venous thrombosis was diagnosed.

Santin et al. described, in 2013 [22], the differences in histological and ultrasound characteristics of de novo thrombus (from spontaneous DVT) and those of heat-induced thrombus. Apart from an obvious histological difference, it shows a more marked hyperechogenicity of the thrombus from the EHITs. This hyperechogenicity could be related to a more pronounced fibroblastic reaction and edema, which is consistent with Kabnick's descriptions.

EHITs and thrombotic extensions.

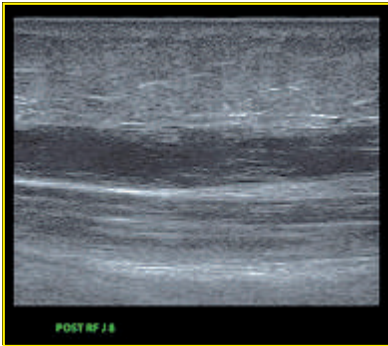


Fig. 6: Great saphenous vein at Day 8 after radiofrequency treatment.

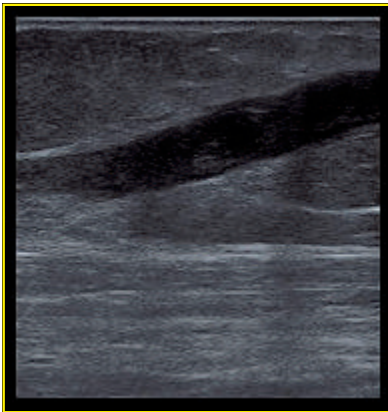
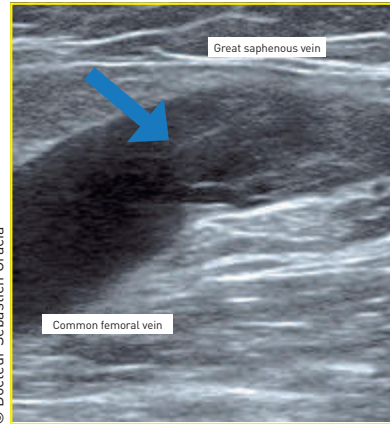


Fig. 7: Gastrocnemius venous thrombosis.



© Docteur Sébastien Gracia

Fig. 8: EHIT at the inspection of the saphenofemoral junction 8 days after an RF procedure.

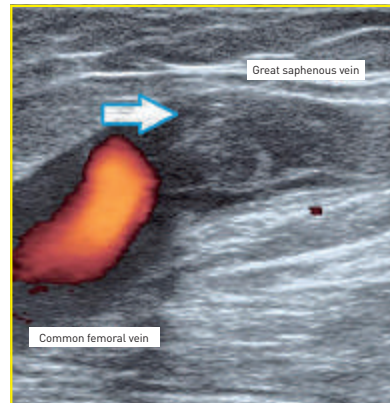


Fig. 9: EHIT at the inspection of the saphenofemoral junction 15 days after the RF procedure.

In the following example, the patient was examined 8 days after RF. A class 1 EHITs is highlighted (**Fig. 8**). This patient being asymptomatic, it is simply decided to check him again 8 days later (**Fig. 9**). During this new examination, 15 days after the procedure, the patient remaining asymptomatic, we notice a more hyperechoic aspect of the thrombus (arrows).

Treatment

There is no real consensus. For Kabnick the following algorithm may be proposed (**Fig. 10**) [20, 23]:

Kabnick offers an 8-day ultrasound check of the endovenous procedure.

- If a class 1 EHIT is diagnosed then the patient will be checked every 7-10 days until regression.
- A class 2 EHIT will be treated with low molecular weight heparins (LMWH) for 10-14 days with subsequent control. In case of regression the treatment is interrupted otherwise it is continued.
- Class 3 and 4 EHITs must be treated as DVT in accordance with the guidelines of the American College of Chest Physician [24].

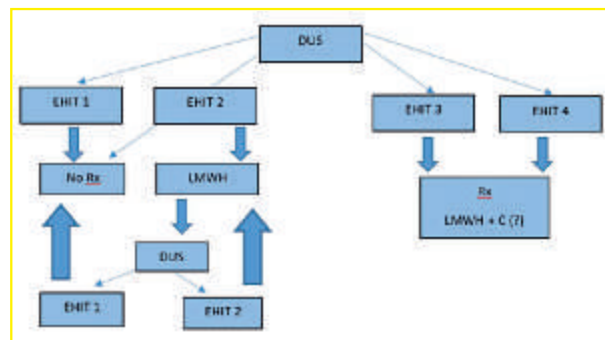


Fig. 10: EHIT processing algorithm proposed by Kabnick.
 - DUS = Duplex Ultrasound;
 - LMWH = low molecular weight heparins;
 - C = Coumadine;
 - No Rx = No prescription.

For others like Sermsathanasawadi, class 2 EHITs were resolved in 2 weeks without further treatment. Class 3 EHITs were treated with oral anticoagulants and disappeared between 2 and 6 weeks [25].

Concerning thromboprophylaxis, North American guidelines recommend the introduction of one in patients at risk, such as those with biological or clinical thrombophilia or obesity [8].

Lawrence reports an additional risk of EHITs in patients with a GSV diameter greater than 8 mm [12].

Sadek et al. demonstrated that an increase in RF or EVL fiber distance greater than or equal to 2.5 cm allowed a significant decrease in class 2 EHITs [23].

Another study published in 2016, involving 67 patients who underwent endovenous radiofrequency ablation of the GSV, showed that the positioning of the RF probe should be between 2 and 2.5 cm from the SFJ to reduce the incidence of EHITs [26].

Sex, age, Caprini score, complementary phlebectomies, presence of venous ulcer(s) could also be risk factors [27-28].

A recent study conducted by Shutze showed that the use of a 1,470 nm wavelength Laser fiber fibers reduced the incidence of EHITs compared to 810 nm fibers [29].

Endovenous Foam-Induced Thrombosis (EFIT)

For EFITs, a classification has also been established allowing the introduction of therapeutic measures according to the level of extension [2] (**Fig. 11**).

Unlike endovenous thermal ablation procedures, no systematic DUS examination is recommended by the European Guidelines [14] following treatment with sclerotherapy.

An ultrasound examination can be performed during a second appointment agreed with the patient (continuation of treatment), or at the request of the patient/ or his general practitioner, in case of unusual pain occurring after sclerotherapy.

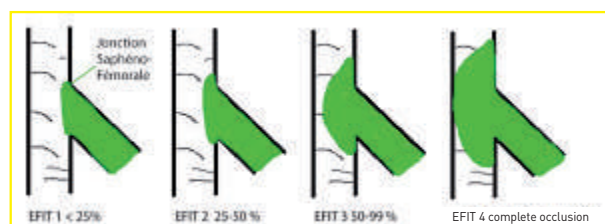


Fig. 11: Endovenous foam-induced thrombosis (EFITs) according to Kulkarni. The percentage corresponds to the level of thrombus progression in the femoral vein.

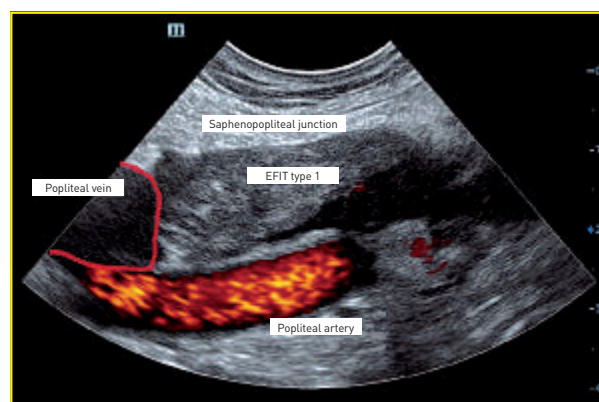


Fig. 12: EFIT type 1, seven days after ultrasound-sclerotherapy with foam of a SSV.

© Docteur Sébastien Gracia

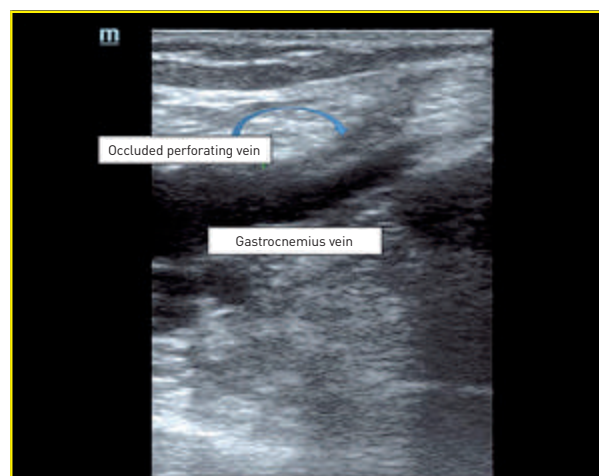


Fig. 13: EFIT 5 days later echo-sclerotherapy with foam of a SSV's tributary.

The ultrasound examination will preferably be performed with a high frequency linear probe, (a microconvex probe may also be used), in a patient lying or sitting depending on the area explored.

The ultrasound images are essentially the same as those described during endovenous thermal ablation.

The thrombotic extension is initially iso to hypoechoic and may be "mobile". Here too it is often observed that this extension rapidly becomes hyperechoic (**Fig. 12**).

Thrombotic extensions may well occur following treatments performed on GSV or SSV tributaries, but also during the treatment of any venous segment.

The following example (**Fig. 13**) shows a thrombotic extension EFIT during the treatment of a SSV reflux tributary

EHITs and thrombotic extensions.

vein fed by a perforating vein. There is a partial occlusion of the perforating vein with extension on the first centimeters of a medial gastrocnemius vein. In this case the patient had consulted for walking pain a few days after the sclerosis. The pressure against the occluded perforator was painful.

The treatment of EFITs also remains unclear.

- Kulkarni in 2013 wrote that class 1 and 2 EFITs could simply be treated with venous compression and aspirin, class 3 and 4 EFITs could be treated with Warfarin and venous compression from 6 to 12 months [2].
- Concerning monitoring, Gillet *et al.* demonstrated that the rate of deep venous thrombosis after ultrasound-guided foam sclerotherapy of the small saphenous vein was weak and that ultrasound monitoring was only justified 1 to 2 weeks after the procedure in patients with medial gastrocnemius vein perforators and those whose small saphenous vein was directly connected to the popliteal vein [30].

Conclusion

The possible occurrence of thrombotic extensions after sclerotherapy, thermal ablation or varicose vein surgery has long been known, but their ultrasound search was most often triggered only in the event of signs of a clinical call.

With increasingly efficient ultrasound scanners, a better knowledge of venous disease, and because endovenous varicose vein treatments are performed by ultrasound experts, we are entering an era of "hyper-exploration" and "hyper-documentation" of ultrasound imaging in phlebology.

This has led to the EHITs and EFITs, which, we must bear in mind, only correspond to descriptions of ultrasound images.

While we can welcome this improvement in knowledge, we must nevertheless retain all our clinical sense and our analytical capacities. Indeed, an outrageous and overly alarmist interpretation of images could lead to an inadequate complexity in the management of the consequences of procedures, and to "over-treatments" by anticoagulants, the latter not being themselves without risks.

In 2014, a literature review on the incidence of thromboembolic events after endovenous heat and sclerotherapy treatment with foam of the great saphenous veins showed a lack of standardization concerning ultrasound monitoring after endovenous ablation procedures [31].

Bibliography

- [1] Kabnick LS, Agis H, Moritz M, Giorgio S, et al. Endovenous heat induced thrombus (EHIT) following endovenous vein obliteration: to treat or not to treat? A new thrombotic classification. In: 3rd International Vein Congress; 2005. Miami, FL. April 14-16, 2005.
- [2] Kulkarni SR, Messenger DE, et al. The incidence and characterization of deep vein thrombosis following ultrasound-guided foam sclerotherapy in 1000 legs with superficial venous reflux. *J Vasc Surg Venous Lymphat Disord.* 2013; 1-3: 231-238.
- [3] O'Donnel TF, Eaddy M, Raju A, et al. Assessment of thrombotic adverse events and treatment patterns associated with varicose vein treatment. *J Vasc Surg.* 2015; 3: 27-34.
- [4] Occlusion de grande veine saphène par radiofréquence par voie veineuse transcutanée. Actualisation du rapport de 2008. Décembre 2013. http://www.has-sante.fr/portail/upload/docs/application/pdf/2013-12/rapport_radiofreq_vd.pdf
- [5] Varicose veins in the legs. The diagnosis and management of varicose veins. NICE clinical guideline, <https://www.nice.org.uk/guidance/cg168>
- [6] Endovenous laser treatment of the long saphenous vein. NICE interventional procedure guidance 52. March 2004. <https://www.nice.org.uk/guidance/ipg52>
- [7] Radiofrequency ablation of varicose veins. NICE interventional procedure guidance 8. September 2003. <https://www.nice.org.uk/guidance/ipg8>
- [8] Glaviczki P, Camerota AJ, Dalsing MC, et al. The care of patients with varicose veins and associated chronic venous diseases: Clinical practice guidelines of the Society for Vascular Surgery and American Venous Forum. *J Vasc Surg.* 2011; 53 (5): 2S-48S.
- [9] Pavlovic MD, Schuller-Petrovic S, Pichot O, Rabe E, Maurins U, Morrison N, et al. Guidelines of the First International Consensus Conference on Endovenous Thermal Ablation for Varicose Vein Disease - ETAV Consensus Meeting 2012. *Phlebology* 2015 May; 30(4): 257-273.

- [10] Marsh P, Price BA, Holdstock J, Harrison C, Whiteley MS. Deep vein thrombosis after venous thermoablation techniques: rates of endovenous heat-induced thrombosis (EHIT) and classical DVT after radiofrequency and endovenous laser ablation in a single center. *Eur J Endovasc Surg.* 2010 Oct; 40(4): 521-7.
- [11] Gillet JL, Lausecker M, Sica M, Guedes JM, Allaert FA. Is the treatment of the small saphenous veins with foam sclerotherapy at risk of deep vein thrombosis? *Phlebology* 2014; 29(9): 600-607.
- [12] Peter F, Lawrence, Chandra A, Wu M, et al. Classification of proximal endovenous closure and treatment algorithm. *J Vasc Surg.* 2010; 52(2): 388-393.
- [13] Jones RT, Kabnick LS. Perioperative duplex ultrasound following endothermal ablation of the saphenous vein: is it worthless? *J Invasive Cardiol.* 2014 Oct; 26(10): 548-50.
- [14] Rabe E, Breu FX, Cavezzi A, Coleridge Smith P, Frullini A, Gillet JL, Guex JJ, Hamel-Desnos C, Kern P, Partsch B, Ramelet AA, Tessari L, Pannier F, and for the Guideline Group. European guidelines for sclerotherapy in chronic venous disorders. *Phlebology* 2014 July; 29(6): 338-354, first published on May 3, 2013.
- [15] Résumé des caractéristiques du produit : AETOXISCLEROL, ANSM, 01/07/2013. <http://agence-prd.ansm.sante.fr/php/ecodex/rcp/R0225040.htm>
- [16] Résumé des caractéristiques du produit : FIBROVEIN, ANSM, 12/12/2013. <http://agence-prd.ansm.sante.fr/php/ecodex/rcp/R0233685.htm>
- [17] Sufian S, Arnez A, Labropoulos N, Lakhanpal S. Incidence, progression, and risk factors for endovenous heat-induced thrombosis after radiofrequency ablation. *J Vasc Surg.* 2013; 1(2): 159-164.
- [18] Harlander-Locke M, Jimenez J C, Lawrence P F, et al. Management of endovenous heat-induced thrombus using a classification system and treatment algorithm following segmental thermal ablation of the small saphenous vein. *J Vasc Surg.* 2013; 58(2): 427-432.
- [19] Gibson KD, Ferris BL, Polissar N, Neradilek B, Pepper D. Endovenous laser treatment of the small saphenous vein: efficacy and complications. *J Vasc Surg.* 2007; 45(4): 795-801.
- [20] Kabnick LS, Berland TL. Endothermal Heat Induced Thrombosis (EHIT) Presented at the 38th Annual Vascular and Endovascular Issues, Techniques and Horizons, November 16-20, 2011, New York City.
- [21] Kabnick LS. Complications of endovenous therapies: statistics and treatment. *Vascular* 2006; 14: S31-S32.
- [22] Santin BJ, Lohr JM, Panke TW, Neville PM, Felinski MM, Kuhn BA, Recht MH, Muck PE. Venous duplex and pathologic differences in thrombus characteristics between de novo deep vein thrombi and endovenous heat-induced thrombi. *J Vasc Surg Venous Lymphat Disord.* 2015; 3(2): 184-189.
- [23] Sadek M, Kabnick L S, Rockman C B, Berland T L, Zhou D, Chasin C, Jacobowitz G R, and Adelman M A. Increasing ablation distance peripheral to the saphenofemoral junction may result in a diminished rate of endothermal heat-induced thrombosis. *J Vasc Surg Venous Lymphat Disord.* 2013 Jul; 1(3): 257-262.
- [24] Hirsh J, Guyatt G, Albers GW, Harrington R, Schunemann HJ. Executive summary: American College of Chest Physicians. Evidence-Based Clinical Practice Guidelines (8th Edition). *Chest.* 2008 Jun; 133(6 Suppl): 71S-109S.
- [25] Sermsathanasawadi N, Tsz Yin Voravitvet, Chinsakchai K, Wongwanit C, Ruangsetakit C, Mutirangura P. Risk factors for endovenous heat-induced thrombosis after endovenous radiofrequency ablation performed in Thailand. *Phlebology* 2015 Jul; 31: 1-6.
- [26] Ahn S, Jung IM, Chung JK, Lee T. Changes in Saphenous Vein Stump and Low Incidence of Endovenous Heat-Induced Thrombosis After Radiofrequency Ablation of Great Saphenous Vein Incompetence. *Dermatol Surg.* 2016 Apr; 42(4): 515-520.
- [27] Spreafico G, Kabnick L, Berland TL, Cayne NS, Maldonado TS, Jacobowitz GS, Rockman CR, Lamparello PJ, Baccaglini U, Rudarakanchana N, Adelman MA. Laser saphenous ablations in more than 1,000 limbs with long-term duplex examination follow-up. *Ann Vasc Surg.* 2011 Jan; 25(1): 71-8.
- [28] Benarroch-Gampel J, Sheffield KM, Boyd CA, Riall TS, Killewich LA. Analysis of venous thromboembolic events after saphenous ablation. *J Vasc Surg Venous Lymphat Disord.* 2013 Jan; 1(1): 26-32.
- [29] Shutze WP, Kane K, Fisher T, Doud Y, Lassiter G, Leuking R, Nguyen E, Shutze WP Jr. The effect of wavelength on endothermal heat-induced thrombosis incidence after endovenous laser ablation. *J Vasc Surg Venous Lymphat Disord.* 2016 Jan; 4(1): 36-43.
- [30] Gillet JL, Lausecker M, Sica M, Guedes JM, Allaert FA. Is the treatment of the small saphenous veins with foam sclerotherapy at risk of deep vein thrombosis? *Phlebology* 2014; 29(9): 600-607.
- [31] Dermody M, Schul MW, O'Donnell TF. Thromboembolic complications of endovenous thermal ablation and foam sclerotherapy in the treatment of great saphenous vein insufficiency. *Phlebology* 2015; 30(5): 357-364.