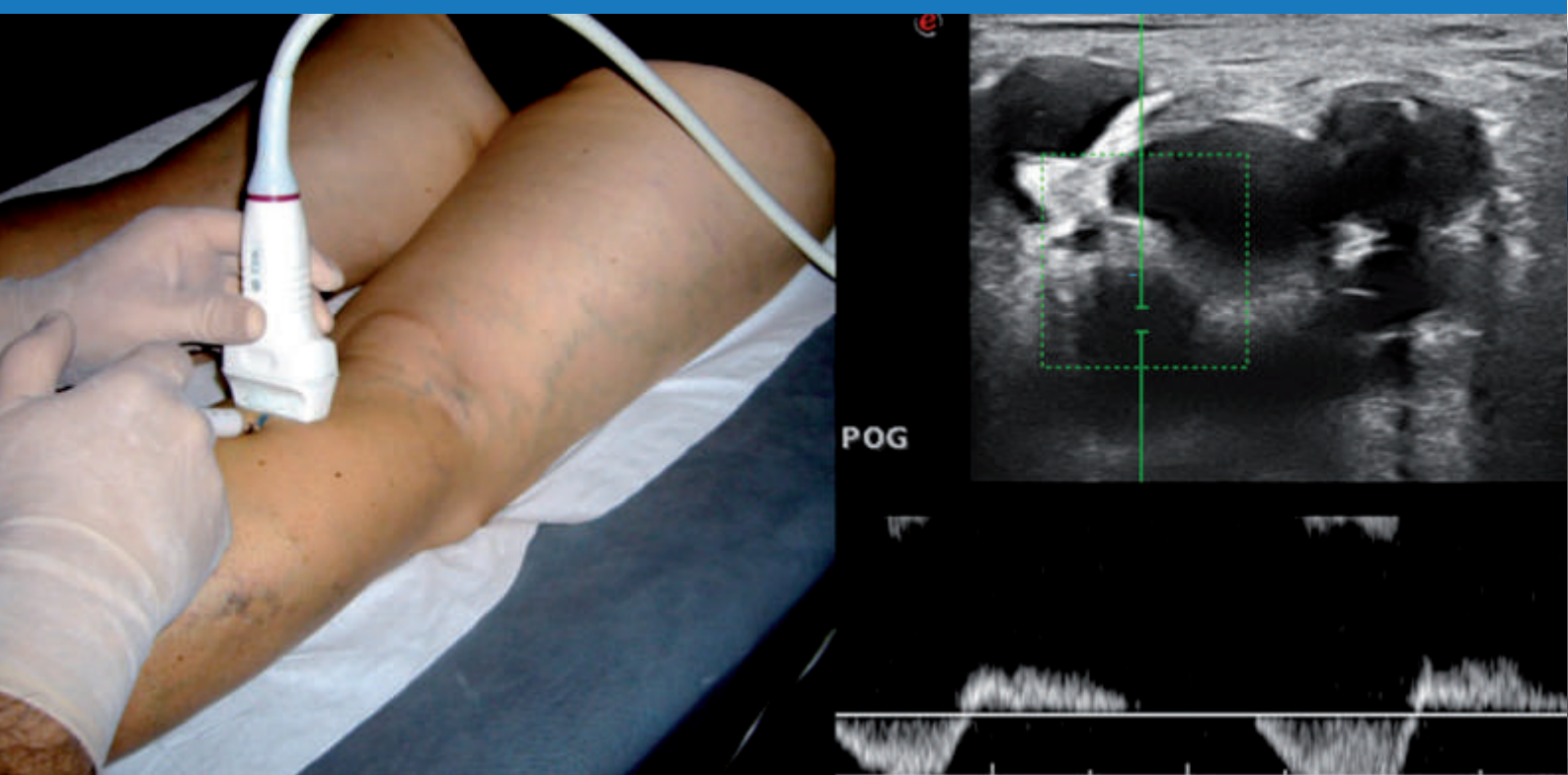


Ultrasound and Phlebology

Under the direction of
Jean-Jérôme Guex and Claudine Hamel-Desnos



Under the aegis of the French Society of Phlebology

SOCIÉTÉ FRANÇAISE DE
PHLEB  LOGIE

Éditions Phlébologiques Françaises - Paris

Chapitre 12

The Echo-Doppler Procedure: Endovenous Thermal Ablation

Nicolas Néaume

Summary

Duplex ultrasound is the central, indispensable and mandatory element at all stages of the endovenous thermal ablation. It is therefore necessary for the operator to have good skills in Duplex venous examinations and knowledge of venous anatomy and pathology.

Meeting these requirements, the practitioner can then optimise the treatment and perform a thermal ablation safely, according to the data of the High Authority of Health. (*Evaluation of Professional Acts Service / April 2008 - 131*) [13, 14].

Introduction

Endothermal venous procedures (using lasers or radiofrequencies) for the treatment of varices are safe and efficacious techniques developed for the past 15 years in most countries in the world. It is important that they are performed in the out-patient environment, under tumescent peri-venous anaesthesia, and constantly guided by ultrasound. The operator must demonstrate his skills in interventional ultrasound techniques and have a good knowledge of venous anatomy and pathology.

Ultrasounds allow real time monitoring of the intervention and to optimise the procedure on the basis of the anatomical characteristics of the varicose segment to be treated.

Since ultrasounds are the central, indispensable and compulsory factor in endothermic venous interventions, it is important to begin this chapter with a few reminders of ultrasound anatomy.

Ultrasound Anatomy of the Blood Vessels [1, 2, 3, 6, 15]

Ultrasound semiology

Liquids that do not contain particles in suspension can be penetrated by ultrasound and are known as anechogenic or trans-sonic.

Interfaces with a high reflection factor (soft tissue/air, soft tissue/bone) mostly reflect ultrasound and display as a hyperechogenic contour generating a cone of shade.

Soft tissues are more or less echogenic: fascias are shown in the form of lines that may be more or less hyperechogenic and muscles are generally hypo-echogenic.

Nerves are hypoechogenic, surrounded by a clearly visible edge, these edges presenting with a more heterogeneous "beehive" or "follicular" aspect.

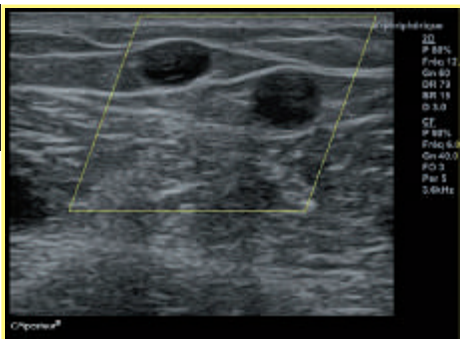
Duplex ultrasound (DUS) topographical anatomy of blood vessels and nerves

The venous anatomy is complex and extremely variable. A good knowledge of anatomy allows to avoid numerous pitfalls, obstacles and complications during thermal ablation. Prior to the intervention, venous-mapping helps performing the endovenous procedure in optimal fashion, by identifying any possible interventional difficulties in advance.

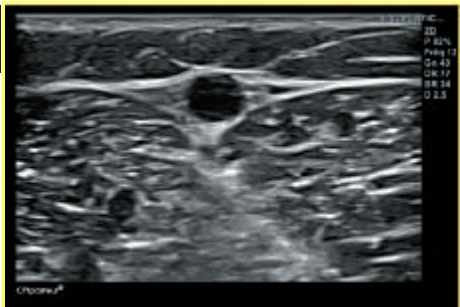
Three venous compartments can be identified, limited respectively by the deepest layer of the skin, the superficial fascia, and the muscular (or aponeurosis) fascia.

The uppermost compartment, situated between the dermis and the superficial fascia, contains veins that are tributaries of the saphenous veins and the network of reticular veins.

DUS image of the inter-fascial great saphenous vein and a supra-fascial tributary.



DUS view of "the Egyptian eye".



The saphenous compartment (inter-fascial, between the two layers of the fascia), situated beneath the superficial fascia and containing the saphenous trunks (great saphenous vein and small saphenous vein), the anterior accessory in the thigh of the great saphenous vein, the Giacomini vein and their satellite nerves.

It is identified in ultrasound as "the Egyptian eye"

The deep vein compartment, situated at depth beneath the muscular fascia.

Perforating veins connect veins of this this compartment to those of the other two through the aponeuroses.

Superficial venous anatomy:

Definitions

The great saphenous vein and the small saphenous vein present with accessories and tributaries and can also be duplicated.

By convention:

- a true saphenous vein duplication runs parallel to the saphenous vein in the saphenous compartment;
- an accessory saphenous vein run more superficially than the saphenous vein, possibly as a doubling of the superficial fascia;
- a tributary runs very superficially within the sub-cutaneous cell tissue outside any fascia.

The great saphenous vein (GSV)

The GSV originates at the internal marginal vein of the foot within the sub-cutaneous cell tissue in front of the internal malleolus.

It then rises vertically at the back of the internal edge of the tibia, accompanied at this level by the leg branch of the internal saphenous nerve which accounts for certain sensory disorders as possible aftereffects of thermal ablation.

At garter level (upper third of the leg) it receives two tributaries from the front and rear of the leg.

It then passes behind the internal condyle of the femur which it surrounds and rises to the thigh, parallel to the medial side of the sartorius muscle, where it is accompanied by sensory nerves: the anterior branch of the internal cutaneous and the accessory of the internal saphenous. Along the way, it receives the sub-cutaneous veins of the thigh that can join in an accessory saphenous vein that discharges at the tip of Scarpa triangle on the anterior surface of which it rises vertically up to the junction (saphenous arch). The saphenous arch perforates the fascia cribriformis and drains into the femoral vein 4 cm below the femoral arch. This is an anatomical constant. Before perforating the aponeurosis it receives the satellite veins of the superficial arteries. Its most immediate connection is lymphatic. Between 4 and 20 inguinal lymph nodes are grouped together in a triangular mass inside the Scarpa triangle.

Of the superficial nerves in the region, only the medial musculo-cutaneous nerve, a branch of the crural nerve, itself contains a branch that accompanies the vein.

Tributaries of the great saphenous vein

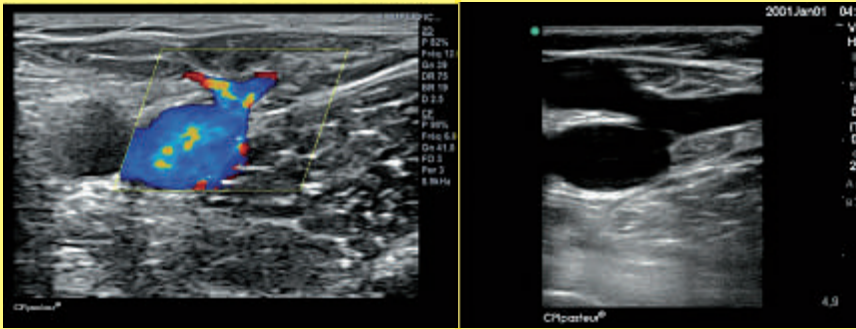
The great saphenous vein receives numerous tributaries that need to be described since knowledge of their anatomy is important in varicose pathology.

The anterior saphenous tributary in the leg drains the pre-tibial sector. It starts from the back of the foot, rises along the tibia and drains into the great saphenous vein at garter level, having traversed the relief of tibial crest at the union of the upper third and the median third.

The rear saphenous tributary in the leg starts at the tip of the medial malleolus and rises to discharge just below the knee into the great saphenous vein after sending an anastomosis to the small saphenous vein.

The anterolateral vein is a long, sub-cutaneous venous trunk that starts at the lower lateral part of the leg and rises on the outer side of the knee to join the great saphenous vein in the upper part of the thigh.

The Echo-Doppler Procedure: Endovenous Thermal Ablation.



The sapheno-femoral junction (great saphenous vein, superficial epigastric vein, common femoral vein).

| The sapheno-femoral junction (SFJ)

The SFJ receives three upper tributaries:

Branches of the abdominal wall with a descending route:

- The superficial circumflex iliac vein.
- The sub-cutaneous abdominal (or superficial epigastric) vein.
- The external pudendal vein with a transversal path.

The way in which these tributaries end is very variable; they may either join the saphenous arch in an isolated and dispersed fashion or they may be grouped together to form a common trunk that drains into the great saphenous vein or the anterior accessory saphenous vein in the thigh

The saphenous arch sometimes receives lower tributaries or accessory saphenous veins, and it may drain at a slightly lower point in the saphenous vein than that of the preceding veins:

- Posterior accessory saphenous vein.
- Anterior accessory saphenous vein.

| The Small Saphenous Vein (SSV)

The SSV drains blood from the external part of the foot and the posterior lateral part of the leg.

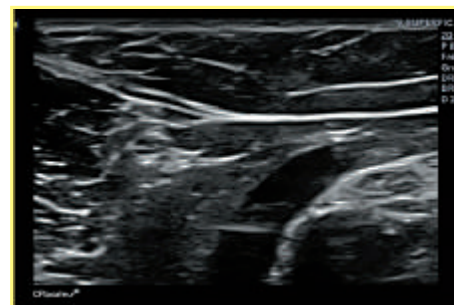It is a continuation of the external marginal vein that runs along the dorsal side of the foot. At its origin, the main trunk passes below, then behind the lateral malleolus in the external retro-malleolar groove.

It then rises vertically and in a median supra-aponeurotic position along the rear of the calf, and is then attached to the sural (sensory) nerve that must not be damaged during thermal ablation.

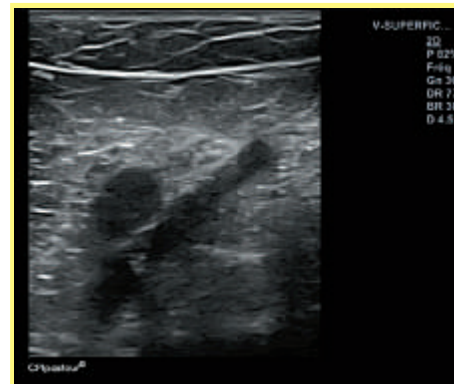At mid-leg it enters the sub-aponeurotic tunnel of the sural triceps. It then bends slightly, which makes it deeper and the vein continues along its path to the top of the up to the knee joint line level. This is where it bends and forms an anterior concave arch to join the popliteal vein at a level that can vary, or it may even be attached to a subordinate popliteal trunk in the great saphenous vein

or the tributaries thereof, in the deep femoral vein or it may even form a joint trunk with the gastrocnemius veins. In the upper part of the calf, the arch of the small saphenous vein generally runs between the tibial nerve and the median gastrocnemial muscle, in which case you should remain below this area (by about 15 to 20 mm in general), so as to avoid damaging the nerve during endovenous thermal ablations.

In 15 to 20% of cases, the sapheno-popliteal junction is non-existent. The external saphenous trunk extends to the rear side of the thigh. It then bends inwards to join the internal saphenous trunk or it may run down towards the deep femoral vein.

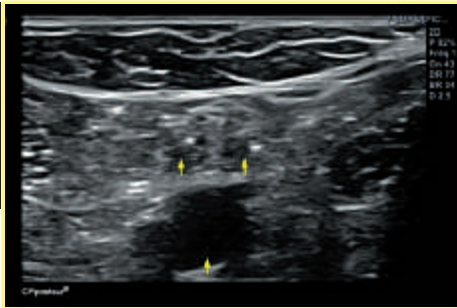


Small saphenous vein: inflexion and front concave cross-piece to where it joins the sapheno-popliteal junction.



Common trunk of small saphenous and gastrocnemius veins.

DUS picture showing the proximity of the nerve structures (N), the Small Saphenous arch (SSV), and the popliteal vein (PV).



Anastomoses between the two saphenous systems

In the leg: three oblique anastomosing branches can be found on the medial side and four transversal anastomosing branches on the lateral side.

In the thigh:

- The **Giacomini vein** (the cranial extension of the small saphenous vein) which separates from the SSV arch rises at the rear, sub-aponeurotic side of the thigh, turns around the medial aspect of the thigh and ends into the great saphenous vein at a variable level.
- The cranial extension of the small saphenous vein also emerges at the cross-piece of the small saphenous vein and rises vertically along the whole rear area of the thigh, reducing in calibre and dividing into numerous branches at the gluteal fold.

Echographic imaging of the thermal ablation material and the vein by procedure [4, 15]

Interventional ultrasound is swift, mobile and non-radiational, it displays a 2D image and thus ensures that the operator is working under satisfactory safety conditions.

It has major advantages thanks to the permanent visualisation in real time of the material needed for thermal ablation.

Thermal ablation interventions are performed according to very specific protocols, that can generally be superimposed for laser treatment, for the radio frequency and with certain specific requirements for Steam Vein Sclerosis treatment.

For Steam Vein Sclerosis (water vapour treatment), a simple echo-guided puncture is performed using an infusion catheter, the treatment catheter (16 G) being installed without a guide. Its metal tip is very echogenic, and thus easy to locate. [5]

All of these endoluminal procedures require the use of a colour ultrasound -doppler with a probe of at least 10 MHz. As with any equipment used in an operating theatre, it needs to be protected by a sterile cover (over the probe and keypad).

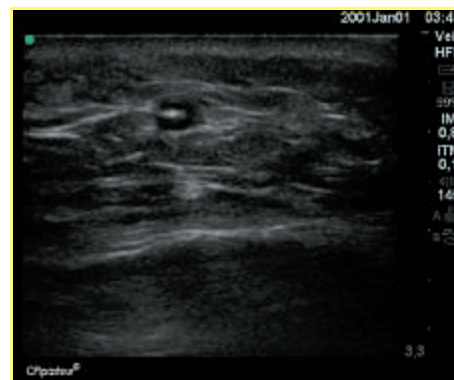Puncturing the vein

The first stage involves puncturing the varicose vein to be treated, using a catheter-needle; this can be done in transversal or longitudinal mode, depending on the operator's preference.

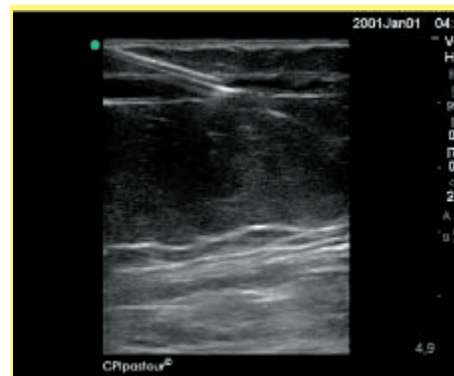The main factors to ensure visibility of the needle during ultrasound are:

- the angle it forms with the direction of the ultrasound beam
- its calibre
- the accurate positioning of needle and probe with reference to the plane.

Therefore, in transversal mode, where the plane of the cross-section is perpendicular to the needle (outside the plane), the tip of the needle can be seen as a point, more or less "hyperechogenous ultrasound tip", creating a cone of shade.



Transverse puncture.



Longitudinal puncture (reverberation artefact of the catheter needle).

The Echo-Doppler Procedure: Endovenous Thermal Ablation.

In longitudinal mode, the plane of the cross-section is parallel to the introduction of the needle (insertion within the plane) enabling visualisation of the whole needle. The closer the angle formed by the needle and the ultrasound beam is to 90°, the greater the visibility of the needle and the more apparent the reverberation artefacts generated by the body of the needle itself. The needle has a hyperechogenic appearance and is easily monitored, thus ensuring visibility of the structures through which it passes.

The ideal position is to place the DUS probe in such a way that it is possible to view the needle throughout its course and/or its tip.

A wide variety of needles is available, varying only in size. During thermal ablation a 18 G X2 ¾ catheter needle is generally used for percutaneous puncture while for a WIRE 0.038 " guide an introducer-dilator of 5F/6F/7F is used. Secondary complications due to puncture are minor, including vaso-vagal reactions, haematoma, and possibly infection at the puncture site.

Guide wire

Once the puncture needle is in position, the blood reflux, in addition to DUS imaging, allows to verify it is correctly positioned into the vein. A guide wire (of 45 cm on average) is then introduced through the catheter needle to catheterise the vein.

In transversal mode, DUS imaging will show a hyperechogenic element close to the centre of the vein; or a hyperechogenic strip of reverberation artefacts (parallel to the walls of the vein in longitudinal mode).

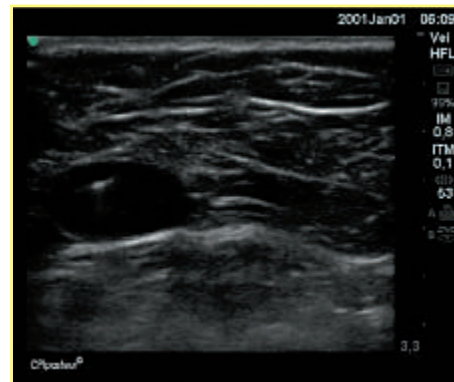Introducer-dilator

Once the guide wire has been inserted, and identified through ultrasound, the introducer-dilator is placed in position using a guide. The guide and the dilator are then removed, being replaced by the introducer in the venous light. DUS shows the introducer as a typical image of hyperechogenous double echo due to its two walls (a cylindrical, hollow object), (visible on either of the two modes, transversal or longitudinal).

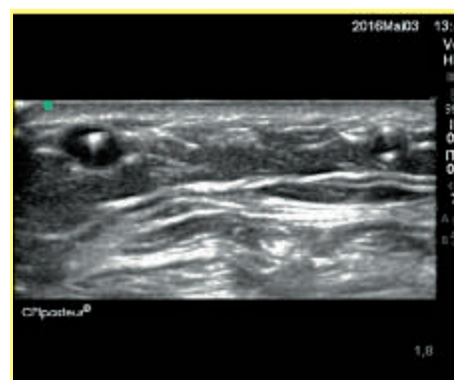
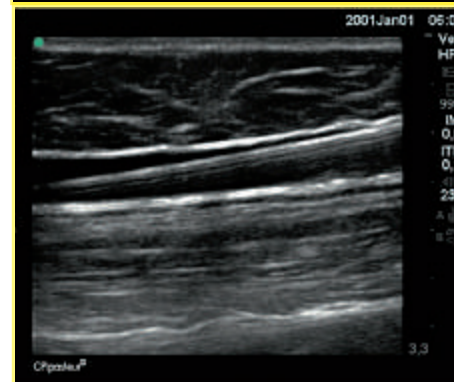
Installing the probe

Once the introducer has been installed, the thermal ablation probe can be introduced up to the sapheno-femoral or sapheno-popliteal junction.

If catheterisation difficulties are encountered, ultrasound makes it possible to identify potential obstacles that could interfere with the procedure. These obstacles may be represented by meanders, ectasia and doublings, localised thrombotic sequels and valvules. Meanders of the trunk are rarely marked and are mostly cases that



Guide wire in transversal and longitudinal mode (reverberation artefacts).



View in transversal mode of a doubling of the saphenous trunk with the guide wire on the left and the introducer on the right (a double hyperechogenous echogram moulding the anterior and posterior of the saphenous vein).

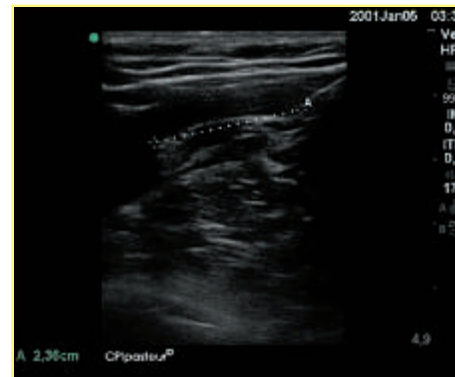
can be overcome by manual manoeuvring or through use of the ultrasound probe. In the opposite case, the procedure may be resumed through using a different approach, this time just above the obstacle. [6]

The upward move under echographic guidance can also travel along the wrong route, either in a saphenous doubling or in an anterior subordinate saphenous vein, in a perineal vein or through perforation into the deep system.

Sapheno-femoral junction

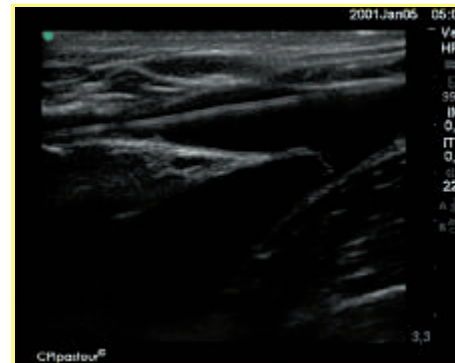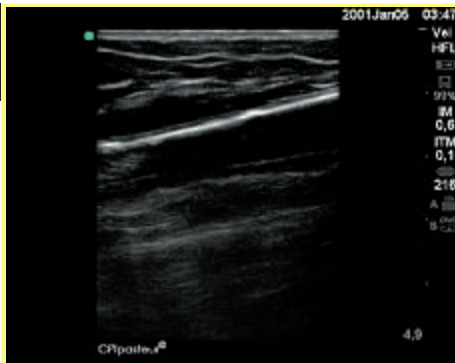
The probe is positioned between 1.5 and 2 cm from the junction, so that for most of the time it is slightly behind the superficial epigastric vein. Ultrasound allow identifying the anatomy and the safe distance measurement. Cross-section and lengthwise section views make it possible to ensure the correct placing of the tip of the probe.

In certain cases it may be difficult to identify the tip, but a simple method consists in pulling and pushing the probe making it disappear and then reappear [AKA the "elevator technique"], like an elevator that rises and descends, and this will enable it to be placed accurately.



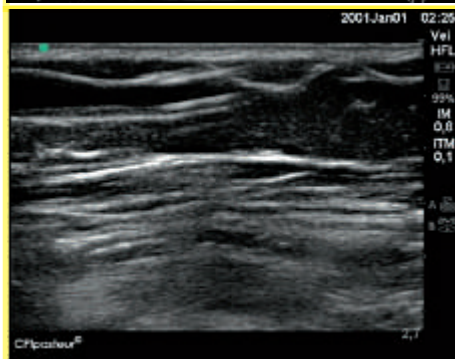
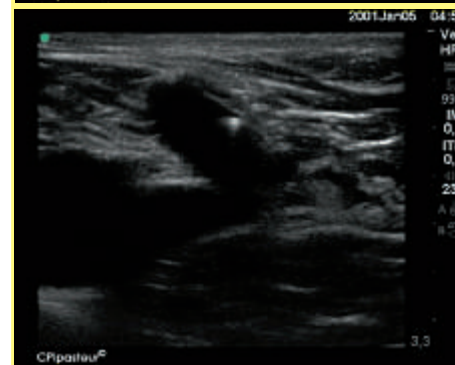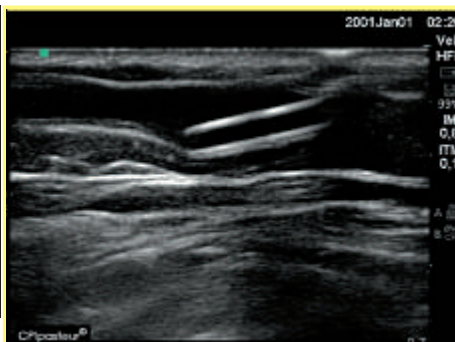
Radiofrequency probe about 2 cm from the sapheno-femoral junction.

Longitudinal section of a thermal ablation probe.



Laser fibre tip in a wrong position: in the superficial epigastric vein (longitudinal/transversal).

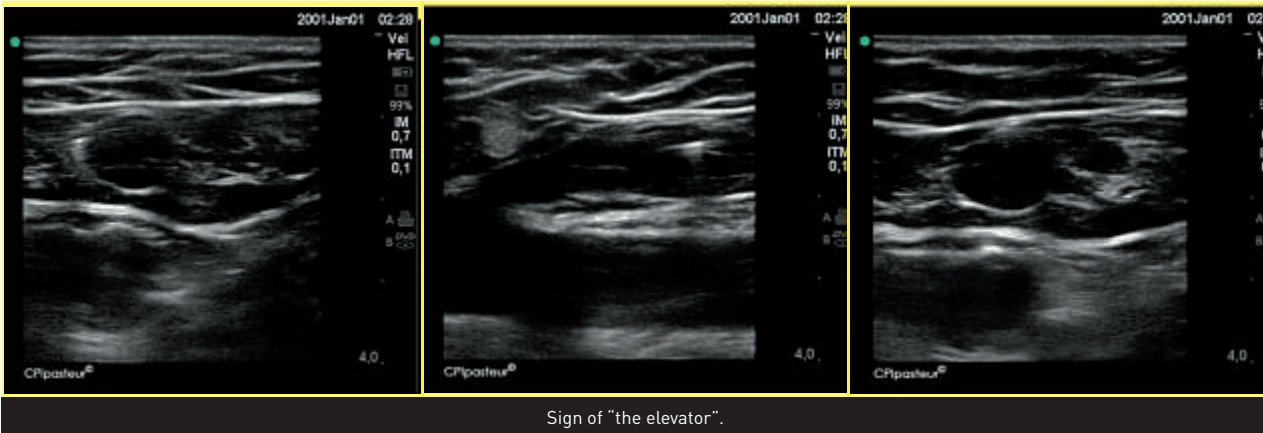
Manual manoeuvre guided by ultrasound allowing to overcome a meander in the saphenous trunk by adjusting the channel of the introducer to match that of the vein.



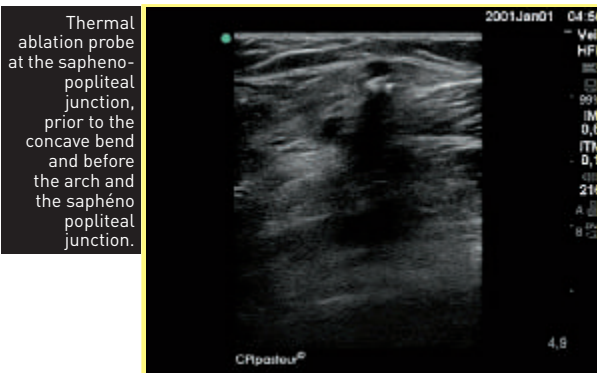Sapheno-popliteal junction

With respect to the sapheno-popliteal junction, one of the problems that arises most frequently is the presence of a nerve that is often attached to the vein when the arch is high and eccentric [9]. Identifying it through DUS allows to inject the tumescence to separate the vein from nerve structures (the "beehive" ultrasound representation) in order to protect them.

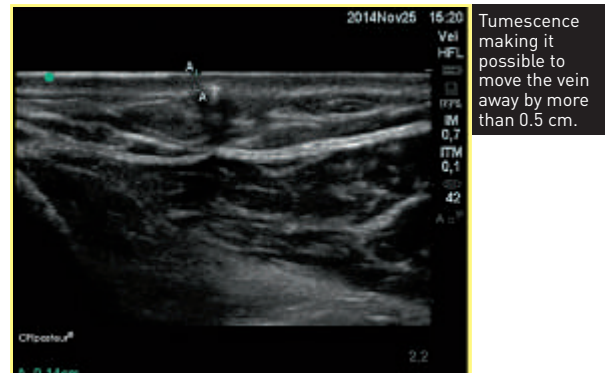
The Echo-Doppler Procedure: Endovenous Thermal Ablation.



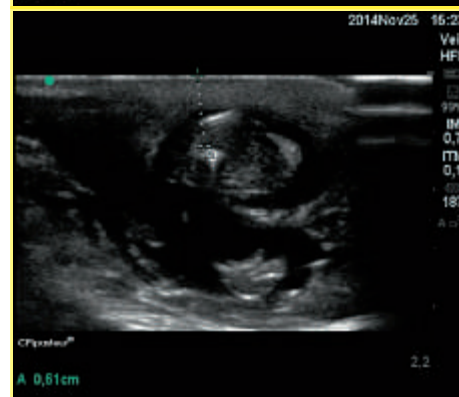Sign of "the elevator".



Thermal ablation probe at the sapheno-popliteal junction, prior to the concave bend and before the arch and the sapheno-popliteal junction.



Tumescence making it possible to move the vein away by more than 0.5 cm.



Here again, the probe is positioned between 1.5 to 2 cm from the sapheno-popliteal junction where it exists. The ultrasound measurement will check that the probe is in the right position.

In the absence of a sapheno-popliteal junction (in about 15 to 20% of cases) the fibre is generally positioned in the upper part of the reflux if catheterisation is possible (for example, 1.5 to 2 cm from the point at which the Giacomini vein links up to the great saphenous vein).

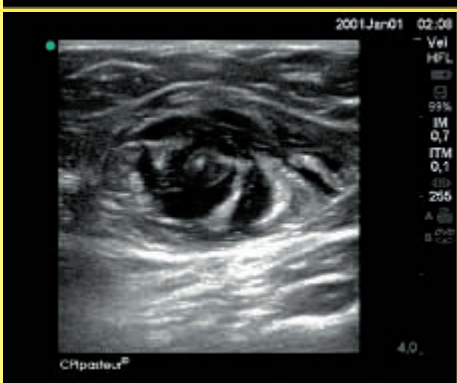
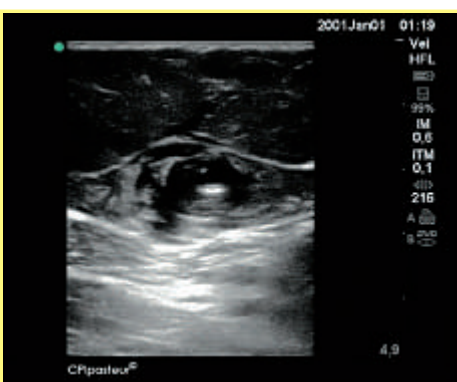
When the small saphenous vein shares a trunk with the gastrocnemius veins, the fibre should be positioned below them in order to keep them intact.

Tumescence

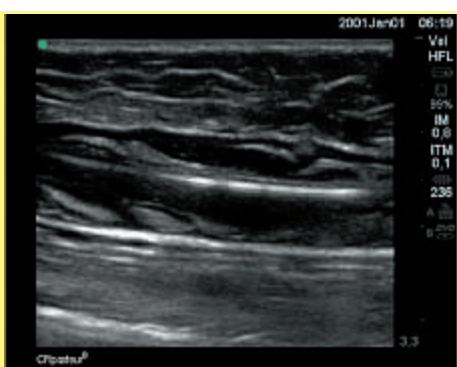
Anaesthesia by tumescence makes it possible to compress the vein and thus physically reduce its diameter. The pressure exercised on the vein causes a spasm that also contributes to the shrinking of the venous lumen, expelling blood from the vein and enabling the probe to come into contact with the endothelium. [7]

Where the vein is very superficial, i.e. less than 0.5 cm from the skin when measured through ultrasound, the vein can then be pushed down by using the tumescence and protecting the surrounding tissues while minimising the risks of burning. [8] The same applies to nerve

Tumescence and hypoechogenic halo in transverse mode.



Tumescence in longitudinal mode.



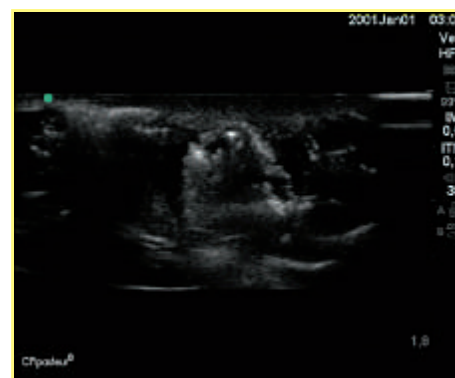structures that can easily be distanced from the vein thanks to the tumescence.

DUS allows to identify the vein, step by step, and create tumescence with longitudinal or cross sectional imagin according to the operator's preference. The ultrasound appearance of the tumescence is that of a hypoechogenic halo surrounding the venous structure, due to the introduction of the volume of fluid inside the saphenous space that creates a sheath of fluid around the vein. Efficacious tumescence causes a spasm of the vein and

leaves only the hyperechogenic probe visible in the centre of the hypoechogenic halo.

The injection of tumescence under ultrasound also allows to avoid damaging the catheter or probe with the bevel of the needle. Similarly, echographic guidance takes on special importance such as in the areas of the sapheno-femoral or sapheno-popliteal junctions, where artery and nerve structures are close by.

Note that insufficient draining of air off the infusion pump tubing will cause very annoying hyperechogenic artefacts, concealing the vascular structures. Consequently it is important to start the tumescence distally so as not to compromise the correct placement of the probe at the sapheno-femoral or sapheno-popliteal junction, as a result of lack of ultrasound visibility.



Hyperechogenic artefacts concealing the vascular structures (failure to blow off the air from the tubing before the start of tumescence... the very hyperechogenic thermal probe can still be seen in the upper part).

Powering up the thermal ablation generator

Another ultrasound check of the position of the fibre or the probe is performed before starting thermal ablation.

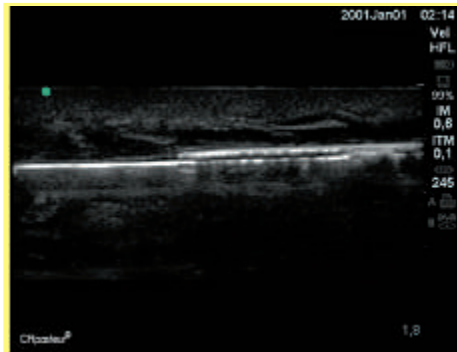
As per procedure, the ultrasound image of the ablation is one of "thermal vaporisation", with mobile hyperechogenic around the tip of the "steam bubble" probe. [10]

The immediate ultrasound image of the vein treated looks like a "rosette or bagel" [11] that is hyperechogenic around the edge with a hypoechogenic point in the centre that may vary in size. A thickening can then be observed as well as a denaturation of the intima-media of the vein wall [12].

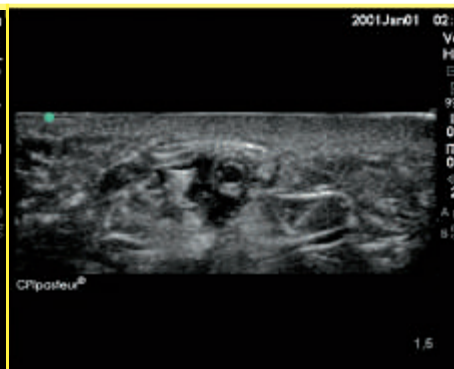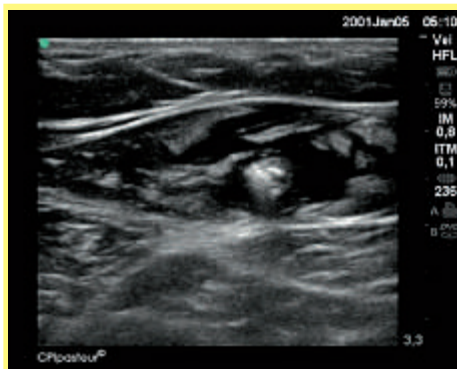
A final check at the end of the treatment verifies that the procedure (occlusion of the saphenous vein) has been successful and in particular that there is no deep vein thrombosis.

The persistence of a hole in the lumen during the immediate check is not significant since the occlusion will occur spontaneously in the following few days. This hole is seen more often in radiofrequency than in laser treatment.

The Echo-Doppler Procedure: Endovenous Thermal Ablation.



Thermal vaporisation.



Instantaneous ultrasound repositioning (endovenous post-laser on the left, post radiofrequency on the right, the hypoechogenic central part is larger in radiofrequency).

Conclusion

Ultrasound is thus the indispensable and essential element in thermal endovenous ablation for intervention at all stages of the procedure. Its use allows to ensure the safety of the procedure as well as the optimisation of the treatment by enabling better progression of catheterisation and tumescence that is adequate for better contact between the thermal device and the wall of the vein.

As recommended by the French Haute Autorité de Santé (Service evaluation des actes professionnels / April 2008 - 131 -), a healthcare professional who wishes to perform the procedure must prove: [13,14].

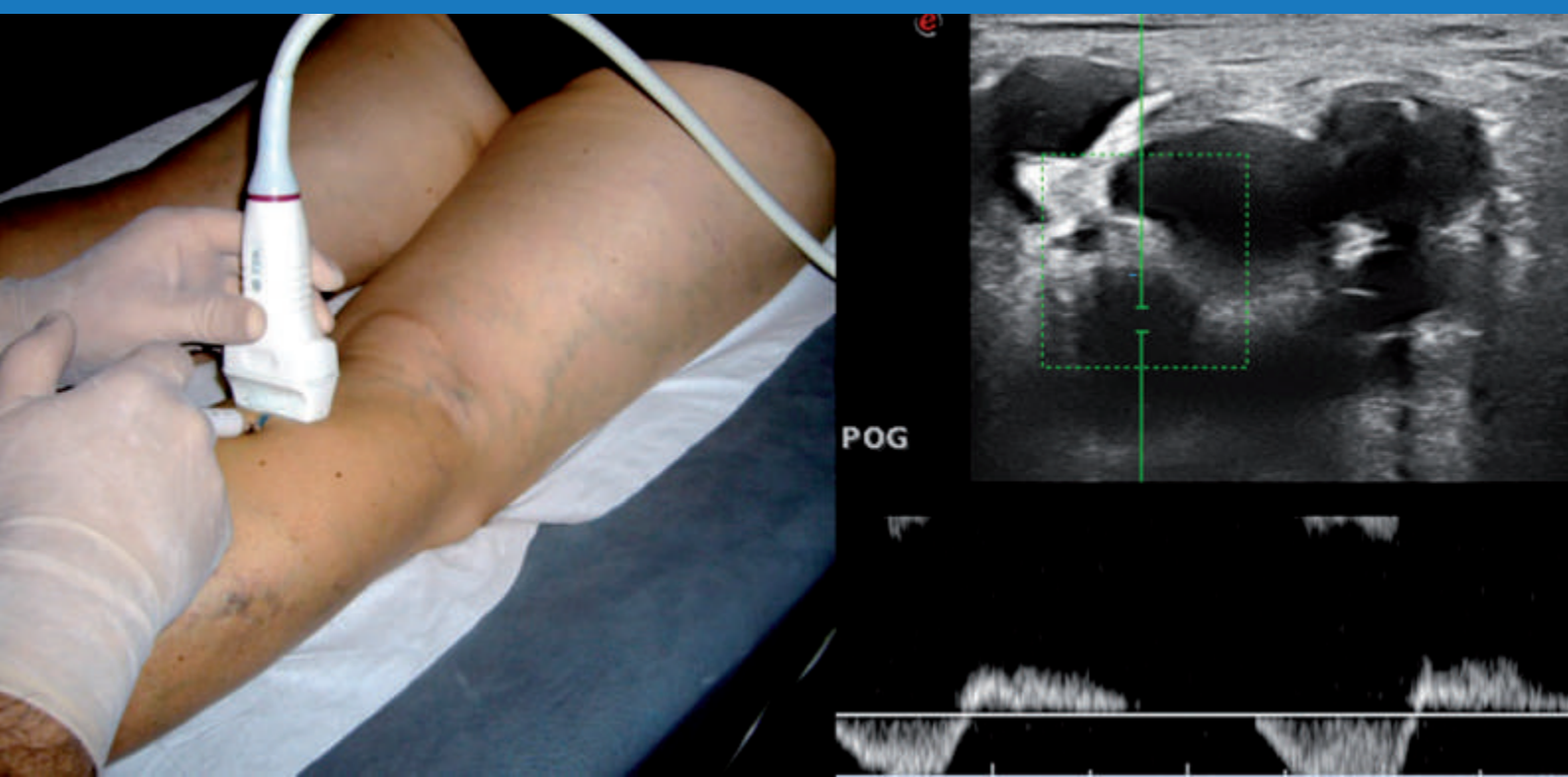
- Clinical skills in the treatment of vascular afflictions of the lower limbs;
- Theoretical knowledge and sufficient practical experience of using echo-doppler in the leg veins;
- Practical experience of procedures involving ultrasound-guided vein punctures;
- Practical experience of endovascular procedures (catheterisation of the veins).

Bibliography

- [1] Kchouk H. Echographie-Doppler veineux. Du cerveau aux membres inférieurs – Collection d'imagerie radiologique - Masson.
- [2] Davy A. L'anatomie normale des veines des membres inférieurs – annales vasculaires - Phlebologie 2012, 65,1, p. 37-46.
- [3] Quere I., et al: Polycopie de phlebologie – CEMV –Prise en charge des varices.
- [4] Bonnin A., et al: Échographie – Imagerie médicale formation – Masson.
- [5] Milleret R., et al: Obliteration veineuse par vapeur d'eau à haute température. Phlebologie 2008;2.
- [6] Allouche L., Néaume N. Cartographie en laser endoveineux. Phlebologie 2013, 66, 2, p.40-44.
- [7] Desnos P. Mode d'action des lasers endoveineux et impact des différentes longueurs d'onde. Phlébologie 2013, 66, 2, p. 28-33.
- [8] Ibid. Avis occlusion de veine saphène par laser par voie veineuse transcutanée. HAS 2008.
- [9] Uth J.F., Gillot C. Anatomy and embryology of the small saphenous vein: nerve relationships and implications for treatment. Phlebology 2012.
- [10] Pannier F, Rabe E. How to perform endovenous laser ablation of great saphenous veins. Phlébologie 2013, 66, 2, p. 45-49.
- [11] Gerard J.L. What is new in laser treatment of the saphenous and perforating veins? Chap 9: 349-354 . Mayo Clinic - International Vascular Symposium 2011 Advances and Controversies in Vascular Medicine, Vascular Surgery and Endovascular Interventions. Ed. Głowiczki P., Shields R.C., Bjarnason H., Becquemin J.-P., Głowiczki M.L.
- [12] Perrin M. Traitement des varices par la radiofréquence. STV 2008; n° 4: 166-82.
- [13] Occlusion de veine saphène par laser-Rapport d'évaluation technologique – Avril 2008.
- [14] Occlusion de grande veine saphène par radiofréquence par voie veineuse transcutanée-Rapport d'évaluation technologique – Avril 2008.
- [15] Eysenberg E., et al: Echographie en anesthésie régionale périphérique – Arnette -2007.

Ultrasons et Phlébologie

Sous la direction de
Jean-Jérôme Guex et Claudine Hamel-Desnos



Sous l'égide de la **Société Française de Phlébologie**

SOCIÉTÉ FRANÇAISE DE
PHLEB  **LOGIE**

Prix de vente :
50 euros + frais d'expédition
Commander à :
courrier@sf-phlebologie.org

Éditions Phlébologiques Françaises - Paris