

The “COPIOUS” study: “COnservative thigh Perforating surgery by selective ablation of Incompetent saphenOUS vein”.

L'étude « Copius » : Chirurgie conservatrice de perforante de cuisse par ablation sélective de la veine saphène incontinente.

Risse J., MD¹, Creton O., MD², Creton D. MD³

Abstract

Introduction:

The involvement of perforating veins of the thigh (PC) in varicose disease and its recurrence is controversial.

Precise haemodynamic exploration is essential before therapeutic decision.

Our hypothesis is that in the presence of an incontinent PC associated with an incompetent and proximal competent distal saphenous trunk, the selective ablation of the great saphenous vein (GVS), under the perforator, restores hemodynamics with an orthograde flow in the Competent GSV and preservation of a PC flow to the deep venous system.

Method:

This is a multi-center, interventional, cross-sectional, nonrandomized clinical trial including consecutive patients with symptomatology of venous insufficiency, refluxing PC, underlying incontinent and proximal continent GVS.

Thermal surgical treatment (laser or radiofrequency) or ligation of the GVS under the perforator was performed.



Résumé

Introduction :

L'implication des veines perforantes de cuisse (PC) dans la maladie variqueuse et ses récurrences est controversée.

L'exploration hémodynamique précise est indispensable avant décision thérapeutique.

Notre hypothèse est qu'en présence d'une PC incontinent associée à un tronc saphénien distal incompétent et proximal compétent, l'ablation sélective de la grande veine saphène (GVS) refluyente, sous la perforante, rétablit l'hémodynamique avec flux orthograde dans la GSV compétente et préservation d'un flux de PC vers le système veineux profond.

Méthode :

Il s'agit d'une étude clinique multicentrique, interventionnelle, transversale, non randomisée incluant des patients consécutifs avec symptomatologie d'insuffisance veineuse, PC refluyente, GVS sous-jacente incontinente et proximale continente.

Un traitement chirurgical thermique (laser ou radiofréquence) ou ligature de la GVS sous la perforante a été réalisé.



1. CHRU de Nancy, Service de Médecine Vasculaire et Centre de Compétence Régional des Maladies Vasculaires Rares et Systémiques Auto-immunes, Nancy, France.

2. Département de chirurgie vasculaire, Clinique Charcot, Sainte-Foy-lès-Lyon, France.

Correspondance:

Dr Jessie RISSE. Service de Médecine Vasculaire et Centre de Compétence Régional des Maladies Vasculaires Rares et Systémiques Auto-immunes. Institut Lorrain du Cœur et des Vaisseaux Louis Mathieu – CHRU de Nancy. Rue du Morvan – 54511 Vandœuvre-lès-Nancy Cedex.

Phone: +33 3 83 15 74 44 – Fax : +33 3 83 15 70 38.

Email: j.risse@chru-nancy.fr

◆◆◆ Results:

Fifty-eight legs were included.

Early control found 92.5% of proximal PCs and GVS permeate with orthograde flow in the GVS and 82.4% in the long term.

CEAP VCSS scores and PC and GVS diameter decreased.

Absence of residual varix in 96.2% of cases. Two patients had long-term variceal recurrence.

◆◆◆ Conclusion:

Selective surgery of incontinent distal GVS under PC with continental proximal GVS preservation is possible and restores hemodynamic balance.

The recidivism rate was low in the long term, not significant, requiring completion of the study on a larger scale.

◆◆◆ Keywords: varicose veins, perforating veins, surgery.

◆◆◆ Résultats :

Cinquante-huit jambes ont été inclus.

Le contrôle précoce trouve 92,5 % de PC et GVS proximales perméables avec flux orthograde dans la GVS et 82,4 % à long terme.

Les scores CEAP VCSS et le diamètre des PC et GVS ont diminué.

Absence de varice résiduelle dans 96.2 % des cas. Deux patients ont présenté une récurrence variqueuse à long terme.

◆◆◆ Conclusion :

Une chirurgie sélective de GVS distale incontinente sous une PC avec préservation de GVS proximale continente est possible et rétabli un équilibre hémodynamique.

Le taux de récurrence était faible à long terme, non significatif, nécessitant de compléter l'étude à plus grande échelle.

◆◆◆ Mots-clés : varices, veines perforantes, chirurgie.

Introduction

Hemodynamic of the perforating veins

The hemodynamic significance of the perforating veins continues to be a point of controversy [1-4].

A thorough understanding of superficial venous anatomy and anatomical variations is essential to perform an accurate examination and guiding future treatment [5-6].

In chronic venous insufficiency (CVI), incompetent perforating veins (IPVs) are more often located in the middle third of the calf, followed by the lower calf and middle thigh [7].

The pathophysiologic mechanisms that lead to the development of PV reflux are not the same at the thigh or the leg. It is important to know and understand this hemodynamic in order to target the area to be treated and avoid recurrences.

Recent reports have proposed that reflux in the leg PVs is due to volume overload at re-entry points of incompetent superficial veins. In the thigh, it seems like PV incompetence is associated with reflux in the superficial veins connected to them [8-10].

This points out the important role of superficial vein reflux in the development of PV incompetence.

IPVs and recurrence of varicose vein

Incompetent perforating veins have been implicated in the aetiology of recurrent varicose veins by several different authors [11]. In a recent study [12], reflux in thigh perforating veins was responsible for recurrence of varicose veins after surgery (REVAS) in 12.5% of failures.

The presence of thigh perforating veins was comparable to great saphenous vein (GSV) recanalization as a cause of REVAS in both Rasmussen's [13] and Rass's [14] studies and most likely was a causative factor in GSV recanalization [15].

This finding underlines the progressive nature of REVAS, despite concomitant treatment of the varicose branch veins as well as incompetent perforating veins in several series at the time of endovenous ablation.

Treatment of IPVs

The necessity for surgical correction of IPV is still debated [3, 16] with several studies showing no symptomatic benefit in C2 patients [13, 17] or improved ulcer healing in C5 or C6 patients [18-21].

There is some evidence that for primary varicose veins, GSV treatment restores competence in up to 80% of incompetent perforating veins [22].

This would still leave 20% of incompetent perforators which would continue to reflux and may lead to recurrence.

The "COPIOUS" study: "Conservative thigh Perforating surgery by selective ablation of Incompetent saphenOUS vein".

IPV surgery is not as successful as its proponents claim, with missed veins and less than optimal durability [4].

Although IPV surgery can be done with some success via less invasive techniques [20, 21, 23], the question remains as to whether it has any value in decreasing the risk of recurrent varicosities (except venous ulcer).

Because most limbs in the early stages of CVI exhibit reflux in the superficial veins only, it can be assumed that one of the mechanisms for development of IPV involves the presence of reflux in the superficial vein segment to which this PV connects.

But the entire GSV is not always incompetent.

If the proximal part of the GSV and the sapheno-femoral junction are competent it is not justified to occlude them.

Our hypothesis is that a thigh IPV associated with a distal incompetent GSV accompanied by a proximal competent trunk can be corrected by selective GSV ablation.

Selective ablation of the distal GSV under the perforator vein would restore hemodynamic.

The flow in the perforating vein should then be made upwards in the competent proximal GSV and we can conserve the flow of PV to the deep venous system.

The present study aimed to evaluate the feasibility of conservative treatment of thigh IPV by selective occlusion of the distal incompetent saphenous vein.

The secondary objectives are to evaluate the competence of the thigh perforator vein and the conserved GSV after treatment, evaluate clinical improvement, identify recurrent varices, describe complications.

Methods

Study design and patient selection

COPIOUS was a multicentre, interventional, cross-sectional, non-randomized clinical study over 10-year involving consecutive patients with a thigh IPV associated to a limited underlying GSV reflux (**Figure 1**).

Patients over 18 who met these criteria and consulting in one of the 2 participating centres were enrolled. Patients with obstructive syndrome or deep venous incompetence, CEAP ≤ 2 or pregnant women were excluded.

Preoperative assessments

Patients were referred to the surgeon by the angiologist.

During the consultation, the investigating physician carried out the usual assessment including the complete clinical examination with pictures, the standardized collection of data and a second full venous duplex ultrasound (DUS).

The CEAP classification was used as the common descriptive platform for reporting patient status in chronic venous disease [24] and the Venous Clinical Severity Score (VCSS).

According to the guidelines from the American College of Phlebology and Intersocietal Accreditation Commission for a complete examination of the superficial venous system [25], DUS was performed with a high-frequency linear transducer (7.5-15 MHz).

Standing and reverse Trendelenburg positions was used to improve the ability to detect reflux and increase the caliber of refluxing veins compared with supine positioning.

Color Doppler was used to rapidly determine the direction of blood flow.

Spectral (pulsed wave) Doppler was used to demonstrate the magnitude, duration, and direction of superficial veins and perforator veins.

Reflux was defined as flow retrograde to the direction of physiological flow and lasting for > 0.5 seconds [26].

Informed consent was received from all patients prior to surgery.

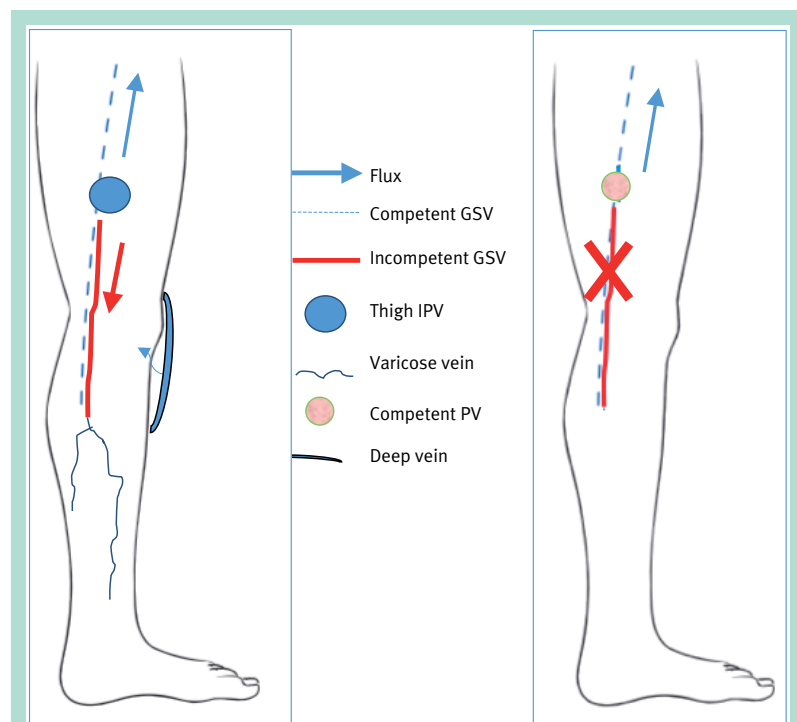


FIGURE 1 : The COPIOUS approach is based on this pathophysiologic theory; only the incompetent GSV (left) is treated by endovenous treatment or stripping and the refluxing PV is preserved.

Procedure

Indications for treatment include clinically significant symptoms of venous insufficiency and current or prior venous ulceration as well as DUS showing axial reflux greater than 0.5 seconds in duration and a patent deep venous system.

Absolute contraindications include restricted mobility and deep venous obstruction with the superficial system vital to allow venous return.

Relative contraindications include allergy and severe coagulopathy or thrombophilia.

Saphenous vein ablation consists of using either a radiofrequency ablation (RFA) system or endovenous laser ablation (EVLA) system, or surgical procedure such as stripping and phlebectomy, or ultrasound guided foam sclerotherapy.

All treatments were performed by two experienced surgeons.

Follow up

A clinical examination and DUS were performed between 1 and 3 months post surgery by the surgeons.

Physicians assessed patient's signs and symptoms utilising venous clinical severity score (VCSS) and completed CEAP classification. In the case of treatment failure: occlusion of the perforating vein or the entire GSV, follow-up has been stopped.

Long term follow-up was done by an independent angiologist.

Ultrasound examination included measuring the external (adventitia-to-adventitia) diameters of the GSV in the standing position, the patency of the thigh perforating vein and the competent GSV and characteristics of outflow and reflux.

Endpoints

The primary endpoint was the patency of the thigh perforating vein and the conserved proximal GSV. The secondary endpoints were the absence of reflux in the perforating vein and an ascending flow in the proximal GSV, the absence of reflux in this GSV, improvement of the perforating vein and GSV diameter after treatment, improvement of CEAP and VCSS, presence of recurrent varices, side effects such as pigmentation, thrombosis, pain.

Statistical analysis

A descriptive analysis was performed on inclusion and per-operative data, giving the mean, standard deviation, median (and range) for quantitative data, and number and percentage for qualitative measures (and exact 95% confidence interval).

CEAP was analysed as an ordinal variable, VCSS as a continuous variable using both parametric and non-parametric tests. Differences were considered significant at the 95% level ($p < 0.05$).

Results

Clinical data

57 subjects were enrolled and 58 legs (bilateral disease in 1 patient) were treated.

The patients were mostly women ($n = 33$; 58%), and the median age was 57 years (range; 25-84).

The CEAP is set out in **Table 1**.

At baseline, the mean VCSS for 16 legs was 5 (2.1) ranging from 2, representing uncomplicated varicose veins or venous oedema with ankle swelling in the evening, to 8 in patient with induration and skin pigmentation.

The VCSS improved at 3 months after surgery reaching a value of 2 (1.2) from 0 to 4 for 15 treated legs.

	Inclusion n (%) 17 patients	3 months n (%) 15 patients
C-Class of CEAP stage		
Co no evidence of venous disease (yes)	0 (0.0)	2 (13.3)
C1 superficial reticular veins (yes)	0 (0.0)	9 (60)
C2 simple varicose veins (yes)	8 (47)	1 (6.7)
C3 oedema of venous origin (yes)	5 (29.4)	0 (0.0)
C4 skin pigmentation in the ankle area (yes)	4 (23.5)	3 (20)
C5 healed venous ulcer (yes)	0 (0.0)	0 (0.0)
C6 open venous ulcer (yes)	0 (0.0)	0 (0.0)

TABLE 1 : Initial characteristics of treated patients at inclusion and 3 months.

Treatment procedure

57 subjects were enrolled and 58 legs (bilateral disease in 1 patient) were treated.

The “COPIOUS” study: “COnservative thigh Perforating surgery by selective ablation of Incompetent saphenOUS vein”.

The patients were mostly women (n = 33; 58%), and the median age was 57 years (range; 25-84).

Twenty-seven patients were treated with radiofrequency ablation (RFA), 29 with conventional surgery (high ligation and stripping) and two with endovenous laser therapy (EVLT).

Study design

Efficacy analysis

Primary endpoint

The analysis was performed on 53 veins from 52 patients. During the early visit (1-3 months), 92.5% [95% CI: 85.4-99.6], n=49 thigh perforating veins were still patent. One was not found during DUS.

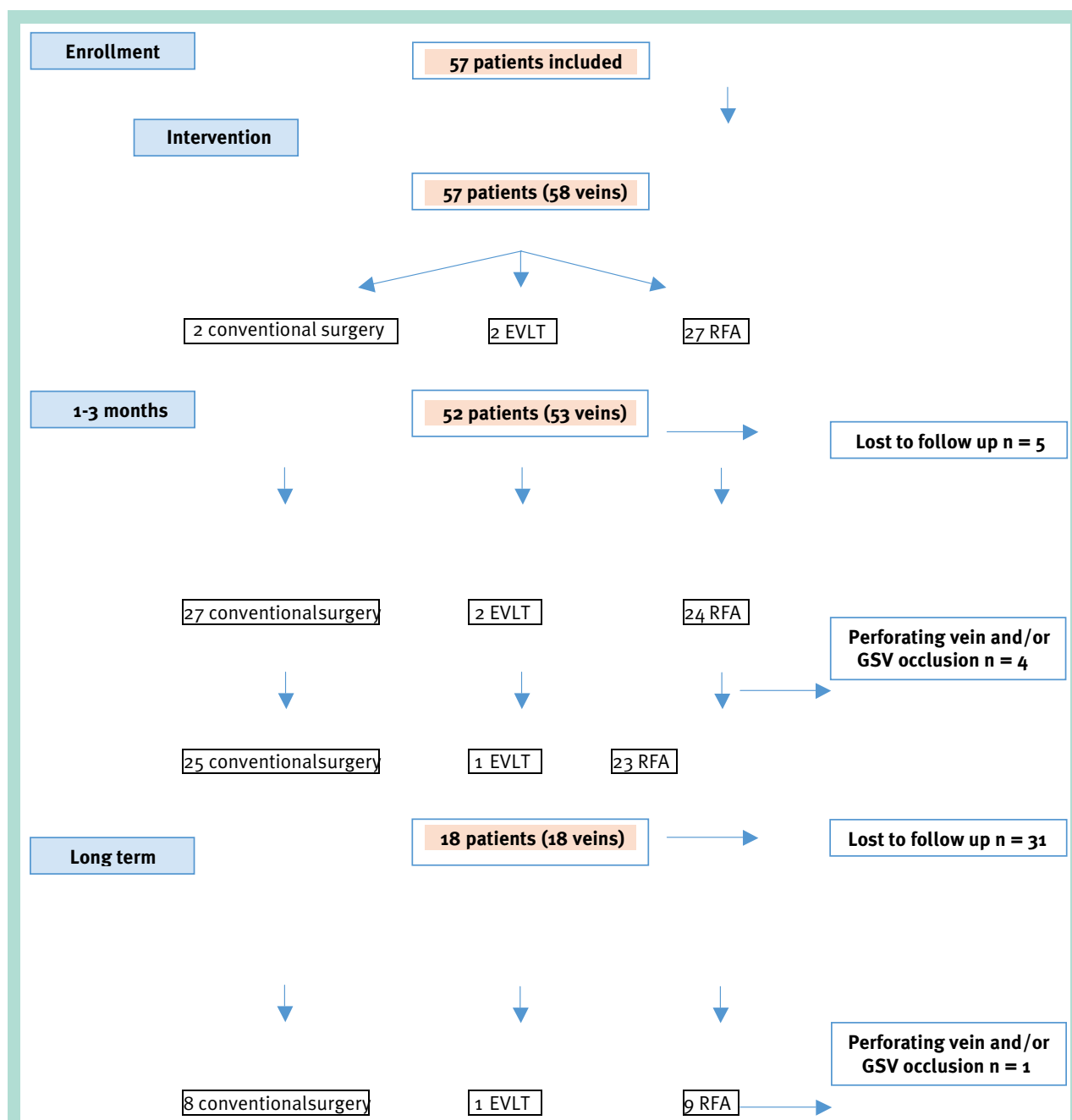


FIGURE 2 : Patients inclusion in the study.

Three (5.7%) perforating veins were occluded, treated by EVLT for one and conventional surgery for the two others (**Figure 2**).

The proximal GSV was selectively preserved with the obliteration of the incompetent part in 49 cases (92.5%).

Long term follow-up was completed in 18 patients (18 veins).

The median time of follow-up was 22.5 months (6-63 months).

Only in one patient the GSV was occluded and the PV has not been found (**Table 2**).

Secondary endpoints

At the first visit (1-3 month), all the patent perforating vein (n = 49) had an ascending flow in the proximal GSV.

Absence of reflux was also found in 96% (n = 2) of the patent perforating veins. All the preserved GSV (n = 48) were still competent.

GSV diameter improved from a median of 4.3 mm (2.5-6 mm) to 4.0 mm (1.6-5 mm) and perforating vein diameter improved from a median of 4 mm (2-9 mm) to 3 mm (1.8-5 mm).

Functional stage was improved at 3 months (**Table 1**).

No residual superficial varicose vein was demonstrated in 96.2% of patients (n = 51/53) at 3-month follow-up. There were no adverse events either during the surgical procedure.

The majority of side effects occurred the first week, the most common being ecchymosis.

Other adverse events were rare most resolved without treatment.

One superficial venous thrombosis and one contralateral venous thrombosis, resolved fully in the 8 days control under treatment by low molecular weight heparin, one infection at an incision point, pigmentation in two cases.

During long-term follow-up, 82.4% (n = 14) of the patent PV were still competent (**Table 2**). Two patients (11.8%) had recurrent varicose veins.

One had a successful complementary sclerotherapy treatment.

	PV	GSV
Patency (yes)	94.4% (n = 17/18)	94.4% (n = 17/18)
Reflux (yes)	17.6% (n = 3/17)	5.9% (n = 1/17)

TABLE 2 : Long-term follow-up.
 PV: perforating vein, GSV: Great saphenous vein

Discussion

studies on the anatomic distribution of venous insufficiency in patients with CVI have shown that PV incompetence is present in approximately 20% of limbs [8, 9].

The hemodynamic significance of IPV has been a subject of debate.

There are argument that IPV are not the major cause of recurrent varicosities (3), which are a result of the natural history of the disease itself, irrespective of IPV status.

Labropoulos [10] notices that PV reflux was always associated with reflux in the superficial vein connected to it. Recurrence rates could be reduced by changing the primary operation.

The aim of COPIOUS is a segmental treatment of the incompetent distal GSV to restore the hemodynamic by maintaining the drainage in the proximal competent GSV eliminating the thigh PV reflux point.

It also preserves a part of the GSV for use as a future vascular graft and we can conserve the flow of PV to the deep venous system.

The difficulty is the removal of the distal saphenous trunk without occluding the thigh PV.

In our study PV and competent proximal GSVs were successfully preserved in more than 90% of cases at early and long-term follow-up, which was similar after endovenous treatment or traditional surgery.

Reflux in PV disappeared in 96% of patients.

The mean diameter of the PV and the proximal GSV was reduced at 3 months sonographic follow-up. There was no statistically significant difference probably because of low power. CEAP "C" classification and VCSS improved after three months of follow-up.

The varicose vein recurrence rate was low but only the third of the patients followed in the long term.

The hemodynamic results were fairly stable after 22 months median follow-up, with three moderate refluxing PV and a no statistically significant improvement in GSV hemodynamics in more than 90% of cases compared with preoperative.

These results suggest that the hemodynamics and diameter of the thigh PV can be improved using a treatment focusing on the incompetent GSV.

Physicians must decide when ablation of only a part of GSV would be feasible, using endovenous or surgical treatment.

Personalized medicine is very important and an incompetent GSV associated with IPV is not the only determinant for the ablation of the GSV in patients with varicose veins.

Our study has some limitations.

The “COPIOUS” study: “Conservative thigh Perforating surgery by selective ablation of Incompetent saphenOUS vein”.

It has a selective study population and the number of patients on long term follow-up were not enough to draw statistically significant results.

The study could also have been supplemented by a quality of life questionnaire like The Chronic Venous Insufficiency Questionnaire (CIVIQ [27]).

This preliminary study would lead to larger prospective series.

From the data in our study and the observations in previous studies of patients with primary venous disease, it would be safe to assume that reflux in the PV occurs only in the presence of incompetent superficial veins that act as a capacitor for the refluxing PV.

As the local hemodynamic conditions change and as intravenous pressure increases, the diameter of the PV increases, and the PV valve becomes incompetent.

This may be in combination with or separate from primary venous wall disease.

Because there is sufficient evidence that correction of reflux in the superficial veins can correct PV and halt CVI progression [28-31, 10], abolishing superficial vein reflux seems appropriate.

By this approach ablation of the GSV will be prevented when there is a competent segmental GSV with an intact terminal valve reflux at the SFJ.

The major argument in favour of this conservative approach is the physiological role that the proximal GSV could play in superficial drainage if it performs its function properly and to a lesser extent its availability as a revascularization material in cardiovascular operations.

In conclusion, the **CO**nservative thigh **P**erforating surgery by selective ablation of **I**ncompetent saphen**OU**S vein (COPIOUS) is feasible and has good technical success rates and clinical results for treating varicose vein disease in patients with proximal segmental GSV reflux and a competent terminal valve.

References

1. Glociczki P., Bergan J.J., Rhodes J.M., Canton L.G., Harmsen S., Ilstrup D.M. Mid-term results of endoscopic perforator vein interruption for chronic venous insufficiency: lessons learned from the North American subfascial endoscopic perforator surgery registry. The North American Study Group. *J. Vasc. Surg.* mars 1999 ; 29(3) : 489-502.
2. Delis K.T., Husmann M., Kalodiki E., Wolfe J.H., Nicolaides A.N. In situ hemodynamics of perforating veins in chronic venous insufficiency. *J. Vasc. Surg.* 1 avr 2001 ; 33(4) : 773-82.
3. Naylor A.R., Forbes T.L. Trans-Atlantic Debate: Whether Venous Perforator Surgery Reduces Recurrences. *Eur. J. Vasc. Endovasc. Surg.* 1 sept 2014 ; 48(3) : 246-7.
4. Whiteley M.S., O'Donnell T.F. Debate: Whether venous perforator surgery reduces recurrences. *J. Vasc. Surg.* 1 sept 2014 ; 60(3) : 796-803.
5. Khilnani N.M. Duplex ultrasound evaluation of patients with chronic venous disease of the lower extremities. *AJR Am. J. Roentgenol.* mars 2014 ; 202(3) : 633-42.
6. Cavezzi A., Labropoulos N., Partsch H., Ricci S., Caggiati A., Myers K., et al. Duplex ultrasound investigation of the veins in chronic venous disease of the lower limbs--UIP consensus document. Part II. Anatomy. *Eur. J. Vasc. Endovasc. Surg. Off. J. Eur. Soc. Vasc. Surg.* mars 2006 ; 31(3) : 288-99.
7. Delis K.T., Ibegbuna V., Nicolaides A.N., Lauro A., Hafez H. Prevalence and distribution of incompetent perforating veins in chronic venous insufficiency. *J. Vasc. Surg.* 1 nov 1998 ; 28(5) : 815-25.
8. Labropoulos N., Delis K., Nicolaides A.N., Leon M., Ramaswami G. The role of the distribution and anatomic extent of reflux in the development of signs and symptoms in chronic venous insufficiency. *J. Vasc. Surg.* mars 1996 ; 23(3) : 504-10.
9. Labropoulos N., Mansour M.A., Kang S.S., Glociczki P., Baker W.H. New insights into perforator vein incompetence. *Eur. J. Vasc. Endovasc. Surg. Off. J. Eur. Soc. Vasc. Surg.* sept 1999 ; 18(3) : 228-34.
10. Labropoulos N., Tassiopoulos A.K., Bhatti A.F., Leon L. Development of reflux in the perforator veins in limbs with primary venous disease. *J. Vasc. Surg.* mars 2006 ; 43(3) : 558-62.
11. Labropoulos N., Touloupakis E., Giannoukas A.D., Leon M., Katsamouris A., Nicolaides A.N. Recurrent varicose veins: Investigation of the pattern and extent of reflux with color flow duplex scanning. *Surgery.* 1 avr 1996 ; 119(4) : 406-9.
12. O'Donnell T.F., Balk E.M., Dermody M., Tangney E., lafrati M.D. Recurrence of varicose veins after endovenous ablation of the great saphenous vein in randomized trials. *J. Vasc. Surg. Venous Lymphat Disord.* 1 janv 2016 ; 4(1) : 97-105.
13. Rasmussen L., Lawaetz M., Bjoern L., Blemings A., Eklof B. Randomized clinical trial comparing endovenous laser ablation and stripping of the great saphenous vein with clinical and duplex outcome after 5 years. *J. Vasc. Surg.* août 2013 ; 58(2) : 421-6.
14. Rass K., Frings N., Glowacki P., Hamsch C., Gräber S., Vogt T., et al. Comparable effectiveness of endovenous laser ablation and high ligation with stripping of the great saphenous vein: two-year results of a randomized clinical trial (RELACS study). *Arch Dermatol.* janv 2012 ; 148(1) : 49-58.
15. Bush R.G., Bush P., Flanagan J., Fritz R., Gueldner T., Koziarski J., et al. Factors Associated with Recurrence of Varicose Veins after Thermal Ablation: Results of The Recurrent Veins after Thermal Ablation Study. *Sci World J [Internet].* 27 janv 2014.
16. Blomgren L., Johansson G., Dahlberg-Akerman A., Thermaenius P., Bergqvist D. Changes in superficial and perforating vein reflux after varicose vein surgery. *J. Vasc. Surg.* août 2005 ; 42(2) : 315-20.
17. Dillavou E.D., Harlander-Locke M., Labropoulos N., Elias S., Ozsvath K.J. Current state of the treatment of perforating veins. *J. Vasc. Surg. Venous Lymphat. Disord.* 1 janv 2016 ; 4(1) : 131-5.

18. van Gent W.B., Catarinella F.S., Lam Y.L., Nieman F.H.M., Toonder I.M., van der Ham A.C., et al. Conservative versus surgical treatment of venous leg ulcers: 10-year follow up of a randomized, multicenter trial. *Phlebology* mars 2015 ; 30(1 Suppl) : 35-41.
 19. Barwell J.R., Davies C.E., Deacon J., Harvey K., Minor J., Sassano A., et al. Comparison of surgery and compression with compression alone in chronic venous ulceration (ESCHAR study): randomised controlled trial. *Lancet Lond. Engl.* 5 juin 2004 ; 363(9424) : 1854-9.
 20. Lawrence P.F., Alktaifi A., Rigberg D., DeRubertis B., Gelabert H., Jimenez J.C. Endovenous ablation of incompetent perforating veins is effective treatment for recalcitrant venous ulcers. *J. Vasc. Surg.* sept 2011 ; 54(3) : 737-42.
 21. Harlander-Locke M., Lawrence P., Jimenez J.C., Rigberg D., DeRubertis B., Gelabert H. Combined treatment with compression therapy and ablation of incompetent superficial and perforating veins reduces ulcer recurrence in patients with CEAP 5 venous disease. *J. Vasc. Surg.* févr 2012 ; 55(2) : 446-50.
 22. Campbell W.A., West A. Duplex Ultrasound Audit of Operative Treatment of Primary Varicose Veins. In: *Phlebology '95* [Internet]. Springer, London; 1995 [cité 26 sept 2017]. p. 407-9. Disponible sur: https://link.springer.com/chapter/10.1007/978-1-4471-3095-6_179
 23. Ozsvath K., Hager E., Harlander-Locke M., Masuda E., Elias S., Dillavou E.D. Current techniques to treat pathologic perforator veins. *J. Vasc. Surg. Venous Lymphat. Disord.* 1 mars 2017 ; 5(2) : 293-6.
 24. Eklöf B., Rutherford R.B., Bergan J.J., Carpentier P.H., Gloviczki P., Kistner R.L., et al. Revision of the CEAP classification for chronic venous disorders: consensus statement. *J. Vasc. Surg.* déc 2004 ; 40(6) : 1248-52.
 25. Gloviczki P., Comerota A.J., Dalsing M.C., Eklof B.G., Gillespie D.L., Gloviczki M.L., et al. The care of patients with varicose veins and associated chronic venous diseases: clinical practice guidelines of the Society for Vascular Surgery and the American Venous Forum. *J. Vasc. Surg.* mai 2011 ; 53(5 Suppl): 2S-48S.
 26. Labropoulos N., Tiongson J., Pryor L., Tassiopoulos A.K., Kang S.S., Ashraf Mansour M., et al. Definition of venous reflux in lower-extremity veins. *J Vasc Surg.* 1 oct 2003 ; 38(4) : 793-8.
 27. Launois R., Reboul-Marty J., Henry B. Construction and validation of a quality of life questionnaire in chronic lower limb venous insufficiency (CIVIQ). *Qual. Life Res. Int. J. Qual. Life Asp. Treat. Care Rehabil.* déc 1996 ; 5(6) : 539-54.
 28. Sales C.M., Bilof M.L., Petrillo K.A., Luka N.L. Correction of lower extremity deep venous incompetence by ablation of superficial venous reflux. *Ann. Vasc. Surg.* mars 1996 ; 10(2) : 186-9.
 29. Walsh J.C., Bergan J.J., Beeman S., Comer T.P. Femoral venous reflux abolished by greater saphenous vein stripping. *Ann. Vasc. Surg.* nov 1994 ; 8(6) : 566-70.
 30. Labropoulos N., Tassiopoulos A.K., Kang S.S., Mansour M.A., Littooy F.N., Baker W.H. Prevalence of deep venous reflux in patients with primary superficial vein incompetence. *J. Vasc. Surg.* oct 2000 ; 32(4) : 663-8.
 31. Stuart W.P., Adam D.J., Allan P.L., Ruckley C.V., Bradbury A.W. Saphenous surgery does not correct perforator incompetence in the presence of deep venous reflux. *J. Vasc. Surg.* 1 nov 1998 ; 28(5) : 834-8.
-