

Acute iliofemoral venous thrombosis: why should clots be removed?

Alimi Y.

Résumé

L'«American College of chest physicians» a récemment recommandé (Evidence-Based Clinical Practice Guidelines - 8th Edition, 2008), la réalisation d'une thrombolyse veineuse dirigée sur cathéter et/ou d'une thrombectomie veineuse, chez des patients sélectionnés, en bon état général, et présentant une thrombose veineuse profonde (TCP) extensive ilio-fémorale, de survenue récente. Afin de réduire les risques immédiats et surtout le syndrome post-thrombotique, ce traitement doit être mise en œuvre dans les plus brefs délais après le début des symptômes, avec correction simultanée des lésions veineuses associées (syndrome de Cockett, thrombus marginé, ...) par angioplastie et mise en place d'endoprothèses.

L'analyse de la littérature montre la survenue d'une maladie post-phlébitique chez 85 à 88 % des patients traités médicalement pour une TVP intéressant 3 ou 4 niveaux, après une surveillance moyenne de 6,6 ans. Une prévalence de claudication veineuse à 5 ans est notée chez 43,6 % des patients traités pour une TVP ilio-fémorale. Un traitement agressif offre une perméabilité secondaire ilio-fémorale variant de 81 à 88 % à 5 ans. Une thrombolyse et/ou thrombectomie veineuse doit être proposée préférentiellement à des patients jeunes présentant une TVP récente et extensive, sans inflammation abdomino-pelvienne, et en cas de phlegmasia caerulea menaçant la viabilité du membre.

Mots clés : thrombose veineuse profonde; thrombolyse veineuse ; thrombectomie veineuse.

Summary

The American College of chest physicians has recently recommended (Evidence-Based Clinical Practice Guidelines - 8th Edition, 2008), the use of catheter-directed or venous thrombectomy, in selected good-risk patients presenting with extensive acute proximal DVT (iliofemoral DVT). In order to reduce acute symptoms and postthrombotic morbidity, this treatment should be performed during the first days after the beginning of clinical symptoms, with correction of underlying venous lesions (May-Thurner syndrome, residual clots, ..) using balloon angioplasty and stents.

After a mean surveillance period of 6.6 years, analysis of the literature shows that 3 and 4 level acute deep venous thrombosis (DVT) treated medically are responsible for a post-thrombotic syndrome in respectively 85 and 88 %. After occurrence of an iliofemoral DVT, a 5-year prevalence of venous claudication is noted in 43.6 %. An aggressive early treatment is associated with a 5-year iliofemoral venous secondary patency rate of 81 to 88 %. Venous thrombectomy and/or thrombolysis should preferably be offered to young individuals with fresh thromboses, and without abdominopelvic inflammation, and to patients with limb-threatening phlegmasia.

Keywords : Deep venous thrombosis; venous thrombolysis; venous thrombectomy.

Introduction

When a proximal deep venous thrombosis (DVT) occurs, the goals of therapy are (1) to prevent fatal embolism and extension or recurrence of the deep venous thrombus and (2) minimize the early and late sequelae of DVT.

Anti-thrombotic therapy can accomplish the former but contributes little to the second goal. Particularly in iliofemoral DVT, progressive swelling of the leg can lead to phlegmasia cerulea dolens and increased compartmental pressure which can progress to venous gangrene and limb loss.

Later, the development of severe post-thrombotic syndrome can result from persistent obstruction of the venous outflow and/or loss of valvular competence and pulmonary embolism can lead to pulmonary chronic hypertension.

According to the literature, patients with acute deep venous

thrombosis (DVT) involving the iliofemoral venous system experience the most severe post-thrombotic sequelae (1-3).

Rationale : Is clot removal necessary?

In the USA, it has been estimated that DVT affects more than 250,000 patients per year, and pulmonary embolism is responsible for 50,000 deaths annually (4-5).

Adequate anticoagulation decreases the risk of recurrent venous thromboembolism by approximately 80 %, from 29 % to 47 % untreated to 5 % to 7 % treated.

During adequate anticoagulant therapy, the risk of fatal PE is very low, 0.4 % and 0.3 % during and after treatment of DVT and 1.5 % and 0 % during and after treatment of PE (6-7).

However, the long term clinical outcome of patients following an episode of DVT of the lower extremity is uncertain. In many of these patients chronic venous insufficiency (CVI) may occur. CVI is thought to be caused by damage to the valve either by the inflammatory process associated with thrombus formation or by venous hypertension due to either outflow obstruction in incomplete or absent recanalization, or proximal valve incompetence.

Early studies suggested that the prevalence of PTS resulted in cutaneous ulceration in more than 80 % of the affected limbs after 10 years (8). However, more recent studies have mentioned a lower incidence of severe changes, with 25 to 33 % of affected extremities having no trouble at all, only 15 to 30 % developing hyperpigmentation, and 3 to 5 % progressing to ulceration (9).

In 1996, *Van Haarst et coll.* (10) found 48 % of post-thrombotic venous segments had valve incompetence in 24 patients examined with duplex scanning after a mean interval of 34 months following the DVT, which had been treated with a complete and control medical treatment. This figure increased to 60 % after 86 months. This study highlights a significant association between initial extensive thrombosis and multi-segment long term reflux, which represent a high risk group.

After a median follow-up period of only 3 years (range 1 to 6), *Johnson et al.* noted that features of PTS were present in 41 % of the 83 limbs with edema and/or hyperpigmentation, and ulceration in 2 limbs, but only 22 % of patients when the initial extension of the thrombus involved a single venous segment compared to 46 % for multi-segment involvement (11). At the time of the last follow-up, the Duplex scanning examination showed that 88 % of limbs had multi-segment involvement in the PTS group and also 71 % in the asymptomatic group (4, 11).

Interestingly, after a mean follow-up period of 6.6 years, *Ziegler et al.* mentioned that the percentage of patients presenting with PTS increased to 82 % in a population of 132 patients, with the highest risk for developing severe PTS after level-four DVT (12).

In 2004, *Delis et al.* noted 43.6 % of their 39 patients presented a venous claudication after a median follow-up period of 5 years (range 1-23 years) following an iliofemoral venous DVT treated conservatively with anticoagulation. Seventeen patients developed venous claudication in the limb with prior proximal DVT during treadmill exercise at an initial claudication distance of 130 m (range 105-268 m), and the severity of the claudication compelled 6 of them to discontinue the treadmill at an absolute claudication distance of 241 m (range 137-298 m). Prior iliofemoral venous DVT caused outflow impairment, as well as a high residual venous volume and reflux, resulting in markedly compro-

mised clinical assessment and quality of life (2).

Furthermore, DVT and PTS remain of socio-economic importance: a 15-year follow-up analysis in Sweden pointed out that the additional long-term health care cost of possibly disabling post-thrombotic complications are about 75 % of the cost of primary DVT (13).

Techniques: How to perform venous clot removal?

Surgical venous thrombectomy technique

- Preoperative preparation (14)

Because most patients do not develop this severity of extensive disease, the likelihood of identifying an underlying thrombophilia is high; blood is then sent for a full thrombophilia evaluation with special attention to the most frequent abnormalities: antiphospholipid antibody, factor V Leiden, prothrombin gene mutation and homocystein, which are reliable in patients who have already undergone anticoagulation treatment.

The full extent of the thrombus should be defined before surgery, and particular attention should be given to the status of the vena cava.

In emergency situations, no more than two anatomical exams are generally necessary (Fig. 1A & 1B):

- *Duplex scanning of the veins of the lower limbs:* makes it possible to evaluate the extent of the thrombus into the deep and superficial veins, and also to determine if the clot is "fresh" (homogenous clot with neither adhesion to the vein wall nor vein enlargement),
- *Spiral chest, abdominal and pelvic CT scan with contrast injection:* make it possible to evaluate for pulmonary emboli, chest, abdominal or pelvic tumors or inflammation, and the proximal extent of thrombus.

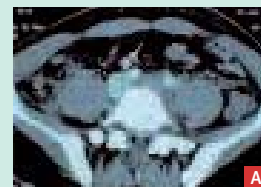

FIGURE 1 : Preoperative exams :

Fig. 1A: PhleboCT scan showing a thrombosis of the left common iliac vein (arrow) with patent IVC.



Fig. 1 B: Duplex scanning showing a fresh non adherent clot.

Indications for proximal venous surgical thrombectomy are listed in Table 1.

- Age under 60 years old, with a life expectancy of at least 5 years,
- The thrombus should be < 7 days old. Estimation of the age of the thrombus is given by the onset of the first symptoms, the characteristic of the clot at duplex ultrasound (DUS) scan (hypoechoic and nonadherent clot with dilatation of the vein) and CT scan (hypodense clot with peripheral enhancement and vein dilation),
- No abdominal or pelvic tumor or inflammation on the preoperative CT scan,
- No contraindication to anticoagulant therapy,
- No arterial limb disease (to perform the AV fistulae),
- Ability to walk on postoperative day one (exclusion of patients with severe polytrauma, major neurological deficit...),
- N.B.: Pregnancy, post-delivery, and thrombolytic treatment failure are not a contraindication to venous thrombectomy.

After introduction of intravenous anticoagulant therapy, the patient is cautiously moved and shaved to avoid clot fragmentation and migration that could cause pulmonary embolism. The patient and his family are made aware of the possibility of endovascular or surgical closure of the AV fistulae, 6 weeks after the first surgical procedure.

TABLE 1: Indications for iliofemoral venous thrombectomy

- Operative details.

General anesthesia is preferred in most patients, and an autotransfusion device is made available during the procedure.

A longitudinal groin incision is made with exposure of the common femoral vein, femoral vein, saphenofemoral junction and profunda femoris vein, as well as the first centimeters of the superficial femoral artery (Fig. 2A).

Before any intravenous manipulation, the anesthesiologist is asked to apply a positive end-expiratory pressure of 10 mmHg H₂O in order to avoid the risk of clot embolization. An intravenous heparin bolus of 50 UI/kg is given if the patient is already being treated with intravenous heparin; if not being treated, and then 100 UI/kg is given.

A 1.5-cm-long transverse venotomy is made at the saphenofemoral junction on a femoral vein which is generally large and distended. The infrainguinal thrombectomy is usually performed first, after the femoral venotomy (Fig. 2B).

The leg is elevated and wrapped tightly with a rubber bandage. The foot is dorsiflexed and the leg milked to remove the clot from below.

If these maneuvers are unsuccessful, and the infra-inguinal clot persists, Comerota (15) proposed exposing the posterior tibial vein and passing a N° 3 or 4 Fogarty balloon catheter proximally from below to exit the common femoral venotomy.

The stem of a large silastic intravenous catheter (14 gauge) is cut from its hub and slid halfway on to the Fogarty balloon catheter passed from below, and a N° 4 Fogarty balloon catheter is placed into the other end (proximal end) of the silastic sheath.

Pressure is applied to the two balloons (this firmly secures the catheters inside the sheath), and the balloon catheters are guided distally from above, through the venous valves and clotted veins to exit at the level of the posterior tibial venotomy.

The operating surgeon applies pressure to both syringes and guides both catheters to ensure smooth, unencumbered passage. The infra-inguinal venous thrombectomy is then performed and the passage of the catheter is repeated as required until no further thrombus is extracted (Fig. 2C).

After the infra-inguinal thrombectomy, a vascular clamp is then applied below the femoral venotomy. The proximal thrombectomy is performed by passing a N° 8 or 10 venous thrombectomy catheter into the iliac vein several times, then associated with a Vollmar ring, to remove most of the vena cava and the iliac vein thrombus (Fig. 2D).

After completion of the iliofemoral thrombectomy, the femoral venotomy is closed using a 6/0 polypropylene thread and the iliofemoral venous system is examined with intra-operative phlebography to ensure unobstructed venous drainage into the vena cava. Any underlying iliac vein stenosis is corrected with balloon angioplasty and Wallstent placement to maintain the desired luminal diameter since venous recoil is almost systematic.

An end-to-side AVF is then constructed by anastomosing the end of the transected proximal saphenous vein or a large proximal branch of the saphenous vein to the side of the proximal superficial femoral artery (Fig. 2E).

The anastomosis should be no greater than 3.5 to 4.0 mm in diameter. Frequently, the proximal saphenous vein is thrombosed and requires thrombectomy before the AVF. A wrap of polytetrafluoroethylene or silastic encircles the saphenous AVF, and a large permanent monofilament suture is looped around the wrapped vein and clipped, leaving approximately 1 inch in the subcutaneous tissue. This will guide future dissection

Acute iliofemoral venous thrombosis: why should clots be removed?

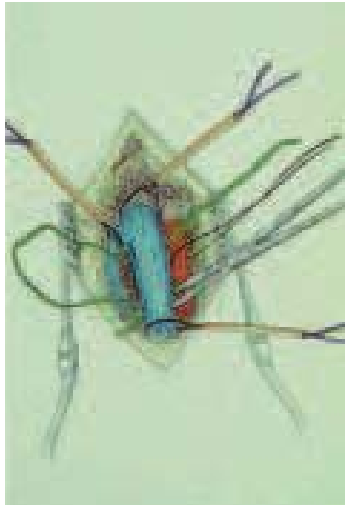


FIGURE 2A: Groin incision with exposition of the saphenofemoral junction and of the superficial femoral artery.

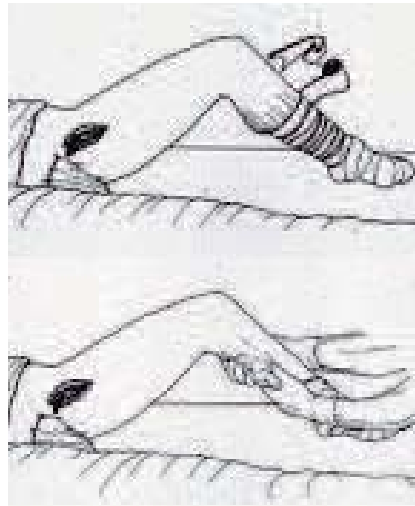


FIGURE 2B: The leg is wrapped tightly with a rubber bandage and the leg milked to remove the clot from below.



FIGURE 2C: Example of clot removal. Please, notice the imprint of the valves on this fresh clot.

for operative closure of the AVF, which generally occurs 6 weeks after the initial procedure; however, percutaneous balloon or coil occlusion of the AVF is performed earlier, and in some cases, because the AVF is well-tolerated and because the flow through the small AVF diminishes with time because of neo-intimal hyperplasia, AVF closure is not required (16).

A drain is then placed in the wound to evacuate blood and serous fluid, and exits through a separate puncture site adjacent to the incision, and the wound is closed with multilayered, running absorbable sutures to achieve a hemostatic and lymphostatic wound closure.

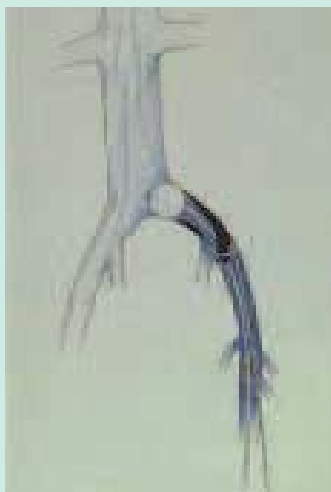


FIGURE 2D: Removal of the iliac vein thrombus by large Fogarty catheter after applying a positive end-expiratory pressure of 10 mmHg H₂O in order to avoid the risk of clot embolisation.

The patient's leg is wrapped snugly from the base of the toe to the inguinal area in double layer elastic bandages.

Full anticoagulation is continued after surgery, using first unfractionated heparin and then low molecular weight heparin in order to allow patient ambulation at postoperative day one. Oral anticoagulation is also begun when patients resume oral intake, and continued for an extended period of time- for at least 6 months to one year in all patients, and indefinitely in many. Elastic compression stockings with a 30 to 40 mm Hg ankle gradient are used in all patients to further reduce post-thrombotic complications, and the patient is asked to walk, the day after surgery.

Intra-thrombus catheter-directed thrombolysis technique

Although initial attempts to treat acute DVT with thrombolytic therapy used a peripheral intra-venous administration, treatment evolved secondarily to the catheter-directed intra-thrombus delivery of thrombolytic agents to improve lytic outcomes compared with systemic delivery.

The basic mechanism of thrombolysis is the activation of fibrin-bound plasminogen to form the active enzyme plasmin, which dissolves clots. During thrombosis, circulating Glu-plasminogen binds to fibrin and is converted to Lys-plasminogen, which has more binding sites for plasminogen activators and is more efficiently activated to plasmin than Glu-plasminogen. Intra-thrombus delivery naturally protects plasminogen activator inhibitor

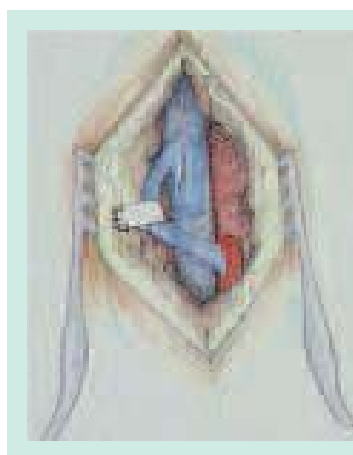

FIGURE 2E: Creation of an AV fistula with the greater saphenous vein implanted on the superficial femoral artery. A wrap of polytetrafluoroethylene encircles saphenous AVF which will guide future dissection for operative closure of the AVF.

(PAI-1) and also protects the resultant active enzyme plasmin from instantaneous neutralization by circulating antiplasmins.

Catheter-directed delivery of plasminogen activators into the thrombus accelerates thrombolysis, increasing the likelihood of a successful outcome. Because accelerated lysis reduces the overall dose and duration of plasminogen activator infusion, it is reasonable to expect that complications also will be reduced (15).

First, no contraindication to thrombolysis should be assessed: surgery within 14 days, history of CVA or CNS disease, history of major bleeding within 1 year, severe hypertension (> 180/100), known or suspected pregnancy, etc.

In the angiosuite, the popliteal vein is punctured using ultrasound guidance allowing for introduction of a lysis

catheter. In the late nineties, a double catheter-coaxial catheter system (*Mewissen Infusion Catheter / Katzen Infusion Wire; Boston Scientific*) was used with the intention to infuse the thrombolytic fluid into most of the thrombus. More recently, a long lysis catheter with a tip occluder and side holes 40-50 cm has been used (*ProInfusion Catheter; AngioDynamics*), covering most of the extension of the thrombus.

Treatment starts with the “pulse-spray” technique, where rt-PA, urokinase or streptokinase + 1000-5000 i.e. heparin is injected over the first 15-30 min in an attempt to shorten the overall treatment period. Afterwards, thrombolysis is continued by means of continuous infusion of -PA, urokinase or streptokinase + 1000 i.e. heparin per hour. The treatment is stopped when the control venogram show complete lysis of the thrombus and a D-Dimer below 10 mg/l.

Associated procedures

- *Thrombectomy and/or interruption of the inferior vena cava (IVC)*

Thrombectomy of the IVC is performed through a right transperitoneal subcostal route deflecting the duodenum and the ascending colon medially (Fig. 3A & B).

The IVC is exposed for 8 cm caudally to the renocaval confluence.

Two tapes are placed around the IVC, one just under the renal veins and another one 6 cm caudally (Fig. 3C).

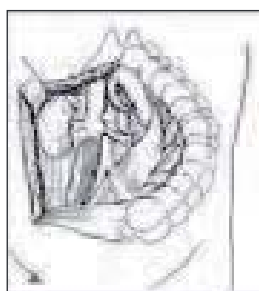


FIGURE 3A: Pre-operative phlebogram of an extensive left iliac vein and IVC thrombosis,



FIGURE 3B: Exposure of the IVC is performed through a right transperitoneal subcostal route deflecting the duodenum and the ascending colon medially.



FIGURE 3C: Two tapes are placed around the IVC, and a large Fogarty catheter is introduced cephalad into the IVC once a 2 mm cavotomy has been performed in the center of a purse string bourse.



FIGURE 3D: The balloon is inflated cephalad to the superior pole of the clot and the cavotomy is extended 2 cm.



FIGURE 3E: the Fogarty catheter is then retrieved and the upper tape is tightened once the catheter is down to it.

FIGURE 3: Thrombectomy of the inferior vena cava (IVC)

Acute iliofemoral venous thrombosis: why should clots be removed?

The lumbar and genital veins must be controlled by threads. Two 6/0 polypropylene stay sutures are placed on the IVC between the 2 tapes, at each extremity of the planned cavotomy.

If the clot reaches the renal vein or is more extensive, a Fogarty catheter is introduced cephalad into the IVC once a 2 mm cavotomy has been performed in the center of a purse string bourse.

The balloon is inflated cephalad to the superior pole of the clot and the cavotomy is extended 2 cm (Fig. 3D).

The Fogarty catheter is then retrieved and the upper tape is tightened once the catheter is down to it (Fig. 3E).

Then the lower part of the IVC is thrombectomized as previously described and the cavotomy is closed with a 6/0 polypropylene running suture.

If thrombosis does not reach the superior third of the infrarenal IVC, the cephalad tape is tightened and the iliac clot is massaged in order to mobilize it.

The cavotomy is then performed and the clot is removed with a large Fogarty catheter while taking great care to limit blood loss (16).

A median laparotomy should be used only if abdominopelvic exploration is needed or if there is a doubt about the age of the thrombosis or if an IVC filter is to be removed (in case of a clot including and going beyond a filter). A suction drain is applied next to the IVC before closure. In case of phlegmasia cerulea dolens, the procedure should begin by fasciotomy.

The risk of severe pulmonary embolism during or after venous thrombectomy was often reported in the early years, and adjuvant IVC interruption was then proposed, first by clip and recently by filter. The current techniques of positive end-expiratory pressure, used preoperatively to prevent pulmonary embolism, combined with complete thrombectomy assessment by intraoperative phlebography, make IVC interruption unnecessary in most patients.

The author only performs IVC interruption when the thrombectomy is difficult and incomplete, because of misjudgement regarding the age of the thrombus or when the AV fistula does not work adequately as a result of poor quality arterial flow (16).

Thrombectomy and thrombolysis

It has been already pointed out that both these procedures share the same goal of removing the thrombus as quickly and completely as possible; however, in the author's experience, more than half of the patients undergoing thrombectomy were not able to receive thrombolysis

because of contraindications such as pregnancy, previous recent surgery or trauma. In other cases, several authors, such as *Comerota* (15) or *Blättler* (17), proposed combining iliofemoral venous thrombectomy with distal infusion of 500,000 U of urokinase or 3 to 5 mg of recombinant tissue plasminogen activator in 150 to 200 ml of saline solution, through the groin incision and/or through a posterior tibial vein or a foot vein.

To improve the effect of the thrombolysis, *Lagardier* proposes elevating the leg and placing a large silicone tourniquet cuff on the thigh, which is then inflated up to 300 mm Hg to exclude the leg from systemic circulation. Urokinase is then infused into the leg, together with 5000 U of unfractionated heparin and up to 1000 ml of saline solution, distributed by means of leg massage, and left to act for 30 minutes.

Finally, the leg is massaged again, from the foot to the thigh, to retrieve residual loose clots, and the blood is aspirated, washed and transfused back into the patient. The distal venotomy and skin are then closed.

Endovascular treatment of iliac venous stenosis

Results of surgical venous thrombectomy and/or thrombolysis have been extensively reported and discussed (18). One of the main concerns was the risk of early rethrombosis, and our team, as others (19-23), demonstrated that this complication is mostly due to the presence of stenotic iliac lesions, whatever their cause, including extrinsic compression (generally May-Thurner syndrome), luminal webs, or residual clots. In our historic series of 77 patients treated with venous thrombectomy without stent placement, 12 early rethromboses occurred, including 8 on the left side, mainly due to May-Thurner syndrome (18). *Mickley et al.* reported that such stenotic lesions led to 73 % of rethrombosis if left untreated (20). This is the reason why our technique is now to introduce a sheath through the great saphenous vein and to perform an ilio-cavography before completion of the AV fistula.

If an obstructive lesion is found (stenosis, occlusion, or residual adherent clot), the vein is catheterized with a 0.035 in guidewire and angioplasty is performed, generally using a 12-mm diameter balloon. Long (60 to 90 mm) and large (12 to 16 mm) self-expanding stents (*Wallstent*, *Boston Scientific*, *Schneider*, *Minneapolis, Minn*) are then deployed, protruding into the IVC, in order to avoid any risk of migration, and dilated with a 15-mm balloon before completion angiography. If the iliac vein is fully patent, the AV fistula is created.

Results

The results of surgical thrombectomy have been extensively reported and discussed. Mortality is very low in recent series reported by experienced groups: we had no deaths in our recent experience of 75 patients (18) and have had no more deaths since the introduction of concomitant iliac stenting (29 patients) (19).

- Eklöf reported a 1 % mortality rate on 203 consecutive patients, non related to the thrombosis (22).

-Pulmonary embolism (PE) is also rarely severe.

- Like Blättler (17), we had no symptomatic postoperative PE in our experience, but Plate (24) reported 45 % of positive perfusion scans on admission and 20 % of additional defects postoperatively but none when an AVF was constructed.

The main other complication is rethrombosis. It is commonly caused by underlying venous lesions, such as in May-Thurner syndrome, incomplete thrombectomy, inappropriate indication, failure of the AVF or inadequate anticoagulation.

Use of an AVF has been shown to reduce the rethrombosis rate: Hutschenreiter had 33 % of iliac patency with AVF

versus 54 % without (21). According to this technique, the primary patency rate was 87 % at three months in a meta-analysis performed by Eklöf while reviewing 527 cases (22).

Residual lesions on the iliac veins and IVC represented a major cause for rethrombosis; in our experience, it occurred in 7 % of the cases in the absence of iliac stenosis versus 26 % in cases of mild stenosis and 56 % in cases of tight stenosis (18).

Obstruction was treated by cross pubic venous bypass until Mickley (20) showed that while leaving iliac lesions untreated, the reocclusion rate was 73 % versus 13 % after stenting.

Stenting has documented safety and effectiveness in the treatment of chronic ilio caval venous lesions, and is now used during venous thrombectomy to treat the lesions that compromise patency (extrinsic compression, luminal webs, or residual clot) while avoiding a long and complex concomitant procedure (fig. 4A & B).

This endovascular procedure can be performed during surgical thrombectomy and usually takes 10 minutes to be completed.

Table 2 summarize the results of the published reports (23-35).

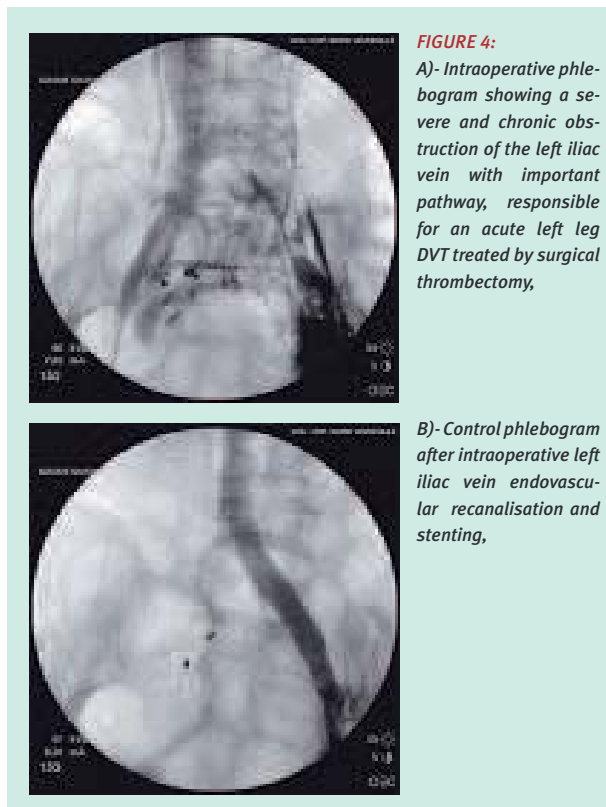
In a group of 29 consecutive patients who had surgical thrombectomy with concomitant stenting, our primary patency rate was 89.7 % at one month and 79 % at 60 months (19).

The only prospective randomized study comparing surgical thrombectomy combined with a temporary fistula versus conventional anticoagulation treatment was performed in 1984 by Plate *et al.* (24).

Of the 58 patients initially included in the study, 30 (17 medical and 13 surgical) were available for follow-up 10 years after the initial thrombotic event.

Despite a continuous supply with compressive stockings, 71 % of the medically-treated patients developed leg swelling and 17 % leg ulcers, with only 33 % with late iliac vein patency and 43 % with preserved valvular function of the popliteal vein.

In the surgical group, leg swelling and ulcers were less frequent (respectively 46 and 8 %), iliac vein patency was noted in 83 % of cases ($p < 0.05$) and minimal popliteal reflux was recorded in 78 % of cases ($p = ns$). It is worthwhile mentioning that 7 of the 13 patients in the surgical group had underlying iliac vein compression responsible for 4 cases of early rethrombosis; intra-operative treatment of these lesions by stents, as done today, would have made possible improvement in the early and long-term results of this study.



Acute iliofemoral venous thrombosis: why should clots be removed?

Study	n	Technical success (%)	Primary at 12 months (%)	Patency Late (%)	Late SP (%)
Thombolysis:					
O'Sullivan	19		Stent +: 92		
Mewissen	144	88 > 50% of lysis	Stent -: 53;	stent +: 74	
Comerota	58	84	Stent -: 71;	stent +: 89	
Patel	10	100			
Abou Rahma	10	90			
Mechanical thrombectomy + thrombolysis:					
Vedantham	14	100			
Kwak	22	96	95	24 mo: 95	24 mo: 100
Surgical thrombectomy:					
Mickley*	8	95	73	24 mo: 95	24 mo: 100
Wohlgemuth*	35	97	76	48mo: 66	48 mo: 69
Schwarzbach*	20	100		21 mo: 80	21 mo: 90
Our series*	29	100	79	60 mo: 79	60 mo: 86

*SP, secondary patency rate; *, Intention to treat.*

TABLE 2: Comparison of the results of venous thrombolysis and venous thrombectomy for acute deep vein thrombosis.

The same remark can be made with regard to the retrospective study by *Törngren et al.* (25) who compared 30 pregnant/puerperal women with iliofemoral DVT treated by surgical thrombectomy with 25 treated medically; intra-operative stenting may have prevented 2 early and 8 late iliac vein re-thromboses in the surgical group, and thus improved the results.

Conclusion

The severity of post-phlebitic syndrome in patients presenting with extensive iliofemorocaval DVT leads us to propose clot removal in a well-selected population. Venous thrombectomy and/or thrombolysis should preferably be offered to young individuals with fresh thromboses, and without abdominopelvic inflammation, and to patients with limb-threatening phlegmasia.

Early diagnosis is most important and particular attention to duplex scanning and phlebo-TDM are mandatory for assessing the age and extent of the thrombus in the entire venous system. Surgical techniques have been improved, first by creation of an AV fistula, and

now by concomitant stenting of the iliac lesions that compromise patency (extrinsic compression, luminal webs, or residual clots). Such aggressive treatment must be compared with conventional anticoagulation treatment in a prospective randomized fashion and the patients followed by morphological, physiological and clinical examinations.

References

1. Akesson H., Brudin L., Dahlstrom J.A., Ohlin P., Plate G. Venous function assessed during a 5 year period after acute ilio-femoral venous thrombosis treated with anticoagulation. *Eur J Vasc Surg* 1990;4:443-8.
2. Delis K.T., Bountouroglou D., Mansfield A.O. Venous claudication in iliofemoral thrombosis: long-term effects on venous hemodynamics, clinical status, and quality of life. *Ann Surg* 2004;239:118-26.
3. Skull K.C, Nicolaidis A.N., Fernandes e Fernandes J., Miles C., Horner J., Needham T., et al.: Significance of popliteal reflux in relation to ambulatory venous pressure and ulceration. *Arch Surg* 1979;114:1304-6.

4. Anderson F.A., Wheeler H.B., Goldberg R.J., Hosmer D.W., Patwardhan N.A., Jovanovic B., et al. A population-based perspective of the hospital incidence and case-fatality rates of deep vein thrombosis and pulmonary embolism: the Worcester DVT study. *Arch Int Med* 1991;151:933-8.
5. Peterson K.L., Acute pulmonary thromboembolism: Has its evolution been redefined? *Circulation* 1999;99:1280-3.
6. Kearon C, Hirsh J. Management of anticoagulation before and after elective surgery. *N Engl J Med* 1997;336:1506-11.
7. Douketis JD, Kearon C, Bates S, Duku EK, Ginsberg JS. Risk of fatal pulmonary embolism in patients with treated venous thromboembolism. *JAMA* 1998;279:458-62.
8. O'Donnel T.F., Browse N.L., Burnand K.G., Lea Thomas M. The socioeconomic effects of an iliofemoral venous thrombosis. *J Surg Res* 1977;22:483-8.
9. Milne A.A., Ruckley C.V. The clinical course of patients following extensive deep vein thrombosis. *Eur J Vasc Surg* 1994;8:56-9.
10. Van Haarst E.P., Liasis N., Van Ramshorst, Moll F.L. The development of valvular incompetence after deep vein thrombosis: a 7 year follow up study with duplex scanning. *Eur J Vasc Endovasc Surg* 1996;12:295-9.
11. Johnson B.F., Manzo R.A., Bergelin R.O., Strandness D.E. Jr. Relationship between changes in the deep venous system and the development of the postthrombotic syndrome after an acute episode of lower limb vein thrombosis: a one-to-six-year follow-up. *J Vasc Surg* 1995;21:307-12.
12. Ziegler S., Schillinger M., Maca T.H., Minar E. Post-thrombotic syndrome after primary event of deep venous thrombosis 10 to 20 years ago. *Thromb Res* 2001;101:23-33.
13. Bergquist D., Jendteg S., Johansen L., Persson U., Odgaard K. Cost of long-term complications of deep vein thrombosis of the lower extremities: an analysis of a defined patient population in Sweden. *Ann Intern Med* 1997;126:454-7.
14. Juhan C., Alimi Y., Di Mauro P., Hartung O. Surgical venous thrombectomy. *Cardiovasc Surg* 1999;7:586-90.
15. Comerota A.J., Gale S.S. Technique of contemporary iliofemoral and infrainguinal venous thrombectomy. *J Vasc Surg* 2006;43:185-91. *Bullet HR, Agnelli G, Hull RD, Hyers TM, Prins MH, Raskob GE. Antithrombotic therapy for venous thromboembolic disease: the Seventh ACCP Conference on Antithrombotic and Thrombolytic Therapy. Chest* 2004; 126:401S-428S.
16. Hartung O., Alimi Y., Juhan C. Role of surgery and endovascular therapies in lower limb deep venous thrombosis. In: Labropoulos N, Stansby G, editors. *Venous and lymphatic diseases*. New York, Taylor & Francis; 2006, pp. 209-25.
17. Blättler W., Heller G., Lagardier J., Savolainen H., Gloor B., Schmidli J. Combined regional thrombolysis and surgical thrombectomy for treatment of iliofemoral vein thrombosis. *J Vasc Surg* 2004;40:620-5.
18. Juhan C.M., Alimi Y., Barthelemy P.J., Fabre D.F., Riviere C.S. Late results of iliofemoral venous thrombectomy. *J Vasc Surg* 1997;25:417-22.
19. Hartung O., Benmiloud F., Barthelemy P., Dubuc M., Boufi M., Alimi Y.. Late results of surgical venous thrombectomy with ilio caval stenting. *J Vasc Surg* 2008;47:381-7.
20. Mickley V., Schwagereck R., Schultz A., Sunder-Plassman L. Stent implantation after thrombectomy of pelvic veins. Indications, results. *Zentralb Chir* 1999;124:12-7.
21. Hutschenreiter S., Vollmar J., Loeprecht H., Abendschein A., Rodl W. Reconstructive operations on the venous system: late results with a critical assessment of the functional and vascular morphological criteria. *Chirurg* 1979;50:512-27.
22. Eklöf B., Neglen P. Venous thrombectomy. In: Raju S., Villavicencio JL, eds. *Baltimore, MD, USA: Williams & Wilkins* 1997;512-27.
23. Alimi Y., Juhan C. New trends in the surgical and endovascular reconstructions of large veins for non-malignant chronic venous occlusive disease. *Curr Op Card* 1998;13:375-83.
24. Plate G., Ohlin P., Eklöf B. Pulmonary embolism in acute iliofemoral venous thrombosis. *Br J Surg* 1985;72:912-15.
25. Törngren S., Hjertberg R., Rosfors S., Bremme K., Eriksson M., Swedenborg J. The long-term outcome of proximal vein thrombosis during pregnancy is not improved by the addition of surgical thrombectomy to anticoagulant treatment. *Eur J Vasc Endovasc Surg* 1996; 12, 31-36.
26. Mewissen M.W., Seabrook G.R., Meissner M.H., Cynamon J., Labropoulos N., Haughon SH. Catheter-directed thrombolysis for lower extremity deep venous thrombosis: report of a national multicenter registry. *Radiology* 1999; 211:39-49.
27. O'Sullivan GJ, Semba CP, Bittner CA, Kee ST, Razavi MK, See DY et al. Endovascular management of iliac vein compression (May-Thurner) syndrome. *J Vasc Interv Radiol* 2000; 11:823-36.
28. Bjarnasson H., Kruse J.R., Asinger D.A., Nazarian G.K., Dietz C.A. Jr, Caldwell M.D., et al. Iliofemoral deep venous thrombosis: safety and efficacy outcome during 5 years of catheter-directed thrombolytic therapy. *J Vasc Interv Radiol* 1997;8:405-18.
29. Comerota A.J., Kagan S.A. Catheter-directed thrombolysis for the treatment of acute iliofemoral deep venous thrombosis. *Phlebology* 2001;15:149-55.

Acute iliofemoral venous thrombosis:
why should clots be removed?

30. Vedantham S., Vesely T.M., Siacrd G.A., Brown D., Rubin B., Sanchez LA, et al. Pharmacomechanical thrombolysis and early stent placement for iliofemoral deep venous thrombosis. J Vasc Interv Radiol 2004;15:565-74.
31. Patel N.H., Stookey K.R., Ketcham D.B., Cragg A.H. Endovascular management of acute extensive iliofemoral deep venous thrombosis caused by May-Thurner syndrome. J Vasc Interv Radiol 2000;11:1297-302.
32. Abu-Rahma A.F., Perkins S.E., Wulu J.T., Nq H.K. Iliofemoral deep vein thrombosis: conventional therapy versus lysis and percutaneous transluminal angioplasty and stenting. Ann Surg 2001;233:752-60.
33. Kwak H.S., Han Y.M., Lee Y.S., Jin G.Y., Chung G.H. Stents in common iliac vein obstruction with acute ipsilateral deep venous thrombosis:early and late results. J Vasc Interv Radiol 2005;16:815-22.
34. Schwarzbach M.H., Schumaker H., Bockler D., Furstenberger S., Thomas F., Seelos R., et al. Surgical thrombectomy followed by intraoperative endovascular reconstruction for symptomatic iliofemoral venous thrombosis. Eur J Vasc Endovasc Surg 2005;29:58-66.
35. Hussmann M.J., Heller G., Kalka C., Savolainen H., Do D.D., Schmidli J., et al. Stenting of common iliac vein obstructions combined with regional thrombolysis and thrombectomy in acute deep vein thrombosis. Eur J Vasc Endovasc Surg 2007;34:87-91.

Note de la Rédaction

« La prise en charge d'un patient présentant un syndrome post-thrombotique : le point de vue du chirurgien »

Le 18 Octobre 2008 s'est tenue à Aix en Provence
la 2^{ème} réunion de la **Société Française de Phlébologie Région Sud-Est**
organisée avec le soutien des **ARMV Rhône-Alpes et PACA**
Nous publions dans ce numéro les communications
du **Pr Y. Alimi** et du **Dr O. Hartung** qui ont développé avec le **Dr P. Nicolini**
le point de vue du chirurgien dans cette pathologie.

Nous publierons dans le prochain numéro de **PHLEBOLOGIE**
les communications qui en ont développé les divers aspects médicaux.

Jean-Luc Gillet, Responsable Scientifique
de la **Société Française de Phlébologie Région Sud-Est**