

Le livre évènement de l'année en Phlébologie : « **ULTRASONS ET PHLEBOLOGIE** » sera disponible en **version FRANCAISE**, sur le congrès SFP de décembre 2016 à Paris et par Internet courrier@sf-phlebologie.org

Pour les non francophones dans ce numéro, la **Revue Phlébologie Annales Vasculaires**, publie en avant-première, la version ANGLAISE « **Use of duplex ultrasound during the procedure: foam sclerotherapy** », du chapitre écrit par **Claudine Hamel-Desnos**.

The publication of the year book on Phlebology: "ULTRASOUND AND PHLEBOLOGY", will be available in French during the SFP Congress in December 2016 in Paris and by Internet at courrier@sf-phlebologie.org

For non-French speaking readers, "Phlebology Vascular Annals" publishes a preview of the ENGLISH version of the chapter devoted to the "Use of duplex ultrasound during the foam sclerotherapy procedure", written by Claudine Hamel-Desnos.

Use of duplex ultrasound during the procedure: foam sclerotherapy

Claudine Hamel-Desnos

Summary

Duplex ultrasound in relation to foam sclerotherapy treatment (Ultrasound Guided Foam Sclerotherapy) is essential in the management of varicose veins, but probably not used enough for small-calibre veins, such as the reticular veins.

During the pre-treatment investigation of the venous disease to formulate the treatment plan and injection sites, Duplex ultrasound is used in all the modes (B, pulsed, colour).

During the procedure, once the injection site has been located, only the B mode is used.

The same applies to immediately post-procedure.

In this chapter we describe the various indications for UGFS, the plans and techniques to be used. We shall focus mainly on the per-procedural phase, based on the direct needle puncture-injection technique with fractionated injections, and on the use of the ultrasound tool during this phase.

Introduction

Ultrasound Guided Foam Sclerotherapy (UGFS) comprises of injecting a sclerosing agent in the form of foam into a target vein, with ultrasound assistance and control.

This development occurred in two stages.

Ultrasound guidance in sclerotherapy was first introduced in the mid-eighties [1, 2], but the actual use of foam in phlebology practice was only introduced ten years later [3, 4].

This combination of foam and ultrasound guidance constituted a turning point in the history of phlebology.

The purpose of using UGFS is to reinforce the relevance, precision, effectiveness and safety of sclerotherapy.

UGFS is used in the treatment of numerous types of varicose veins; it is frequently practised in France, such that the number of procedures greatly exceeds the number of surgical and endothermal ablation procedures.

Nevertheless the method requires a certain number of prerequisites and specific training.

Thus, it is important to be aware of venous disease, be well-practised in the venous duplex ultrasound (DUS) examination and visual sclerotherapy, and to know how to map and plan for the treatment of varicose veins.

These are the essential prerequisites that are required before UGFS training can begin.

Specific training in the technique of making and using the sclerosing foam is required by the French National Agency for Medicines and Health Products Safety (*Agence Nationale de Sécurité du Médicament; ANSM*), in its Summary of Product Characteristics (SmPC) for the sclerosing agents Aetoxisclérol® and Fibrovein® [5].

Furthermore, in 2004, in its report on the treatment of varicose veins, the French health authorities (*Agence Nationale d'Accréditation et d'Évaluation en Santé ANAES*) specified: "Sclerotherapy requires appropriate training; it must not be performed on an occasional basis but requires regular practice over time" [6].

Indications

Indications for ultrasound guidance

In its report on treating varicose veins, published by the French health authorities in 2004 [6], ultrasound guidance was recommended, for safety reasons, in sclerotherapy to treat the following:

- Saphenous trunks;
- Perforating veins;
- Recurrent conditions;
- Any varicose vein not visible situated in an area that is at risk, in particular the popliteal fossa and the inguinal region.

Use of duplex ultrasound during the procedure: foam sclerotherapy

Claudine Hamel-Desnos

Even today, these recommendations remain valid. However, with UGFS now being in wide scale use, the combination of the syringe and the ultrasound probe has become a more natural process and routine practice for the practitioner, so that the indications for ultrasound guidance have been greatly expanded.

Hence the European recommendations to now advise using ultrasound guidance wherever it is technically possible, without restricting the indications [7].

In fact, the safety ought to be optimised in a maximum of situations.

**Use of assistance and ultrasound guidance wherever technically feasible.
Use of assistance and ultrasound guidance wherever the target varicose vein is not visible or at least palpable.**

Indications for the foam

In some international guidelines, foam sclerotherapy (FS) has become one of the recommended techniques for treating saphenous veins, even taking priority over conventional surgery ("crossectomy and stripping") [8, 9]. In fact FS is the most versatile technique of all the methods for treating varicose veins; it is therefore far from being limited to the saphenous veins, since they only represent a moderate percentage of all the indications in daily practice.

In fact, it can be used for treating all types of varicose veins. [7]

Furthermore, in comparison to the liquid form, the foam form is preferable for almost all indications, with various grades of recommendations, but highly recommended for saphenous veins [7].

Excluding specific contraindications for the foam form, the only indication for which the liquid form could still maintain a place is for reticular veins and telangiectasia, yet even here, foam "is gaining ground" in common practice, although foam of the lower sclerosant concentrations is an off licensed use.

**Foam can be recommended for more indications than liquid, except for reticular veins and telangiectasia.
Unless there is a contraindication, the foam form, rather than the liquid form, should be used regularly for treating saphenous veins.**

Indications for UGFS

In contrast to a liquid sclerosing agent, foam is very echoic.

Consequently, whenever ultrasound guidance is used, foam is preferable to liquid. In fact, the distribution of foam in the target vein is clearly visible in B ultrasound mode; the filling of the vein with foam is an important judgment criterion of the immediate impact of the injection.

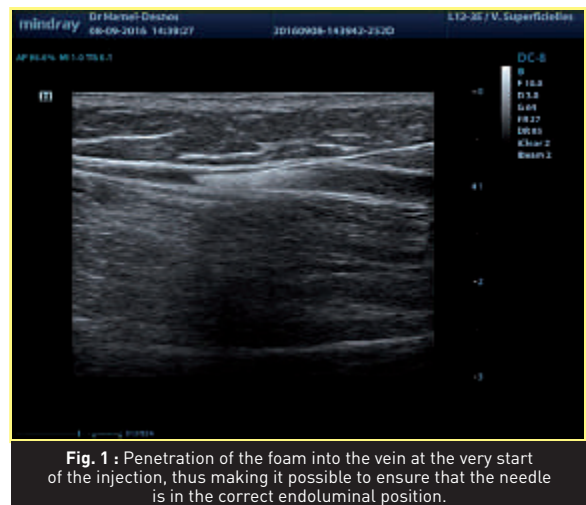

Fig. 1 : Penetration of the foam into the vein at the very start of the injection, thus making it possible to ensure that the needle is in the correct endoluminal position.

The echogenicity of foam makes it possible to improve not only the efficacy of sclerotherapy but also the safety of the procedure.

Consequently penetration of the foam into the vein is perfectly visible from the start of the injection and makes it possible to ensure the correct endoluminal positioning of the needle. **(Figure 1)**

Similarly, the slightest extravasation of foam is visible immediately, enabling the instantaneous stoppage of pressure on the plunger of the syringe. **(Fig. 11)**.

Technically, there is no real upper limit with respect to the feasibility of the UGFS procedure. Some studies tend to show, however, that although it can be performed and could be efficacious in the short term, UGFS of large-diameter veins could result in more failures of recanalisation [10, 11, 12, 13, 14].

Some authors consider that the upper limit for efficacy of foam could be 6 mm in diameter [10, 11, 13].

Historically, the use of UGFS was reserved for varicose veins of at least 3-4 mm in diameter and at rather some distance from the skin.

Currently, thanks to the improved quality of ultrasound images, the use of high-frequency and even very high-frequency probes (18-22 MHz), and the improvement in practice, the lower limits have been increasingly pushed further back.

In fact, it is now technically possible to use UGFS to treat veins of 1 mm in diameter; even those positioned immediately beneath the skin, at a depth of 1 or 2 mm.

These are not technical feats of ingenuity, but are a matter of refining even further skill in performing sclerotherapy and its effectiveness, even on small-calibre veins, including reticular veins and telangiectasia.

Use of duplex ultrasound during the procedure: foam sclerotherapy

Guiding the needle, viewing the penetration of the foam, its endoluminal distribution and impact on the vein is no less important for a reticular vein than for a saphenous vein.

Once there is an indication of sclerotherapy treatment, ultrasound guidance and foam should be combined whenever possible.

Injection Planning – Approaches

Currently, the most frequently used and most highly recommended tactic consists in first injecting the most important reflux positioned at the highest point, and in the order of treatment of the varicosities from largest to smallest [7].

This method is the recommendation of the *French school according to Tournay* and is known as “*top to bottom*”.

Other methods of injection planning were described in the past and have their supporters:

The Sigg Method: treating the most distal varicosities first

The Fegan method: priority injection of perforators.

These have now been abandoned.

As has also been found in the thermal ablation of the saphenous trunks, one of the major observations in the top-to-bottom technique is that by closing the largest reflux points that are also situated at the highest point, in many cases the underlying varicose veins in the area will subside, close and disappear spontaneously; post-procedural inflammatory reactions are also reduced and the need to perform additional sclerotherapy treatments diminishes.

Compared to the Sigg and Fegan techniques, this results in a far less aggressive treatment, as well as greater comfort for the patient, as witnessed by the absence of the need for compression after treatment in the top-to-bottom method, something was considered to be indispensable for the two other schools of thought.

Watkins showed that the sclerosing agent very soon degraded when it came into contact with blood [15].

For this reason, it is desirable not to inject a large bolus of foam from a single site as is sometimes the practice.

Staged injections, divided into fractions are preferable, using, except in special cases, small-volume syringes (2.5 or 3ml), so as to be able spread “fresh” foam at different sites in the targeted varicose territory.

Injections divided in this way are the subject of a recommendation by the ANSM [5].

The choice of site for the first injection is therefore important.

If we take the simple example of UGFS of the trunk of the great saphenous vein (GSV), the first injection site is not always located in the same place in all cases:

- If the reflux is axial, i.e. it occupies the GSV along its whole course, the ideal site for the first injection is close to the junction of the middle third and upper third of the thigh (Figure 2).
- If the truncular reflux is fed by ganglion or pudendal varicose veins, as in the case particularly of recurrences, the first injection site chosen is often close to the root of the thigh (Figure 3).
- If the reflux is segmented only occupying part of the trunk, the first site will be located in the upper portion of the reflux (Figure 4).

The top-to-bottom approach, with staged injections, is the reference technique. It consists in first treating the most significant refluxes and those at the highest point, as well as in the order of the largest to the smallest varicose veins.

Injection Techniques

In France, whether for visual sclerotherapy (sclerotherapy by sight) or for UGFS, the direct puncture-injection technique using a needle is by far the most widespread.

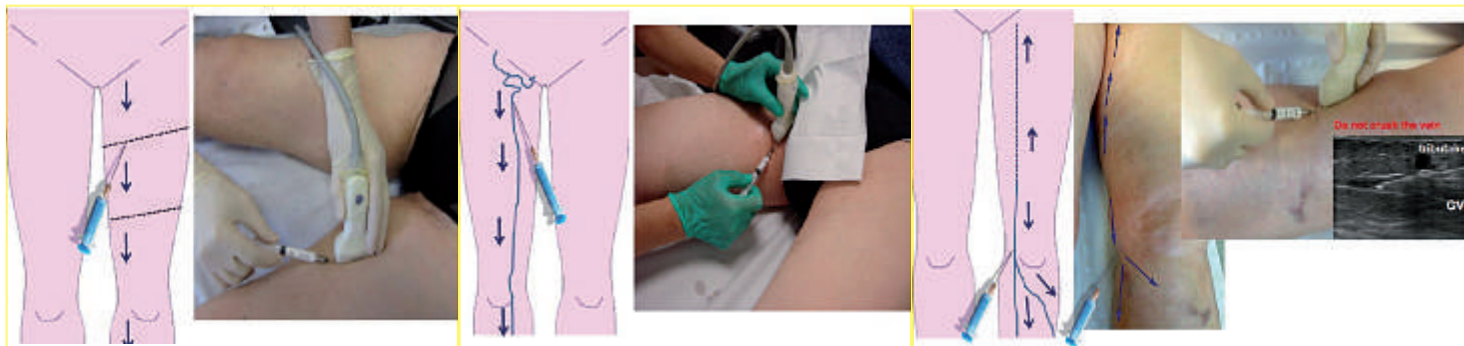


Fig. 2 : GSV axial reflux; the first injection site is at the junction of the middle third and upper third of the thigh.
GSV: great saphenous vein

Fig. 3 : GSV reflux fed by ganglion or pudendal varicose veins; the first injection site is closer to the root of the thigh.

Fig. 4 : GSV segmented truncular reflux; the first injection site has been adjusted according to the upper limit of the reflux.

Use of duplex ultrasound during the procedure: foam sclerotherapy

Claudine Hamel-Desnos

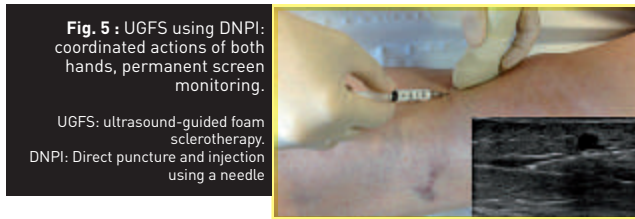


Fig. 5 : UGFS using DNPI: coordinated actions of both hands, permanent screen monitoring.

UGFS: ultrasound-guided foam sclerotherapy.
 DNPI: Direct puncture and injection using a needle

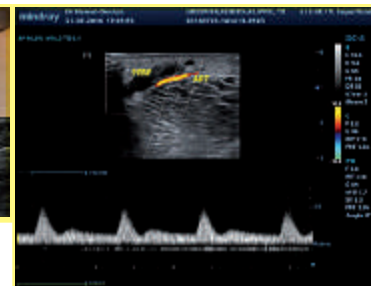

Fig. 6 : Locating by duplex ultrasound prior to the injection: presence of a neighbouring arteriole close to the performing vein (colour and pulsed mode). This site must be avoided.

Other sclerotherapy techniques are sometimes used, such as the butterfly needles, a short catheter or long catheter; they are not often performed in France where the “culture” and practice of direct needle puncture-injection (DNPI) has existed for as long as sclerotherapy.

Direct needle puncture-injection (DNPI)

In DNPI, the needle is directly attached to the syringe that is filled with the sclerosing agent, thus making it possible to inject the foam directly into the vein, without the need for an intermediate device; this is the basic sclerotherapy technique that has been used for a century and that remains the most widespread.

In the classic description of UGFS using DNPI, the operator acts alone, without an operating aid or assistant. The operator’s dominant hand holds and manipulates the syringe independently but in coordination with the other hand, the latter holding the ultrasound probe. (Figure 5)

Description of the technique

The first descriptions of the ultrasound-guided sclerotherapy technique using a liquid sclerosing agent were produced by Schadeck and Vin [1, 2] in the 1980s. Subsequent the method was discussed in greater detail, using sclerosing foam [16, 17, 18, 19].

Officially, the French health authorities published good practice instructions [5, 6], and the European recommendations for performing the UGFS technique were published in 2013, with grade 1C [7].

Ultrasound-guided sclerotherapy procedure using DNPI – Rules for good practice and recommendations:

The entire ultrasound-guided sclerotherapy procedure as a whole is performed under ultrasound control.

Traditionally, four stages are described:

- Locating the site before injection.
- Puncture.
- Injection.
- Post-injection check.

The stages are listed below.

N.B. For adjusting the ultrasound image, avoid “zooming in” too close to the vein, opt for a slightly wider field so as to be able to follow the needle’s progress as it passes through the tissues and to be able to alter its direction if necessary.

Before the injection:

Locating by the duplex ultrasound (modes B, pulsed, colour; longitudinal section and cross-section).

- Locating the target segment of vein;
- Choice of a suitable and safe injection site;
- Check for the absence of arteries and neighbouring arterioles (colour mode) (Figure 6);
- should there be a reflux of the axial saphenous vein (affecting the saphenous vein throughout its length), the first injection site should be chosen in the proximal region:
 - of the thigh, for the great saphenous vein (GSV) or an anterior accessory saphenous vein (AASV);
 - of the calf for the small saphenous vein (SSV);
- in all other cases, choose the most strategic puncture site that is relevant, safest and easily accessible.

Marking of the chosen puncture site, if necessary.

Skin asepsis.

Preparation of the equipment

- Cover the probe (with a dedicated probe protector bearing CE marking).
- Extemporaneous foam production.
- Attach the needle to the foam-filled syringe and unlock the cap but leave it on the needle.

Puncture (only in mode B)

- The ultrasound probe must be held flexibly and lightly without squeezing it. It is positioned on the skin, at the site previously chosen with respect to the vein, without crushing it; during the first approach, the cross-section is used and at this stage, either hand may be used. Subsequently, when the probe is correctly positioned, if the longitudinal section is preferred to making the puncture, the probe should be pivoted without losing the image. The image can be adjusted for quality of image of the venous lumen, which should appear to be well separated, with the fewest artefacts possible (Figures 7 and 8). The ultrasound image must then be maintained; from this stage, it is always the non-dominant hand that should hold the probe, and it must move as little as possible during the puncture-injection.
- The dominant hand holds the syringe and, at a distance of about 0.5 to 1 cm from the probe, it punctures the skin, passing through it and thence into the vein; the angle of attack will vary depending on the depth of the tissues to penetrate but it is generally about 45° in relation to the plane of the skin.
- Position the tip of the needle as correctly as possible in the centre of the lumen in the vein. (Figure 9).

Use of duplex ultrasound during the procedure: foam sclerotherapy

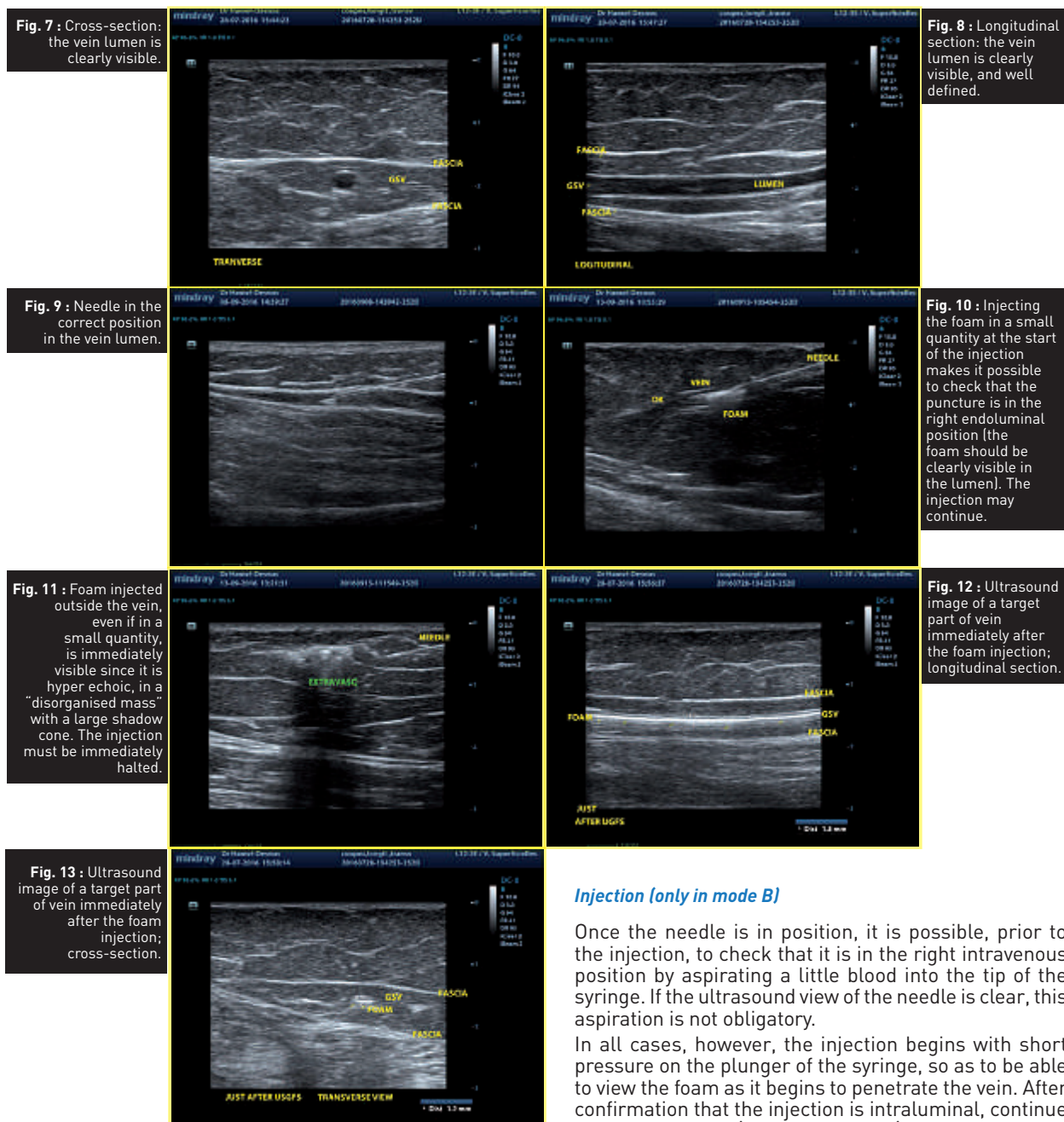


Fig. 7 : Cross-section: the vein lumen is clearly visible.

Fig. 8 : Longitudinal section: the vein lumen is clearly visible, and well defined.

Fig. 9 : Needle in the correct position in the vein lumen.

Fig. 10 : Injecting the foam in a small quantity at the start of the injection makes it possible to check that the puncture is in the right endoluminal position (the foam should be clearly visible in the lumen). The injection may continue.

Fig. 11 : Foam injected outside the vein, even if in a small quantity, is immediately visible since it is hyper echoic, in a "disorganised mass" with a large shadow cone. The injection must be immediately halted.

Fig. 12 : Ultrasound image of a target part of vein immediately after the foam injection; longitudinal section.

Fig. 13 : Ultrasound image of a target part of vein immediately after the foam injection; cross-section.

Injection (only in mode B)

Once the needle is in position, it is possible, prior to the injection, to check that it is in the right intravenous position by aspirating a little blood into the tip of the syringe. If the ultrasound view of the needle is clear, this aspiration is not obligatory.

In all cases, however, the injection begins with short pressure on the plunger of the syringe, so as to be able to view the foam as it begins to penetrate the vein. After confirmation that the injection is intraluminal, continue with the injection. **(Figures 9 and 10).**

The whole injection is constantly in view on the ultrasound screen.

The injection only lasts a short time, generally no longer than about 10 to 15 seconds for a 2.5 mL syringe.

Fig. 7 and 8 Locating the saphenous vein image prior to puncture by means of cross-sections and longitudinal sections; the lumen should be well-defined and contain as few artefacts as possible in the target area.

Use of duplex ultrasound during the procedure: foam sclerotherapy

Claudine Hamel-Desnos

N.B.: once the foam has been made, it must be injected within the next 60 seconds at most otherwise it will begin to reform into a liquid [5].

Immediate post-injection check (only in mode B)

Once the injection has been completed, a "scan" is performed in mode B, especially in cross-section. An assessment is made of the distribution of the foam. If the procedure has had an instantly favourable impact this can be seen via:

- The occurrence of a spasm in the target part of the vein;
- Uniform filling of the target part of the vein with a dense and compact foam.

Ideally, the ultrasound image of the vein in spasm and well "impacted" by the foam, will be a simple hyper echoic line, measuring no more than 1 to 2 mm in diameter (**Figures 12 and 13**), even if at the start the vein had a significant calibre.

This post-injection ultrasound check also makes it possible to judge whether it will be necessary to perform an additional injection during the same session for a particular area. In fact, based on the principle of fractionated injections in stages, the filling of the vein with foam is performed on demand, based on the reaction of each target section of vein (tailored injections).

Other techniques

Alternative techniques to DNPI injection are the use of short or long catheters, or butterfly needles.

Short catheters and butterfly needles

For a GSV, the device is usually introduced into the trunk, under ultrasound monitoring, in the knee area.

A butterfly needle is sometimes introduced visibly into a tributary of the GSV in the knee or leg region rather than into the trunk, since this fairly non-superficial area may be difficult to reach with this needle.

Once in place, the device is secured by being fixed to the skin by means of a sticking-plaster.

The foam is then made and injected via this single site, by connecting a syringe, or even a succession of syringes, filled with foam.

The progression of the foam through the saphenous vein is monitored via ultrasound (mode B).

The operator usually stops the injection as soon as the foam reaches the sapheno-femoral junction (SFJ), then withdraws the device.

Some operators insert several devices at the outset, in stages along the trunk of the GSV (including in the thigh), and sometimes also in the largest tributaries.

Subsequently, once all the devices have been attached to the skin, the leg is elevated and the foam is injected via the various puncture sites [20].

The aim of this method of proceeding is to distribute the foam more evenly in the various parts of vein, by dividing the injections into fractions and injecting "fresh" foam at each site.

This method referred to British technique would make the procedure closer to the DNPI using a similar approach of top-to-bottom injection.

Long catheters

After administering local anaesthetic, the long catheter (generally a 5 French) is usually introduced by means of an introducer, in the knee region for a GSV. It is then brought up under the SFJ, with the tip positioned through ultrasound control (mode B). Once the catheter is in position, one or more foam-filled syringes are injected into the trunk via this catheter, which is gradually redescended until it emerges completely from the vein [16].

Advantages and disadvantages of the different techniques

The advantages offered for the use of catheters or butterfly needles include:

- the operator benefits from time and comfort in which to prepare and inject the foam;
- it is possible to use several syringes in succession at the same site if needed;
- during treatment of the GSV, it is possible to elevate the lower limb to empty the vein of blood before the injection (for better contact between the foam and the wall of the vein) and to prevent the foam moving into the sapheno-femoral junction;
- it is possible to perform a tumescent infiltration of the perivenous tissues in order to obtain a reduction in the calibre of the vein and better contact between the foam and the venous endothelium.

No study, however, has confirmed the point of elevating the leg.

The European guidelines even specify that they do not recommend either elevation of the leg nor manual compression of the SFJ for safety reasons [7].

Furthermore, conducted randomised controlled trial by Devereux and Khale, that compared the results of catheter foam sclerotherapy applied to the GSV with or without peri-venous tumescence, did not demonstrate any superiority of the "arm with tumescence" [21].

The disadvantages of using catheters and butterfly needles include:

- the devices are too restrictive. In comparison to DNPI, they are less accurately manipulated and not suited for complex networks and veins of difficult

Use of duplex ultrasound during the procedure: foam sclerotherapy

accessibility, such as inguinal recurrences in particular. Catheters and butterfly needles may be sufficient for the primary saphenous trunks, since these are generally easy to access and, in fact, technically among the easiest veins to treat by sclerotherapy. On the other hand, the primary saphenous veins only represent a small part of the sclerotherapy indications in our regular consultations, during which DNPI and UGFS by DNPI have proved to be the most suitable and swift techniques in most cases;

- the techniques take slightly longer to perform than DNPI, even if the butterfly needles can be inserted relatively quickly, into the tributary veins for example;
- there is a risk that the foam will deteriorate in the extender tubes, if they are used, or in the catheter itself in the case of a long catheter;
- in the case of the single short catheter or butterfly needle:
 - there is a risk of failing to occlude the proximal portion of the GSV in the thigh. In fact, if the foam is injected into the knee region, when it reaches the proximal section of the thigh, will have seriously deteriorated, both due to the distance it has had to travel and due to its being adversely affected by the blood;
 - there is a risk of post-procedural inflammatory reaction that is potentially higher. In fact, the foam is of maximum "strength" at the point of injection (in the knee which is a "sensitive" site, not heavily protected by tissue) and in the vicinity (varicose tributaries in the leg). If a bolus of foam is injected into the knee region, there is every possibility, due to local overdose, of causing inflammatory reactions.

Ultrasound sections and images

The ultrasound sections most frequently used in phlebology are:

- Longitudinal section: the probe is moved along the vein (in the axis of the vein); the vein can be displayed across the width of the screen, in the form of a tube; (Figure 8)
- Cross-section: the probe is at right angles to the vein (perpendicular to the vein axis), so that the image is circular. (Figure 7).

In both cases, the lumen of the vein and its liquid content are anechoic, while the wall is echoic, having an image that is denser and lighter, as are the fascias and aponeuroses.

During UGFS by DNPI, the needle is visible since it is hyperechoic. If it is to be effectively displayed in longitudinal section it needs to be correctly positioned under the ultrasound (US) beam, and in cross-section, it must encounter the beam.

Longitudinal section

It is in this section that the needle is at its most visible, since it is introduced at the outset into the US field; it then appears in the form of a solid line, sometimes with repetition echoes, depending on the angle formed with the beam. (Figure 14).

The needle is generally introduced about 0.5 or 1 cm behind the probe, at an angle of 30° to 45° to the plane of the skin, but this angle may vary depending on the thickness of the tissue through which it has to penetrate. (Figure 15).

For UGFS by DNPI of very superficial veins (sub-cutaneous veins and reticular veins, for example) the procedure differs very little, but the needle is introduced much more tangentially. (Figure 16).

It is nevertheless not enough to place the needle under the probe for it to be under the ultrasound beam. In fact, the thickness of the probe is often at least 1 cm, and that of the beam about 1 mm (Figures 17 and 18).

Furthermore, a slight deviation of the direction of the needle during the puncture will produce a significant distancing of the needle from the beam (Figures 19 and 20). If the needle cannot be seen on the screen, it will be necessary to check the direction of the syringe-needle axis in relation to that of the probe so as to be able to re-position the needle.

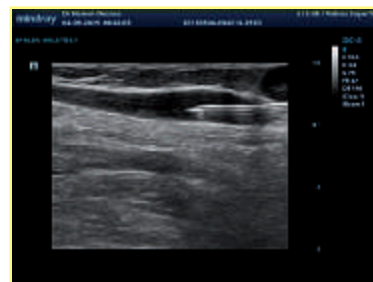

Fig. 14 : Hyperechoic image of the needle; echoes of "repetition".

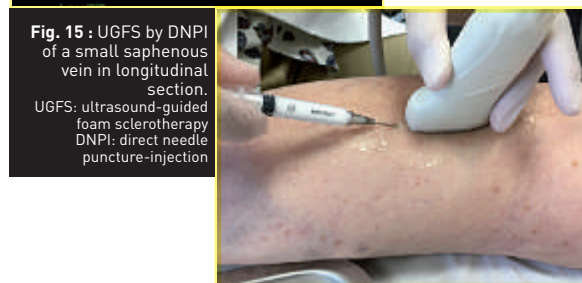


Fig. 15 : UGFS by DNPI of a small saphenous vein in longitudinal section. UGFS: ultrasound-guided foam sclerotherapy DNPI: direct needle puncture-injection

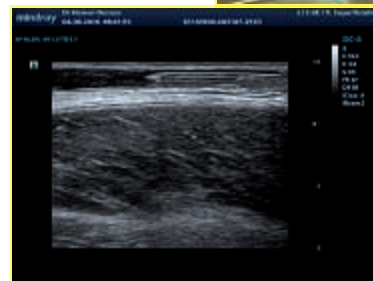

Fig. 16 : Needle introduced very tangentially in a very superficial vein; note the "repetition" echoes.

Use of duplex ultrasound during the procedure: foam sclerotherapy

Claudine Hamel-Desnos



Fig. 17 : Ultrasound beam shown as a red line and needle beneath the beam.

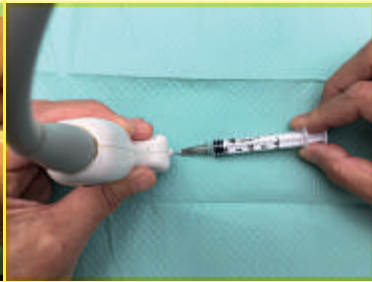

Fig. 18 : Needle under the beam, in the right direction, along the axis of the probe (the needle will be visible on the screen).

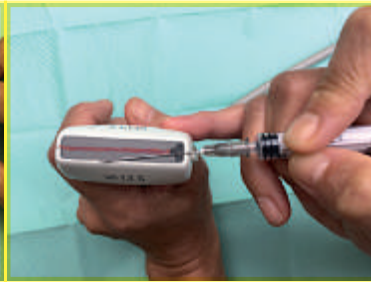

Fig. 19 : Deviation in the direction of the needle (the needle will not be visible on the screen).

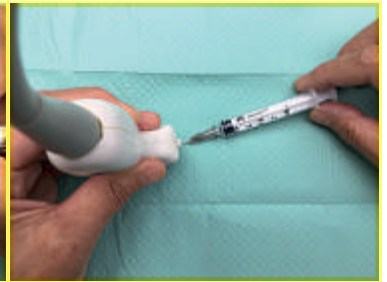

Fig. 20 : Deviation in the direction of the needle; the needle is not visible on the screen, it will be necessary to reposition the needle.

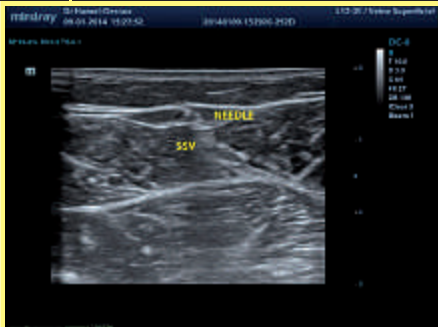

Fig. 21 : Image of the needle in cross-section is in the shape of a dot.

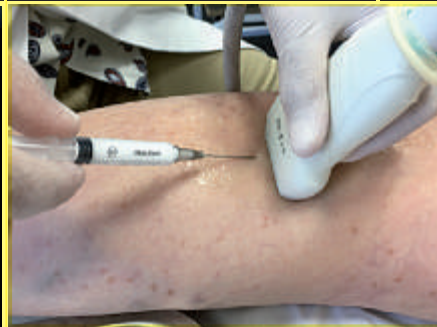

Fig. 22 : UGFS by DNPI of the small saphenous vein in cross-section. UGFS: ultrasound-guided foam sclerotherapy DNPI: direct needle puncture-injection

Sometimes, images of the vein and the needle may be contiguous, and the 2D image may give the false impression that the needle is inside the vein (parallax error).

Cross-section

In cross-section, the needle passes outside the US field before encountering the US beam; the image is in the shape of a dot (**Figure 21**).

It is introduced with an angulation of about 45° in relation to the plane of the skin; the puncture must not be performed too close to the probe. (**Figure 22**).

In this cross-section, the beam being positioned crosswise, the needle will encounter it more easily than in longitudinal section.

Since the image of the needle is merely a dot, if it penetrates through the rear wall of the vein, the tip of the needle will be in an extravascular position, and the image of the shaft of the needle may be mistaken for the tip of the needle, causing the operator to believe that the position is correct.

The advantages and disadvantages of each section are summarised in Table 1.

While both techniques that have just been described, namely: "longitudinal section and puncture" and "cross section and puncture" are the most frequently used, other cases are possible (**see annex**).

Furthermore, it should be noted that in the case of sinuous veins, it is sometimes difficult to obtain a satisfactory longitudinal section, and even when positioning the probe along the vein, the latter may appear as in a cross-section. In such a case, the puncture should nevertheless be performed in the longitudinal direction (in the direction of the probe).

Doses

Schematically, it should be considered that the choice of concentrations depends on the diameter of the veins and the volumes based on the quality of filling and the venous spasm.

Concentrations

In the case of the concentrations of sclerosants to be used in sclerotherapy, guidance has been published [7, 17, 18, 19].

Use of duplex ultrasound during the procedure: foam sclerotherapy

Table 1: Advantages and disadvantages of longitudinal sections and cross-sections.

	LONGITUDINAL SECTION	CROSS-SECTION
Advantages	Better visibility of: - vein and venous lumen - front and rear walls - needle during puncture (before injection) - distribution of the foam during the injection - extent of the spasm during the injection	- all of the walls are visible - the US beam is easy to reach - no parallax error
Disadvantages	- side-walls not visible - more difficult to "lead" the needle in the US beam - possibility of parallax error	less good visibility for: - vein and venous lumen - needle - distribution of the foam during the injection - extent of the spasm during the injection risk of passing through the rear wall

More specifically, in the case of UGFS, it is possible to provide, as an indication, the following concentrations:

Table 2: Suggested concentrations based on the diameters of the veins, for polidocanol and sodium tetradecyl sulfate, used in the form of foam in UGFS.

Diameter of the vein (mm)*	Polidocanol** %	Sodium Tetradecyl Sulfate** %
≤ 2	0.12 to 0.25	0.1
2 - 3	0.25	0.2
3 - 4	0.5	0.2 to 0.5
4 - 5	1	0.5 to 1
6 - 7	2	1
8 and over	3	3

* Measurements when examining the patient standing in cross-section in the targeted section.

**Concentrations of the sclerosing product used with air to make a foam [proportions= 1 volume of sclerosing agent + 4 volumes of air, with a bi-connector].

The literature provides randomised clinical studies that make comparisons of concentrations for the treatment of saphenous trunks using foam [22, 23, 24], as well as an ex-vivo study [25]. On the other hand, there is far less data concerning concentrations for treatment using sclerosing foam of small and very small calibre veins, for which the proposed values are thus essentially empiric. In France, polidocanol has received marketing authorisation for use as foam only for concentrations of 2 and 3%, and sodium tetradecyl sulfate for concentrations of 1 and 3%.

Volumes

Remember that in current practice, the maximum volume of foam injected per session must not exceed

10 ml according to European recommendations [7], while the ANSM (French regulation) permits up to 16 ml [5]. In both cases, it is recommended to divide the injections up into smaller volumes.

Dividing the injections and performing them in stages makes it possible to optimise the efficacy while minimising the procedure's side effects, the adjustment of the volumes being based on the quality of the spasm and filling of the vein, judged after each injection (**Figures 12 and 13**).

If, after injection, the spasm and the filling are not satisfactory, the following injection must be performed on an empty target section of vein or one that has very little foam filling. (**Figure 23**).

By using this method, an average of 4 to 5 ml of foam is generally enough to treat a GSV and 3 ml for an SSV of average calibre (up to 6 mm in diameter).

The choice of concentrations depends on the diameter of the target section of vein.
The total volumes injected depend on the quality of the spasm and filling of the target vein, but in current practice, 10 ml in one session should not be exceeded.

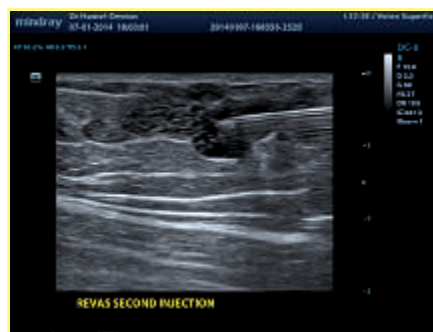

Fig. 23 : Ultrasound image of the target section of vein (post-surgical inguinal recurrence) after an initial injection of foam, demonstrating inadequate spasm and filling. A second injection will be needed (the needle has been introduced yet).

Use of duplex ultrasound during the procedure: foam sclerotherapy

Claudine Hamel-Desnos

The values (concentrations and volumes) provided in this chapter are an indication only. If the vein reacts poorly to the injections, it is preferable, as far as possible, to increase the concentration of the sclerosing agent rather than the volumes.

Equipment (Figure 24)

Duplex ultrasound Machine

The quality of the 2D imaging of the ultrasound machines has improved considerably in recent years and the frequency of the probes available is rising.

In current practice, an duplex ultrasound with a high-frequency linear probe (7.5 to 13 MHz) is adequate, but the very high-frequency probes, that have now become available on the market (16 to 22 MHz), have the advantage of improving comfort and performance by the practitioner, especially for very superficial veins.

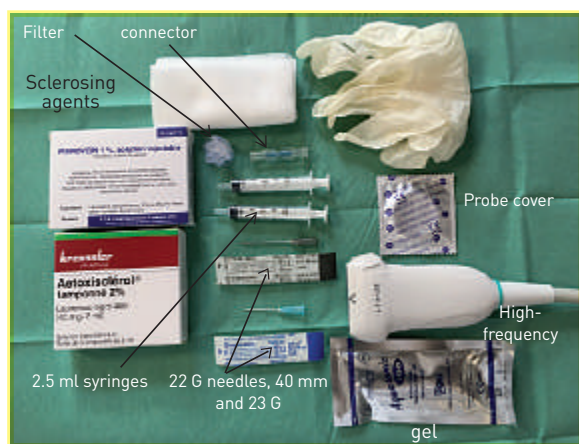


Fig. 24 : Equipment for performing UGFS by DNPI.
 UGFS: ultrasound-guided foam sclerotherapy
 DNPI: direct needle puncture-injection

Sclerotherapy equipment

The UGFS by DNPI procedure requires the use of the following equipment:

- Probe cover dedicated for ultrasound use, with CE marking;
- Sterile, disposable, 2.5 or 3 ml low-silicone syringes (PIC® Ansana, Italy);
- 22 Gauge needle, 0.7 mm in diameter, 40 mm in length (or 23 Gauge) (Laboratoires Terumo-France);
- Sclerosing agent: polidocanol (Laboratoire Kreussler Pharma France) or sodium tetradecyl sulfate (STD Pharmaceutical United Kingdom);
- Sterile equipment for making the foam: female-female sterile two-way connector + air filter kit (Laboratoire Kreussler Pharma, France), or other dedicated kit (such as EasyFoam® laboratoire Kreussler France, Sterivein® France).

Reminder of recommendations for making the foam

Table 3 summarises the various recommendations currently governing the making of the foam, based on European recommendations and French regulation (ANSM) [5, 7, 19].

The European and ANSM recommendations suggest a mixture of 1 volume of sclerosing agent to 4 volumes of air (5 volumes is acceptable).
 The French regulation (ANSM) requires the use of filtered or sterilised air.

Dilutions of the sclerosing agents

It is desirable, as far as possible, to avoid diluting the sclerosing agents. The recommendation is to use the proprietary concentrations available without altering them.

Certain proprietary concentrations are not available, however, and there is guidance for obtaining the desired concentrations and optimising the accuracy of the desired concentration.

It is therefore preferable to perform dilutions using volumes that are sufficient to reduce the margin of error and, if possible, to mix the sclerosing agents of two concentrations that are commercially available [26]. For example, in order to obtain a 1% concentration of polidocanol, insert 1 ml of 2% polidocanol and 1 ml of 0.25% polidocanol in a 2.5 ml syringe. Mix them and transfer the desired quantity (usually 0.5ml) to another syringe, using the two-way connector.

To obtain a polidocanol concentration of 0.12%, or a sodium tetradecyl sulfate concentration of 0.1%, however, it will be necessary to use a saline solution. Proceed in the same way as above, mixing 1 ml of saline with 1 ml of 0.25% polidocanol, or 1 ml of 0.2% sodium tetradecyl sulfate.

Special features depending on the indication or the context

An obese subject and veins "far from the skin"

Use a "lower" frequency (7.5 MHz) or increase the depth of field.

Use a longer needle (21 Gauge, 50 mm in length).

Insert the needle at a wider angle between the needle and the plane of the skin (80°, for example).

Use of duplex ultrasound during the procedure: foam sclerotherapy

Table 3 : European recommendations and French regulation (ANSM) for manufacturing the foam.

Producing the FOAM	European recommendations	ANSM (French regulation)
Method	Tessari (three-way stopcock) or equivalent (two-way connector) (grade 1 A)	Tessari or equivalent (two-way connector) or dedicated devices
Gas	Room air (grade 1 A) Mixture of CO2+O2 (grade 2 B)	Sterilised or filtered air (0.2µ)
Sclerosing agents	Polidocanol and sodium tetradecyl sulfate	Aetoxisclerol® and Fibrovein®
Concentrations	no restriction	Aetoxisclerol® 2 and 3% Fibrovein® 1 and 3%
Sclerosing agent + gas	1+4 or 1+5 (grade 1 A)	1+4; EsayFoam kit (1+4.6) acceptable
Minimum needle diameter	At least 25 Gauge for large varicose veins (grade 1 C)	At least 25 Gauge
Time between preparation of the foam and completion of the injection	As short as possible (grade 1 C)	Less than 60 seconds

Thin subject, very superficial, subcutaneous, reticular veins

Use a high-frequency/very high-frequency probe (13 to 22 MHz), or reduce the depth of field.

Insert the needle very tangentially (**Figures 16 and 25**); take care as the reticular veins are fragile so the puncture should not be traumatic and the plunger of the syringe should be pressed down flexibly.

A 23 Gauge needle, 30 mm in length can be used.

Vulvo-perineal varices

These varicosities are often difficult to access in combining use of the syringe with the probe. They are characteristically thin-walled and fragile, since the vein walls have little smooth muscle fibre. They are therefore difficult to puncture under ultrasound control especially, as they generally require the skin to be stretched.

Some pudendal varicose veins are nevertheless accessible for a UGFS by DNPI. It will then be necessary to puncture them very tangentially because they are subcutaneous.

On the other hand, vulvar varicosities cannot be injected without ultrasound monitoring.

Nevertheless, even in the case of sclerotherapy performed merely by sight, in all cases, DUS monitoring before starting the procedure and a DUS post-injection check must be routinely performed.

As in the case of reticular veins, it is necessary, for the puncture and the course of the injection, to be as atraumatic as possible (see previous paragraph).

For disinfecting the vulva, the alcohol solution is replaced by a Dakin solution

Summary of the role of the DUS in UGFS

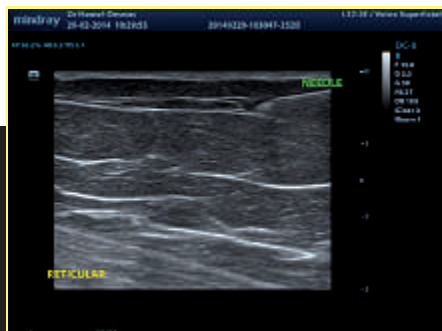As demonstrated in this chapter, the importance of DUS in UGFS should not be reduced to mere guidance of the needle.

The DUS + sclerotherapy combination is much more than that. It translates into a comprehensive approach, representing a concept, a culture, an entity, almost a "philosophy".

It is an inseparable "whole", resulting in a therapeutic approach that is no longer and will never again be "as before".

All of these concepts should be embraced and if we need to summarise the role of DUS in UGFS (and not only in UGFS), we would simply say that the ultrasound probe constitutes an "integral part" of the practitioner's hand during a phlebology consultation, and his own direct vision for patients vessels.

Fig. 25 : Puncture for UGFS by DNPI of the reticular vein (1.5 mm in diameter; 22 gauge needle, 40 mm long).
 UGFS: ultrasound-guided foam sclerotherapy
 DNPI: direct needle puncture-injection.

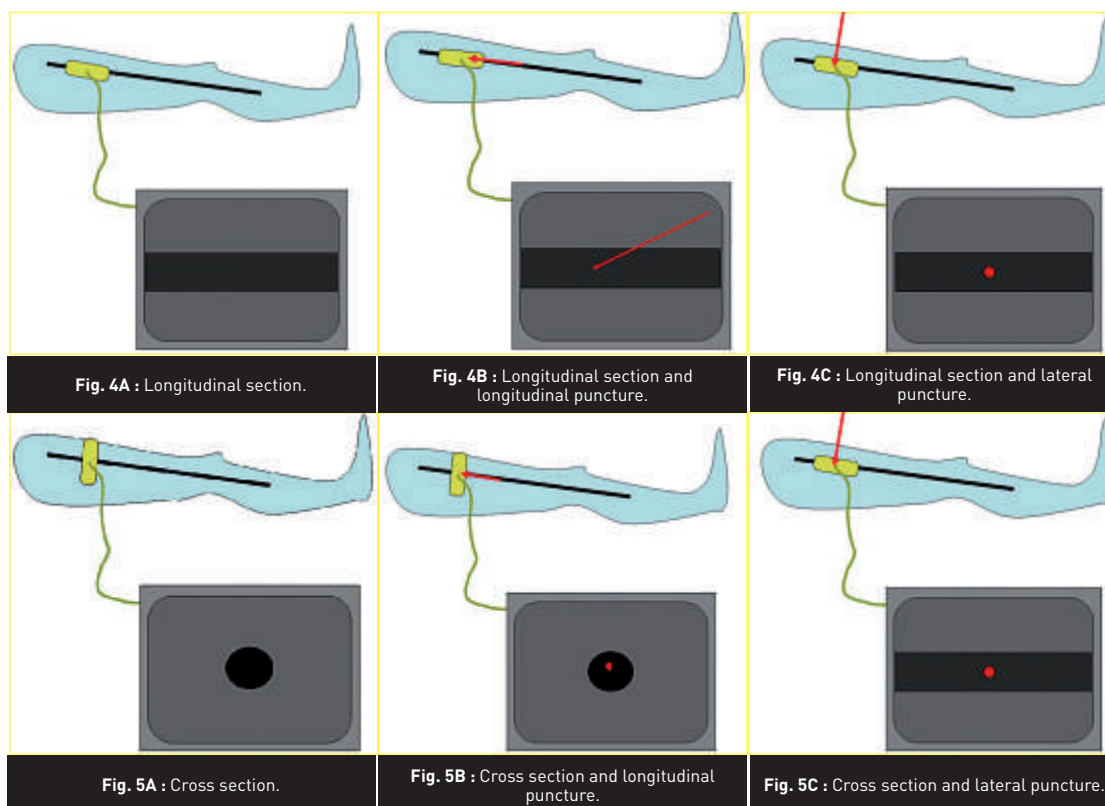


Use of duplex ultrasound during the procedure: foam sclerotherapy

Claudine Hamel-Desnos

Annexes

The various ultrasound sections and punctures (courtesy of JJ Guex)



References

- [1] Schadeck M. Doppler et échotomographie dans la sclérose des veines saphènes. *Phlébologie*. 1986; 39:697-716.
- [2] Knight R.M., Vin F., Zygmunt J.A. Ultrasonic guidance of injection into the superficial venous system, *Phlébologie* 1989, A. Davy, R. Stemmer. John Libbey Eurotext; 339-41.
- [3] Cabrera Garrido J.R. Elargissement des limites de la sclérothérapie : nouveaux produits sclérosants, *Phlébologie* 1997; 50: 181-8.
- [4] Monfreux A. Traitement sclérosant des troncs saphéniens et leurs collatérales de gros calibre par la méthode MUS, *Phlébologie* 1997; 50: 351-3.
- [5] ANSM. Agence Nationale de Sécurité du Médicament et des Produits de Santé ; <http://ansm.sante.fr/>; <http://agence-prd.ansm.sante.fr/php/ecodex/rcp/R0225261.htm>. 2013.

Use of duplex ultrasound during the procedure: foam sclerotherapy

- [6] ANAES. Traitement des varices des membres inférieurs. Rapport de l'Agence Nationale d'Accréditation et d'Évaluation en Santé. Service Évaluation en santé publique – Évaluation technologique Juin 2004.
- [7] Rabe E., Breu F., Cavezzi A., Smith PC., Frullini A., Gillet J, et al. European guidelines for sclerotherapy in chronic venous disorders. *Phlebology*. 2014; 29(6):338-54. Epub 2013/04/06
- [8] National Institute for Health and Clinical Excellence (NICE). Varicose veins in the legs. The diagnosis and management of varicose veins. July 2013; NICE clinical guideline 168; guidance. <https://www.nice.org.uk/guidance/cg168/chapter/1-Recommendations>.
- [9] Document developed under the auspices of The European Venous Forum, The International Union of Angiology, The Cardiovascular Disease Educational and Research Trust (UK), Union Internationale de Phlébologie. *International Angiology* 2014 April; 33(2):87-208. Management of chronic venous disorders of the lower limbs Guidelines according to scientific evidence.
- [10] Coleridge Smith P. Chronic Venous Disease Treated by Ultrasound Guided Foam Sclerotherapy. *Eur J Vasc Endovasc Surg* 2006; 32: 577-583.
- [11] Myers KA., Jolley D., Clough A., Kirwan J. Outcome of ultrasound-guided sclerotherapy for varicose veins: medium-term results assessed by ultrasound surveillance. *Eur J Vasc Endovasc Surg*. 2007 Jan; 33(1): 116-21.
- [12] Barrett JM., Allen B., Ockelford A., Goldman MP. Microfoam ultrasound-guided sclerotherapy treatment for varicose veins in a subgroup with diameters at the junction of 10 mm or greater compared with a subgroup of less than 10 mm. *Dermatol Surg*. 2004 Nov; 30(11): 1386-90.
- [13] Shadid N., Neleman P., Lawson J., Sommer A. Predictors of recurrence of great saphenous vein reflux following treatment with ultrasound-guided foam sclerotherapy. *Phlebology* 2015; 30 (3): 194-199.
- [14] Lee CTD., Whiteley MS., Li J-M. Vein wall penetration of detergent sclerosants – an in vitro study using immunohistochemistry. *EVF 2014 June-Paris – abstract*.
- [15] Watkins MR. Deactivation of sodium tetradecyl sulphate injection by blood proteins. *Eur J Vasc Endovasc Surg*. 2011; 41(4): 521-5. Epub 2011/01/26.
- [16] Hamel-Desnos C., Desnos P., Ouvry P. Nouveautés thérapeutiques dans la prise en charge de la maladie variqueuse. *Echosclérophérapie et mousse*. *Phlébologie* 2003, 56, N°1, 41-8.
- [17] Hamel-Desnos C., Guias B., Jousse S., Desnos P., Bressolette L. Echosclérophérapie à la mousse par ponction-injection directe à l'aiguille : Techniques et doses. *Journal des Maladies Vasculaires Tome 31, N°4, 2006*: 180-189.
- [18] Hamel-Desnos C. L'échosclérophérapie à la mousse en pratique courante : indications et technique. *Phlébologie* 2013, 66: 23-27.
- [19] Hamel-Desnos C., Moraglia L., Ramelet AA. Sclérophérapie. In: *La Maladie veineuse chronique*. Elsevier Masson SAS 2015: 89-126.
- [20] Bradbury A.W., Bate G., Pang K., Darvall K.A, Adam D. J. Ultrasound-guided foam sclerotherapy is a safe and clinically effective treatment for superficial venous reflux. *J Vasc Surg* 2010; 52: 939-45.
- [21] Devereux N., Recke AL., Westermann L., Recke A., Kahle B. Catheter-directed foam sclerotherapy of great saphenous veins in combination with pre-treatment reduction of the diameter employing the principals of perivenous tumescent local anesthesia. *Eur J Vasc Endovasc Surg*. 2014 Feb; 47(2): 187-95. doi: 10.1016/j.ejvs.2013.10.017. Epub 2013 Oct 30.
- [22] Hamel-Desnos C., Ouvry P., Benigni JP., Boitelle G., Schadeck M., Desnos P., et al. Comparison of 1% and 3% polidocanol foam in ultrasound guided sclerotherapy of the great saphenous vein: a randomised, double-blind trial with 2 year-follow-up. «The 3/1 Study». *Eur J Vasc Endovasc Surg*. 2007; 34(6): 723-9; discussion 30. Epub 2007/09/22.
- [23] Ceulen RP., Bullens-Goessens YI., Pi-Van de Venne SJ., Nelemans PJ., Veraart JC., Sommer A. Outcomes and side effects of duplex-guided sclerotherapy in the treatment of great saphenous veins with 1% versus 3% polidocanol foam: results of a randomized controlled trial with 1-year follow-up. *Dermatol Surg*. 2007; 33(3): 276-81. Epub 2007/03/07.
- [24] Blaise S., Bosson JL., Diamand JM. Ultrasound-Guided Sclerotherapy of the Great Saphenous Vein with 1% vs. 3% Polidocanol Foam: A Multicentre Double-Blind Randomised Trial with 3-Year Follow-Up. *Eur J Vasc Endovasc Surg*. 2010. Epub 2010/03/09.
- [25] Erkin A., Kosemehmetoglu K., Diler MS., Koksak C. Evaluation of the Minimum Effective Concentration of Foam Sclerosant in an Ex-vivo Study. *Eur J Vasc Endovasc Surg*. 2012; 44(6): 593-7. Epub 2012/11/06.
- [26] Desnos P. Différentes possibilités de faire de la mousse avec du polidocanol 1 %. À partir d'une solution pure ou à partir de polidocanol 2 % : est-ce similaire ? *Phlébologie* 2016 (in press).