



Deep venous reflux correction in chronic venous insufficiency: when and how?

Correction du reflux veineux profond dans l'insuffisance veineuse chronique : quand et comment ?

Maleti O.

Summary

The exact role played by surgical procedures in treating deep venous pathologies is not yet well established.

Actually, no wide-ranging studies in this field exist, and clinical experience is based on the work of only a few centres around the world.

However, increased attention is being devoted to deep venous system treatment, largely due to the introduction of procedures, which prove effective in bringing relief to patients with severe chronic venous insufficiency.

The new procedures address proximal obstruction and reflux.

A diagnostic protocol, based on multiple investigations, has been designed to plan a treatment strategy.

The latter involves endovascular and open surgery techniques, applied either separately or in association

Patients with chronic venous insufficiency, in whom the treatment of superficial system incompetence failed, and who did not respond to conservative treatment, can now take advantage of deep venous procedures.

Deep venous procedures are safe and effective: their purpose is to prevent further progress of the pathology towards severe-stage of chronic venous insufficiency.

Keywords: deep venous surgery, Chronic venous insufficiency, Venous stenting, Valvuloplasty, Neovalve.

Résumé

L'efficacité des interventions chirurgicales dans le traitement des pathologies du système veineux profond n'est pas encore clairement établie.

Nous ne disposons pas à ce jour d'études de forte puissance et les indications de ce traitement reposent sur l'expérience et les publications de quelques centres spécialisés. Cependant, le traitement des pathologies du système veineux profond suscite un intérêt indiscutable lié aux résultats fournis par l'utilisation de nouvelles techniques qui améliorent les patients qui présentent une insuffisance veineuse chronique sévère.

Ces nouvelles techniques traitent l'obstruction et le reflux. Le protocole diagnostique inclut des investigations variées dont le but est de planifier une stratégie interventionnelle précise et spécifique. Les interventions se déclinent en chirurgie à ciel ouvert et procédures endoveineuses, celles-ci étant réalisées à titre isolé ou en association. Les malades qui présentent une insuffisance veineuse chronique, chez lesquels le traitement conservateur ou celui de l'insuffisance superficielle s'est traduit par un échec, peuvent bénéficier de ces nouvelles techniques opératoires.

Elles sont efficaces et sûres : leur but est de limiter l'évolution inéluctable vers les stades les plus sévères de l'insuffisance veineuse chronique.

Mots-clés : chirurgie veineuse profonde, insuffisance veineuse chronique, Stenting veineuse, valvuloplastie, neovalve.

Introduction

Deep venous surgery has always been considered a kind of surgery deserved to patients with severe diseases, without any possible medical treatment either in obstruction or reflux disorders.

The obstruction treatment has been usually deserved for extrinsic compression, particularly in neoplastic disease or for deep venous thrombosis (DVT) with ischemic evolution (Phlegmasia Cerulea Dolens).

Oscar Maleti, MD, Chief of vascular and endovascular surgery and Director of Hesperia Hospital Deep Venous Surgery Center, Department of cardiovascular surgery, Hesperia hospital, Via Arquà 80, 41125 Modena (Italy).

Director for research. Interuniversity Center Math-Tech-Med University of Ferrara. Honorary member of French Society of Phlebology. E-mail: maleti@chirurgiavascolaremodena.it

Similarly, anatomic lesions in chronic venous insufficiency (CVI) has seldom been treated by surgeon all the more so the treatment of reflux.

Bypass for occlusion and valve reconstruction for reflux where procedures performed in very few Centres around the world.

The reasons for this are the disappointing outcomes in both venous bypass and post-thrombotic valvular reconstruction, probably due to insufficient diagnosis and inadequate treatment strategy.

The attention of phlebologists has been usually directed to the superficial system [1, 2] and perforators [3], treating the deep system by compression therapy alone [4].

The introduction of stenting [5] in treating ilio caval obstruction and the introduction of new surgical procedures [6] have been accepted with reluctance and very little promoted.

It's difficult to establish the reasons for this, certainly the absence of an adequate know-how in this field play a crucial role.

The purpose of this paper is to define a picture for deep venous surgery which could help the reader in suggesting investigations and deep venous procedures for patients affected by chronic venous insufficiency.

Etiology

Deep venous reflux is classically distinct in "primary", "secondary" and "congenital". "Primary" [7, 8, 9] identifies an unknown malfunction of the valve despite the fact that congenital anomalies can be supposed in many cases (asymmetrical cusps, redundant leaflets etc.).

In other conditions the valve is normal and it's simply overloaded by superficial system incompetence [1, 2].

Despite the fact that these two conditions are clearly so different, both the conditions are inscribed in the same group, deserving the term congenital incompetence to conditions with venous aplasia or hypoplasia (**Figure 1**).

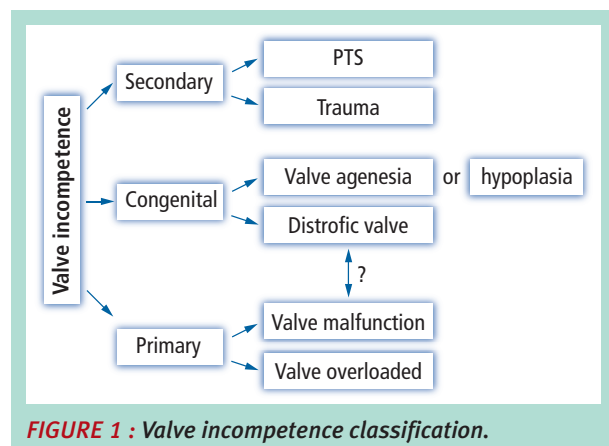


FIGURE 1 : Valve incompetence classification.

Secondary deep venous insufficiency is a consequence of deep venous thrombosis and represents the major rate [10] (40 to 70%) of patients with deep venous valvular incompetence. The distinction between primary and secondary is not always performable because occurrence of both pathologies within a patient in more frequent than expected.

The rapid resolution of DVT can preserve the valve morphology simply thickening the leaflets or we can have segmental destruction of the valves with preservation of them in other segment.

Secondary deep venous reflux is a complex pathology characterized in 2/3 of cases in association of obstruction and reflux. Obstruction is a common lesion in post thrombotic syndrome (PTS) that involves iliac, common femoral vein (CFV), femoral vein (FV) and popliteal vein but it is particularly hemodynamically significant in its proximal localization.

Other forms of proximal obstruction variously associated with deep or superficial vein incompetence and named NIVL (Non-thrombotic Iliac Vein Lesion) are due to extrinsic compression or intraluminal congenital defects [11].

Diagnostic evaluation

Symptoms and signs are those described for chronic venous insufficiency. There are no pathognomonic symptoms and signs to define deep venous reflux, being the same anatomical lesion correlated either to clinical class C2 or C6.

However, severe deep vein axial reflux is usually correlated with severe symptoms and signs [12]. Obstruction and reflux determine common results of two hemodynamic alterations, consisting in obstacle to flow and reflux. It is not possible at the moment to distinguish the respective role of obstruction and reflux [13], variously correlated, in regard with clinical classes.

However, deep venous surgery is usually deserved for C4b-C6 patients or seldom to selected patients in class C2-C3.

The indication to treatment is based on patient selection and diagnostic protocol (**Figure 2**).

The diagnostic protocol involves ultrasound (US) evaluation, air plethysmography [14], venography [15] and intravascular ultrasound (IVUS) [16].

It is common thinking that US are exhaustive in defining the venous abnormalities of the lower limbs [17].

US are not sufficiently diagnostic in detecting proximal obstruction and given that, as mentioned before, iliac lesions are frequently present and represent the first site to treat in most patients, further investigations are needed.

Deep venous reflux correction in chronic venous insufficiency: when and how?

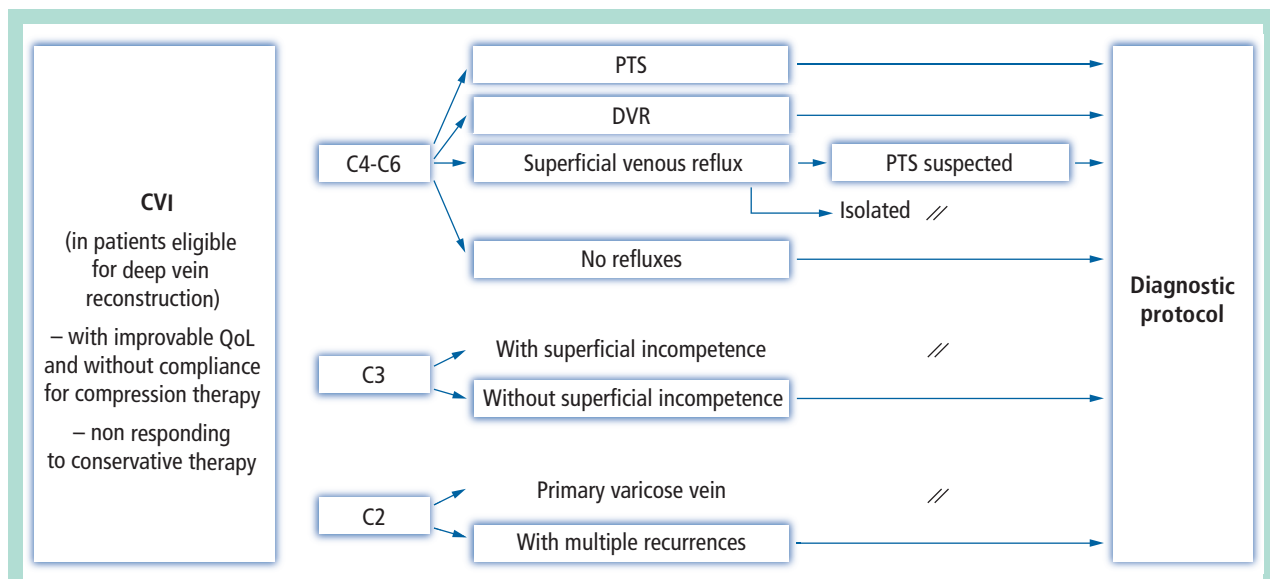


FIGURE 2 : Patient selection for diagnostic protocol.

US is able to detect the reflux, except in particular cases with low buffering effects of the calf, the reflux can be neglected or under evaluated.

The reflux is not the only hemodynamic alteration correlated with valve malfunction, modified volume and compliance in patient with CVI and malfunctioning valve may be under evaluated in a standard US exam.

The evaluation of patients with CVI should furthermore elucidate functional data like the calf pump efficiency [18]. The restoration of a valve at thigh is an insufficient condition to maintain a low volume of the leg during walking if not associated with efficient calf contraction.

Poor results in some series can be attribute to a non-accurate patient selection.

Other parameter like VFI (venous filling index), EF (ejection fraction), RVF (residual volume fraction) are particularly useful in follow up evaluation [19].

Any macrocirculatory disorders will exercise a direct action at microcirculatory level and the restore of the latter doesn't occur immediately after the restore of valve function. A microcirculatory evaluation is particularly useful to monitor the reversibility of microcirculatory lesions and how to improve it by means of pharmacological and compression therapy.

When a patient is candidate to deep vein correction treatment will be submitted to iliocaval and descending venography [15] and to IVUS [16] when proximal obstruction is suspected and not well detected. IVUS represent at the moment the gold standard technique in detecting proximal obstruction but the correlated costs and adequate learning curve are limiting factor in the diffusion of this method.

The diagnostic protocol, as shown in **Figure 2**, will be applied in any patient eligible for deep vein reconstruction with:

- improvable QoL (Quality of Life) and not responding or without compliance for compression therapy;
- in patients C4-C6 affected by non-PTS or presenting deep venous reflux, or with superficial venous reflux and suspected post-thrombotic syndrome, or in absence of any reflux;
- in patients C3 where any superficial insufficiency as been detected;
- in-patient C2 with multiple recurrences.

Surgical treatment

The valve incompetence surgical treatment [20] is schematically shown in **Figure 3**.

It involves essentially two kinds of procedures, valvuloplasty and creation of a non-refluxing segment [21].

Valvuloplasty

Valvuloplasty is performable when the valve apparatus is sufficiently preserved to be repaired. This event occurs in primary incompetence and rarely in secondary.

The intervention of reference is valvuloplasty according to **Kistner** [22]. It consists in stretching the leaflets reducing the redundancy of the leaflet itself (**Figure 4**).

Other techniques aimed to modify the first **Kistner** proposal by adding technical details [23, 24, 25] on phlebotomy and how to avoid valve damage during the procedure.

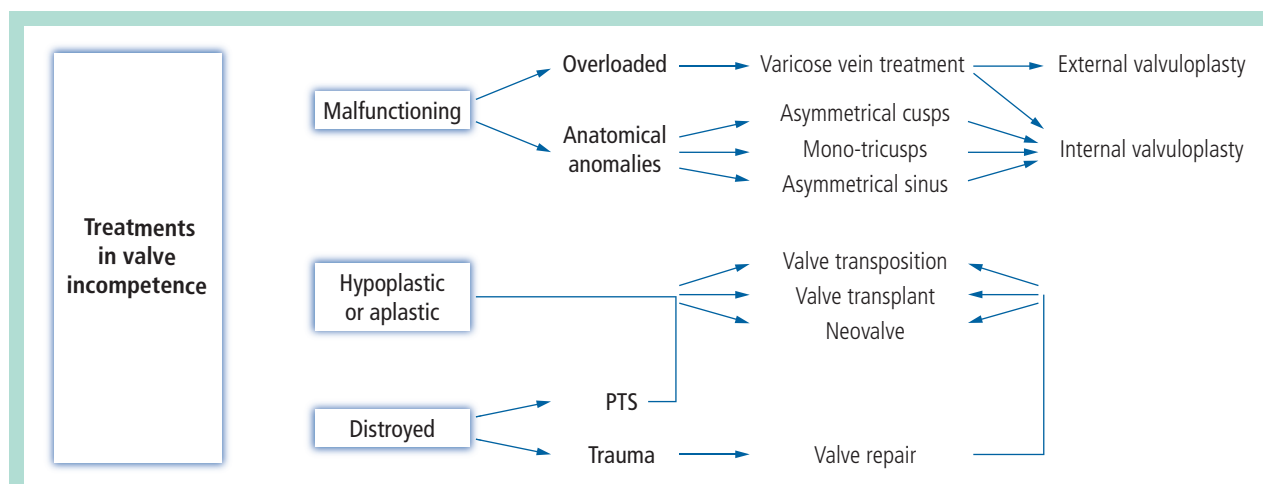


FIGURE 3 : Treatments in valve incompetence.

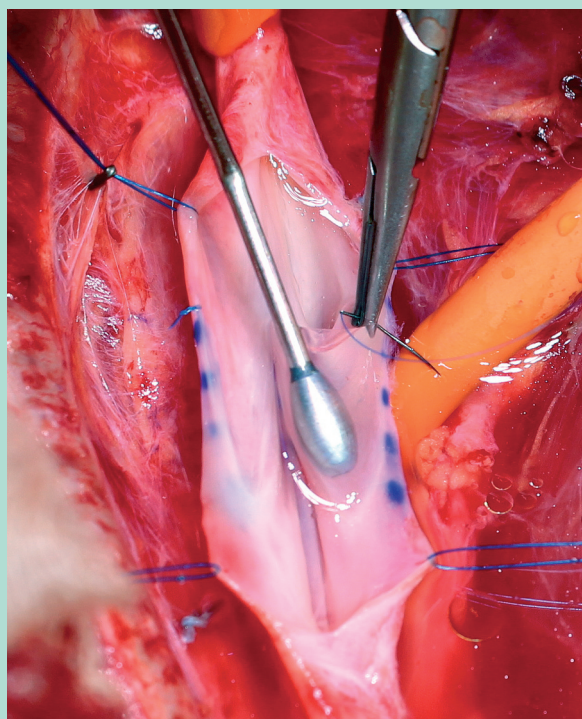


FIGURE 4 : Internal valvuloplasty.

External valvuloplasty is a technique that consists in reducing the commissural angle applying external stitches without phlebotomy [26, 27, 28].

The less precise procedure and the risk to reduce excessively the sinus of the vein gives less satisfying results.

Considering that frequently the valve malfunction is due to valve anomalies like asymmetrical cusps insertion, we prefer instead of stretching the valve, to reduce itself lifting the commissure restoring their symmetry and maintaining the sail effect action of the sinus [29].

In secondary deep vein incompetence and in valve agenesis the valve completely destroyed or rudimentary. In both cases are not possible to perform a valvuloplasty and other techniques are needed.

Aim of these techniques is to create a new competent segment, they are: vein transposition, vein transplant and neovalve.

Vein Transposition

Vein transposition [30, 31, 32] is a technique consisting in transposing a devalvulated segment below a valvulated one, usually employing profunda vein or saphenous vein.

Transposition on profunda vein can use termino-lateral or end-to-end anastomosis in based of anatomical features.

It offers very good results but it seldom applicable due to anatomic limitation offered by profunda vein or incompetence of the profunda vein itself or for incompetence or previous ablation the great saphenous vein (GSV).

When the latter is available, it is preferable to transpose itself in the subfascial area to obtain a new competent axis (Figure 5).

The discrepancy in caliber must be corrected with surgical techniques and a cuff to prevent a subsequent dilatation of the segment can be applied below the valve itself.

Vein Transplant

This technique aims to insert a segment containing a competent valve inside an incompetent axis.

The donor segment is usually the axillary vein (AV), as first described by Raju [33], or the brachial vein, as proposed by Taheri [34] and other authors [35, 36].

Deep venous reflux correction in chronic venous insufficiency: when and how?

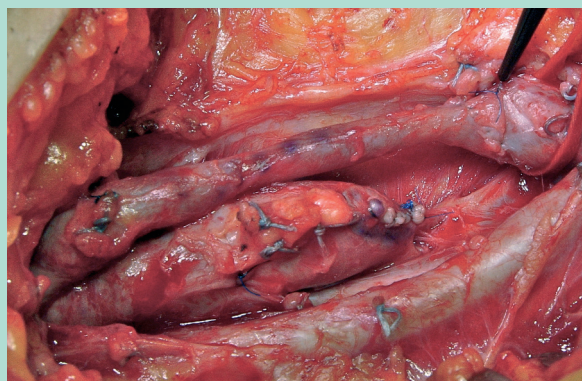


FIGURE 5 : Transposition creating a new axialisation.

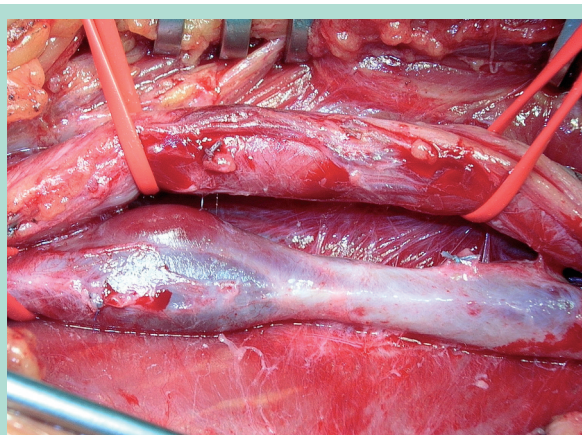


FIGURE 6 : Vein transplant at popliteal level.

The major disadvantage with this technique may be incompetence in the donor segment and discrepancy in caliber between the two segments. It is not necessary to restore anatomical continuity at the donor site because abundant collateral pathways ensure good compensation, and therefore complications resulting from removal of the AV are rare.

Before removal, the segment should be tested for the competence of the valve (or valves) it contains. Should the latter be incompetent, bench reconstructive surgery may be used, but this technique is not easy to perform.

The segment should be implanted in the most suitable receptor segment, either in the femoral or popliteal vein (**Figure 6**), depending on its caliber. Where implant in the popliteal vein is the chosen option, given the multi-axiality of the same, the competence of parallel axes should be ascertained in advance. Should competence not be ascertained, the incompetent refluxing parallel axis should be ligated.

This technique is correlated with a high risk of postoperative thrombosis, making it imperative to avoid creating twisting, tension and stenosis at the suture site.

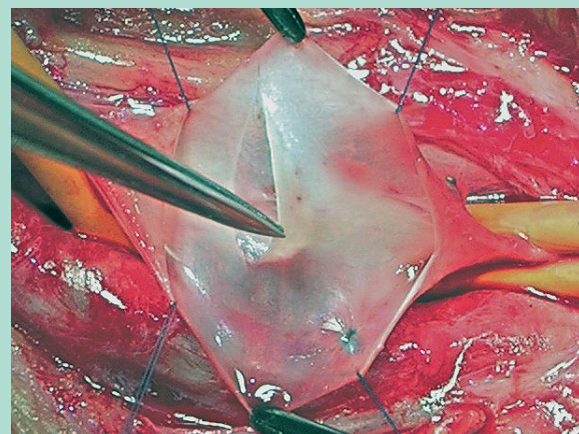


FIGURE 7 : Neovalve in valve agenesis.

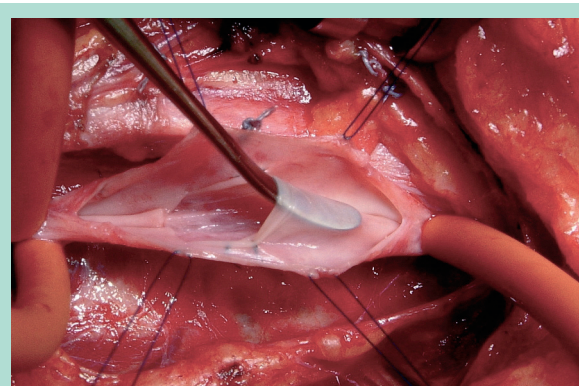


FIGURE 8 : Neovalve in post-thrombotic syndrome.

Neovalve

The neovalve is a technique based on the principle of reconstructing a new autologous valve by refashioning the patient's own vein wall [37].

Raju and Hardy [38] had created a *de novo* valve using a valvulated portion of the saphenous vein or a tributary of the axillary vein, which they inserted into the femoral vein; the results were very good despite the limited number of cases reported.

Plagnol [39] created a neovalve located in the terminal portion of the GSV, invaginating this portion of the saphenous vein into the common femoral vein.

In the version proposed by **Maleti**, the neovalve is obtained by dissecting the vein wall in such a way as to create a flap.

Also applicable in cases of valve agenesis (**Figure 7**), the neovalve is easier to perform in PTS, thanks to the characteristic thickening of vein wall tissue (**Figure 8**).

The Maleti neovalve technique cannot be standardized due to the anatomical variables in the vein wall and the diversity of post thrombotic lesions.

The choice of site for the neo valve, as well as the technical variations to be adopted in constructing it should be based on high-resolution ultrasound evaluation.

However, this decision can (and therefore should) usually be made only after a phlebotomy has been performed.

There are many varieties of post thrombotic lesion: slight thickening of the vein wall, uniform or otherwise; synechiae or septa; endoluminal fibrotic tissue which creates a double channel; notable thickening of the vein wall with fibrosis occupying a large part of the lumen.

Except for the first of these conditions, endophlebectomy should normally be associated.

The principal risk with the neo valve technique is postoperative re-adhesion of the flap at the dissection site. This can be prevented by applying specific sutures [40].

The neo valve may be bicuspid or monocuspid, depending on the features of the vein wall.

The monocuspid valve should be made deeper in order to prevent leakage.

It is now known that physiological valve function is determined by the shape of the valve itself.

Since the neo valve does not completely comply with the natural model, the washout action performed by the sinus is missing.

This leads to reduce movement in the flap, which in turn can create a thrombosis in the valve sinus itself.

To avoid this eventuality, when applicable, a flap is created at the site of a tributary in order to determine a competing flow.

Other authors have suggested a technique whereby a portion of the vein wall is invaginated to create a flap and the wall itself is reconstructed using a polytetrafluoroethylene (PTFE) patch.

The disadvantage with this technique is that, since the neo valve is open laterally, the flap is not able to fragment the hydrostatic pressure.

However, the consequent reduction in volume of the reflux will lead to partial functioning of the neo valve when associated with efficient ambulation [41].

Strategies

The distinction in primary, secondary and congenital is fundamental to set up operative strategy [20, 42].

We know that in primary insufficiency we can obtain the competence of the deep venous system only by treating the superficial system, because the deep reflux can represent a functional overload of the deep system when associated with a significant superficial reflux [1].

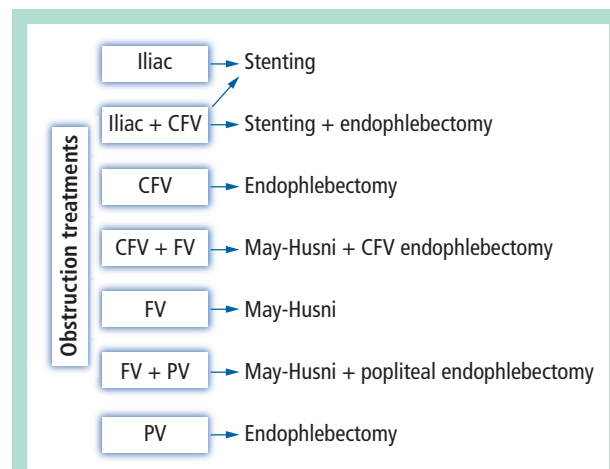


FIGURE 9 : Obstruction treatments.

The reduction of deep overload can restore the valve competence only when the valve is normal, conversely when it is dysplastic the valve reconstruction should be the first option because the reduction of deep overload is not able to restore the valve function.

Valve agenesis is characterized by the absence of valve in the entire venous tree and usually manifests in young patients with severe CVI and low QoL level [43].

When superficial reflux and deep venous reflux due to valve agenesis are associated, any attempt to be radical in the ablation of varicose vein usually fails.

Valvuloplasty is not performable; other direct surgical options may obtain transitory results.

Thus, we apply first two indirect actions: ensure a functional and efficacious flow by treating the proximal obstruction frequently associated and increase the calf pump efficacy [18].

The need to treat the deep system through a direct approach is reserved to patients in C4b-C6. In these cases neo valve construction is a good option.

PTS can present different hemodynamic alterations, variously associated: proximal obstruction (iliocaval level), common femoral vein obstruction, femoral and popliteal obstruction and reflux, parallel refluxes in collateral pathway, tibial obstruction and reflux, superficial and perforators reflux.

PTS is a complex pathology characterized by two principal hemodynamic disorders: increased in resistance to flow (obstruction), due to stenosis, intraluminal synechiae, rigidity of the venous wall [44] and reflux, due to valve damage [12].

Both the elements, obstruction and reflux, can be isolated or variously associated in the same site or in different sites. The obstruction treatment strategy is shown in **Figure 9**.

Deep venous reflux correction in chronic venous insufficiency: when and how?

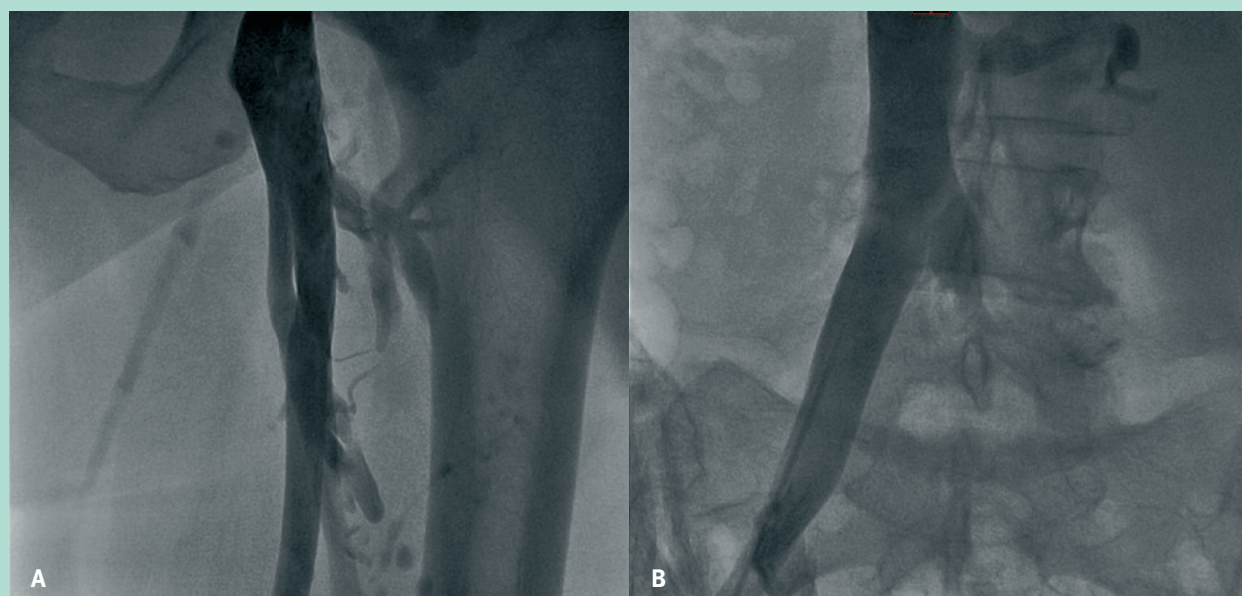


FIGURE 10 : Associated reflux (A) and proximal obstruction (B) in post-thrombotic syndrome.

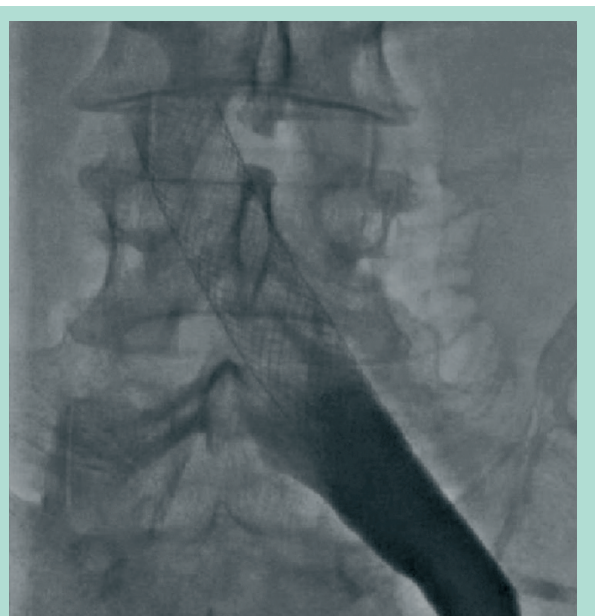

FIGURE 11 : Iliac venous stenting.

Usually obstructive lesions are in proximal iliac and common femoral vein, while reflux is in femoral-popliteal-tibial segment (**Figure 10, A, B**). Reflux is directly correlated with CVI.

Operative strategy in PTS [45] considers, at first, the treatment of proximal obstruction by means of venous stenting (**Figure 11**).

This for two reasons: almost half of the patients can improve without other surgical procedures; in the other half of patients not responding to stenting alone, we can correct the reflux thanks to the improved flow.

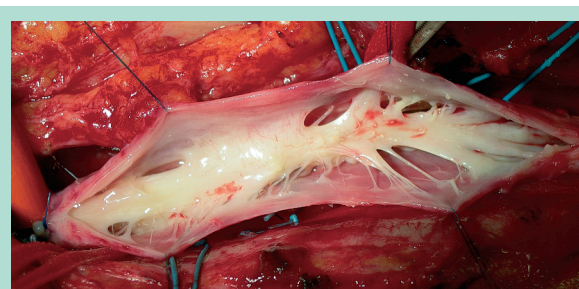


FIGURE 12 : Common femoral vein: intraluminal fibrosis in post-thrombotic syndrome.

Secondly we should address our attention to common femoral obstruction. Obstructive lesions at this level represent an obstacle in a crucial point of the leg that can be corrected applying endophlebectomy, which consists in the surgical removal of intraluminal fibrosis (**Figure 12**).

Thirdly, we must attentively evaluate the femoro-popliteal segment. Always considered the sole cause of the reflux, it is on the contrary a problem of reflux and obstruction associated. The improvement we can obtain after a venous femoro-popliteal bypass or a May-Husni operation [46] (**Figure 13**), despite the incompetence of the saphenous vein, is proof that the inflow is crucial.

Fourthly, in patients without improvement, we can consider deep venous reflux correction, by means of transposition, transplant or neovalve reconstruction.

After correcting the deep axial reflux, we should consider the parallel refluxes [47].

The correction can be performed by means of endovascular occlusion technique (**Figure 14**).

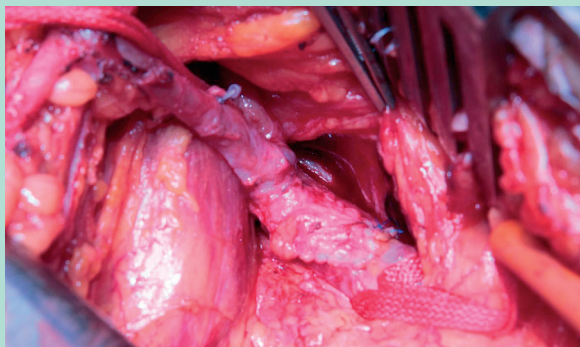


FIGURE 13 : *May-Husni procedure in femoral occlusion.*

Conclusions

Any patient with CVI who is able to maintain a good QoL and satisfying conditions simply treating the superficial venous system or applying compression therapy doesn't need further investigations and procedures [48, 49].

Every patient with CVI, with poor QoL, with decompensated leg, low compliance for compression therapy and young age or multiple recurrences in varicose veins probably deserves further investigations, because by means of selected and well tolerated procedure we can considerably improve his condition [40, 50, 51, 52, 53, 54, 55, 56].

The complication rate of deep venous system (DVS) treatments is particularly rare, and DVS is safe [57]. The results are satisfying, particularly in primary incompetence, despite the heterogeneity of patients.

The less satisfying results obtained treating the secondary incompetence, are probably correlated with:

- not adequate knowledge in deep venous function;
- not adequate applied strategy (in the past proximal obstruction was underestimated and consequently not previously treated);
- wrong selection of patients;
- patients with advanced CVI and not reversible microcirculatory damage.

An accurate diagnostic protocol, associated with a treatment strategy, will probably be able to improve considerable the results in the future.

Independently of the results, the merit of the new DVS surgery approach has been to focus the attention on the whole venous system, avoiding to consider the superficial system and perforators isolately.

The DVS treatment increases our knowledge on venous pathophysiology, which still represent a poor understood field. To understand the interaction between obstruction and reflux and the interaction between superficial and deep venous system will certainly led to advantages in the future patient management.

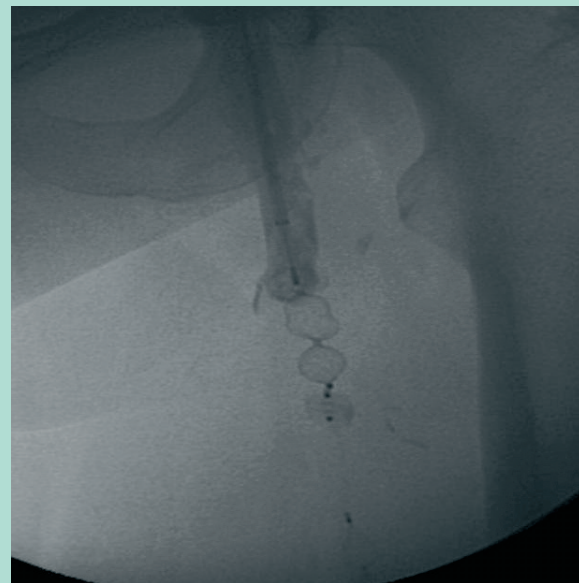


FIGURE 14 : *Parallel reflux: endovascular occlusion technique.*

References

1. Walsh J.C., Bergan J.J., Beeman S., Comer T.P. Femoral venous reflux abolished by greater saphenous vein stripping. *Ann. Vasc. Surg.* 1994 ; 8(6) : 566-70.
2. Ciostek P., Michalak J., Noszczyk W. Improvement in deep vein haemodynamics following surgery for varicose veins. *Eur. J. Vasc. Endovasc. Surg.* 2004 ; 28 : 473-8.
3. Kalra M., Gloviczki P. Surgical treatment of venous ulcers: role of subfascial endoscopic perforator vein ligation. *Surg. Clin. North. Am.* 2003 ; 83 : 671-705.
4. Mayberry J.C., Moneta G.L., Taylor L.M. Jr., et al. Fifteen-year results of ambulatory compression therapy for chronic venous ulcers. *Surgery* 1991 ; 109 : 575-81.
5. Raju S., Owen S., Neglen P. The clinical impact of iliac venous stents in the management of chronic venous insufficiency. *J. Vasc. Surg.* 2002 ; 35 : 8-15.
6. Maleti O. Venous valvular reconstruction in post-thrombotic syndrome. A new technique. *J. Mal. Vasc.* 2002 ; 27 : 218-21.
7. Eklöf B., Rutherford R.B., Bergan J.J., et al. Revision of the CEAP classification for chronic venous disorders: consensus statement. *J. Vasc. Surg.* 2004 ; 40 : 1248-52.
8. Nicolaidis A.N. (chair) and the Executive Committee of the ad hoc committee, American Venous Forum, 6th annual meeting. February 22-25, 1994, Maui, Hawaii: Classification and grading of chronic venous disease in the lower limbs: a consensus statement. In: Gloviczki P., Yao J.S.T., eds. *Handbook of Venous Disorders*. London, England: Chapman & Hall; 2001 : 653-6.
9. Porter J.M., Moneta G.L., and an International Consensus Committee on Chronic Venous Disease: Reporting standards in venous disease: an update.. *J. Vasc. Surg.* 1995 ; 21 : 634-45.

Deep venous reflux correction in chronic venous insufficiency: when and how?

10. Kahn S.R., Comerota A.J., Cushman M., et al. The postthrombotic syndrome: evidence-based prevention, diagnosis and treatment strategies. A scientific statement from the American Heart Association. *Circulation* 2014 ; 130(18) : 1636-61.
11. Neglen P. Endovascular reconstruction for chronic iliofemoral vein obstruction. In: Gloviczki P., ed. *Handbook of Venous Disorders*. Third edition. Guidelines of the American Venous Forum 2009 ; 44 : 491-502.
12. Danielsson G., Arfvidsson B., Eklöf B., et al. Reflux from thigh to calf, the major pathology in chronic venous ulcer disease: surgery indicated in the majority of patients. *Vasc. Endovasc. Surg.* 2004 ; 38 : 209-19.
13. Nicolaides A., Clark H., Labropoulos N., Geroulakos G., Lugli M., Maleti O. Quantification of reflux and outflow obstruction in patients with CVD and correlation with clinical severity. *Int. Angiol.* 2014 ; 33 : 275-81.
14. Criado E., Farber M.A., Marston W.A., et al. The role of air plethysmography in the diagnosis of chronic venous insufficiency. *J. Vasc. Surg.* 1998 ; 27 : 660-70.
15. Kistner R.L., Ferris E.B., Raudhawa G., Kamida C. A method of performing descending venography. *J. Vasc. Surg.* 1986 ; 4 : 464-8.
16. Neglen P., Raju S. Intravascular ultrasound scan evaluation of the obstructed vein. *J. Vasc. Surg.* 2002 ; 35 : 694-700.
17. Mattos M.A., Summer D. Direct noninvasive tests (duplex scan) for the evaluation of chronic venous obstruction and valvular incompetence. In: Gloviczki P., Yao J.S.T., eds. *Handbook of Venous Disorders*. London, England: Arnold; 2001 : 120-31.
18. Araki C.T., Back T.L., Padberg F.T., et al. The significance of calf muscle pump function in venous ulceration. *J. Vasc. Surg.* 1994 ; 20 : 872-7.
19. Gillespie D.L., Cordts P.L., Hartono C., et al. The role of air plethysmography in monitoring results of venous surgery. *J. Vasc. Surg.* 1992 ; 16 : 674-8.
20. Maleti O., Perrin M. Reconstructive surgery for deep vein reflux in the lower limbs: techniques, results and indications. *Eur. J. Vasc. Endovasc. Surg.* 2011 ; 41 : 837-48.
21. Maleti O., Lugli M., Perrin M. Chirurgie du reflux veineux profond. *Encyclopédie Médico-Chirurgicale (Elsevier Masson SAS, Paris), Techniques chirurgicales - Chirurgie vasculaire, 43-163, 2009.*
22. Kistner R.L. Surgical repair of a venous valve. *Straub. Clin. Proc.* 1968 ; 24 : 41-3.
23. Sottiurai V.S. Technique in direct venous valvuloplasty. *J. Vasc. Surg.* 1988 ; 8 : 646-8.
24. Tripathi R., Ktenedis K.D. Trapdoor internal valvuloplasty – a new technique for primary deep vein valvular incompetence. *Eur. J. Vasc. Endovasc. Surg.* 2001 ; 22 : 86-9.
25. Sottiurai V.S. Supravalvular incision for valve repair in primary valvular insufficiency. In: Bergan J.J., Kistner R.L., eds. *Atlas of Venous Surgery*. Philadelphia, PA: WB Saunders; 1992 : 137-8.
26. Kistner R.L. Surgical technique of external venous valve repair. *Straub. Found. Proc.* 1990 ; 55 : 15-6.
27. Gloviczki P., Merrell S.W., Bower T.C. Femoral vein valve repair under direct vision without venotomy: a modified technique with angioscopy. *J. Vasc. Surg.* 1991 ; 14 : 645-8.
28. Raju S., Berry M.A., Neglén P. Transcommissural valvuloplasty: technique and results. *J. Vasc. Surg.* 2000 ; 32 : 969-76.
29. Lurie F., Kistner R.L., Eklof B., Kessler D. Mechanism of venous valve closure and role of the valve in circulation. A new concept. *J. Vasc. Surg.* 2003 ; 38 : 955-61.
30. Kistner R.L. Surgical repair of the incompetent femoral vein valve. *Arch. Surg.* 1975 ; 110 : 1336-42.
31. Queral L.A., Whitehouse W.M., Flinn W.R., Neiman H.L., Yao J.S.T., Bergan J.J. Surgical correction of chronic deep venous insufficiency by valvular transposition. *Surgery* 1980 ; 87(6) : 688-95.
32. Raju S., Fountain T., Neglen P., Devidas M. Axial transformation of the profunda femoris. *J. Vasc. Surg.* 1998 ; 27 : 651-9.
33. Raju S. Discussion after late objective assessment of venous valve surgery. *Arch. Surg.* 1981 ; 116 : 1461-6.
34. Taheri S.A., Lazar L., Elias S., Marchand P., Heffner R. Surgical treatment of postphlebotic syndrome with vein valve transplant. *Am. J. Surg.* 1982 ; 144 : 221-4.
35. Bry J.D., Muto P.A., O'Donnell T.F., Isaacson L.A. The clinical and hemodynamic results after axillary-to-popliteal vein valve transplantation. *J. Vasc. Surg.* 1995 ; 21 : 110-9.
36. Cardon J.M., Cardon A., Joyeux A., et al. Use of ipsilateral greater saphenous vein as a valved transplant in management of postthrombotic deep venous insufficiency: long-term results. *Ann. Vasc. Surg.* 1999 ; 13 : 284-9.
37. Maleti O., Lugli M. Neovalve construction in postthrombotic syndrome. *J. Vasc. Surg.* 2006 ; 43 : 794-9.
38. Raju S., Hardy J.D. Technical options in venous valve reconstruction. *Am. J. Surg.* 1997 ; 173 : 301-7.
39. Plagnol P., Ciostek P., Grimaud J.P., Prokopowicz S.C. Autogenous valve reconstruction technique for post-thrombotic reflux. *Ann. Vasc. Surg.* 1999 ; 13 : 339-42.
40. Lugli M., Guerzoni S., Garofalo M., Smedile G., Maleti O. Neovalve construction in deep venous incompetence. *J. Vasc. Surg.* 2009 ; 49 : 156-62.
41. Opie J.C. Monocusp-novel common femoral vein monocusp surgery uncorrectable chronic venous insufficiency with aplastic/dysplastic valves. *Phlebology* 2008 ; 23 : 158-71.
42. Raju S., Fredericks R.K., Hudson C.A., et al. Venous valve station changes in "primary" and post-thrombotic reflux: an analysis of 149 cases. *Ann. Vasc. Surg.* 2000 ; 14 : 193-9.
43. Plate G., Brudin L., Eklof B., Jensen R., Ohlin P. Physiologic and therapeutic aspects in congenital vein valve aplasia of the lower limb. *Ann. Surg.* 1983 ; 198(2) : 229-33.
44. Neglen P., Thrasher T.L., Raju S. Venous outflow obstruction: an underestimated contributor to chronic venous disease. *J. Vasc. Surg.* 2003 ; 38 : 879-85.
45. Maleti O., Lugli M., Perrin M. Operative treatment in postthrombotic syndrome: an update. *Phlebology* 2014 ; 21(3) : 131-7.
46. Ryer E.J., Misra S., McBane R.D., et al. Great saphenous vein transposition to the popliteal vein (the May-Husni procedure). *J. Vasc. Surg. Venous and Lym. Dis.* 2013 ; 1 : 82-3.

47. Eriksson I., Almgren B. Influence of the profunda femoris vein on venous hemodynamics of the limb. Experience from thirty-one deep vein valve reconstructions. *J. Vasc. Surg.* 1986 ; 4 : 390-5.
48. Rutherford R.B., Padberg F.T. Jr., Comerota A.J., et al. Venous severity scoring: an adjunct to venous outcome assessment. *J. Vasc. Surg.* 2000 ; 31 : 1307-12.
49. Lamping D.L., Schroter S., Kurz X., et al. Evaluation of outcomes in chronic venous disorders of the leg: development of a scientifically rigorous, patient-reported measure of symptoms and quality of life. *J. Vasc. Surg.* 2003 ; 37 : 410-9.
50. Perrin M. Reconstructive surgery for deep venous reflux. A report on 144 cases. *Cardiovasc. Surg.* 2000 ; 8 : 246-55.
51. Masuda E.M., Kistner R.L. Long-term results of venous valve reconstruction: a four to twenty-one year follow-up. *J. Vasc. Surg.* 1994 ; 19 : 391-403.
52. Raju S., Fredericks R.K., Neglen P., Bass D. Durability of venous valve reconstruction techniques for primary and postthrombotic reflux. *J. Vasc. Surg.* 1996 ; 23 : 357-67.
53. Perrin M., Hiltbrand B., Bayon J.M. Results of valvuloplasty in patients presenting with deep venous insufficiency and recurring ulceration. *Ann. Vasc. Surg.* 1999 ; 13 : 524-32.
54. Perrin M.R. Results of deep-vein reconstruction. *Vasc. Surg.* 1997 ; 31 : 273-5.
55. Nash T. Long-term results of vein valve transplants placed in the popliteal vein for intractable post-phlebitic venous ulcers and preulcer skin changes. *J. Cardiovasc. Surg.* 1988 ; 29 : 712-6.
56. Sottiurai V.S. Results of deep-vein reconstruction. *Vasc. Surg.* 1997 ; 31 : 276-8.
57. Lurie F., Kistner R., Perrin M., Raju S., Neglen P., Maleti O. Invasive treatment of deep venous disease. A UIP consensus. *Int. Angiol.* 2010 ; 29 : 199-204.