



## Varicose veins of external popliteal sciatic nerve.

### *Les varices du nerf sciatique poplité externe.*

Enrici E.A., Mocellin M.M., D'Alotto C.

#### Summary

Based on our experience, the intention of this paper is to clarify doubts about the name as a clinical entity, its etiology and provide expertise regarding diagnosis and therapy.

**Material and methods:** From 2008 to date 36 lower limbs in 30 patients with varicose veins of the sciatic nerve with progression to external popliteal sciatic nerve were analyzed. They were suspected clinically and the diagnosis was confirmed with Doppler ultrasound, all performed by the same team.

The status of the deep venous system was also analyzed to separate this pathology from the persistence of the embryonic sciatic vein.

Association or not with varicose veins of other origin was found as well as the clinical features and the outcome of therapy, with periodic follow up to date.

**Results:** Of the 30 patients analyzed, 28 were women with similar frequency in both limbs. In 6 cases were bilateral.

The higher average age of 50 to 70 years and in contrast varicose pathology of another origin existed (4 cases).

The first manifestation was the appearance of varicose veins in the postero-external mid calf progressing to the external malleolus and the other with anterior direction near the head of the fibula.

Third of patients had lumbo-sciatalgia in the leg, and in the operated patients such symptom disappeared and also improved with venotonics.

The deep venous system was normal or near normal in all patients and external saphenous vein was insufficient in only 6 patients.

The treatment was surgical in 11 cases without recurrence to date; Sclerotherapy in 8 with periodic maintenance and follow up treatment in 17.

#### Résumé

À partir de notre expérience, notre objectif est de clarifier des doutes portant sur cette entité clinique, son étiologie, et de fournir une expertise sur son diagnostic et son traitement.

**Matériel et méthodes :** De 2008 à ce jour, 36 membres inférieurs chez 30 patients ayant des varices du nerf sciatique avec progression au niveau du nerf sciatique poplité externe étaient analysés. Évoqué cliniquement, le diagnostic a été confirmé par une échographie Doppler réalisée par la même équipe.

L'état du système veineux profond a également été analysé pour distinguer cette pathologie de la persistance d'une veine sciatique embryonnaire.

L'association ou pas à des varices d'une autre origine ainsi que les caractéristiques cliniques et les résultats des traitements, avec leur suivi périodique à jour, étaient observés.

**Résultats :** Parmi les 30 patients analysés, 28 étaient des femmes avec une fréquence similaire dans les deux membres. Dans 6 cas les varices étaient bilatérales.

La moyenne d'âge plus élevée de 50 à 70 ans, en contraste varices pathologie d'une autre origine existait (4 cas).

La première manifestation était l'apparition de varices veines de la face postéro-externe à mi-mollet progressant jusqu'à la malléole externe et en avant vers de la tête du péroné.

1/3 des patients avaient des lombo-sciatalgies de la jambe, et chez les patients opérés ces symptômes ont disparu et ont été également améliorés avec des veinotoniques.

Le système veineux profond était normal ou proche de la normale dans l'ensemble patients et la veine saphène externe était insuffisante chez seulement 6 patients.

Le traitement a été chirurgical dans 11 cas sans récurrence à ce jour. La sclérothérapie dans 8 cas pour la maintenance et le suivi du traitement dans 17 cas.

Ermenegildo Enrici A., PhD, MD.

Mario M. Mocellin, MD. Catholic University of Argentina.

Carlos D'Alotto, MD. "Diagnosis Maipú Institute", Vicente López, Buenos Aires, Argentina.

E-mail : [mocellin2002@yahoo.com.ar](mailto:mocellin2002@yahoo.com.ar)

❖❖❖ **Conclusions:** Varicose veins of external popliteal sciatic nerve constitute a clinical entity perfectly distinguishable from persistence of the embryonic sciatic vein. Clinical and Doppler ultrasound allow a certain diagnosis and a scheduled treatment. According to the size and age, surgery is the therapy of choice. Sclerotherapy may also be an alternative.

**Keywords:** *persistent sciatic vessel, external popliteal sciatic nerve, varicose veins, sclerotherapy.*

❖❖❖ **Conclusions :** *Les varices du nerf poplité externe nerve sciatique constituent une parfaite entité clinique distincte de la persistance de la veine sciatique embryonnaire. L'échographie Doppler et la clinique permettent d'assurer le diagnostic et un traitement programmé. Selon la taille et l'âge, la chirurgie est le traitement de choix. La sclérothérapie peut aussi être une bonne alternative thérapeutique.*

**Mots-clés :** *veines persistantes du nerf sciatique, nerf sciatique poplité externe, varices, sclérothérapie.*

## Introduction

Little is known about this varicose disease due to its very low frequency as well as difficulties in diagnosis. All this leads to many questions to be answered, in first place the confusion generated by its nomination and afterwards its etiology, clinical presentation and therapeutic possibilities.

This paper aims to present our casuistic, slightly more numerous than previous casuistic reported. The analysis has allowed us to understand some still unclear aspects of this disease as a clinical entity.

## Material and methods

36 members affected by varicose veins in sciatic nerve in 30 patients from 2008 to date are discussed.

Of these, 28 were women and 2 men.

The right lower limb was affected in 17 patients and the left in 19 patients.

The largest number of cases was detected between 50 and 70 years old.

In 4 patients it was the first varicose manifestation, the remaining 26 had previous varicose pathology of other origin, 10 of them had been operated for this reason.

Clinically one third of the patients had low back pain in the affected limb [11].

Topographically varicose veins were visible in supra-aponeurotic way above the popliteal fold only in 3 cases.

In 5 at the fold level and in 25 below the popliteal fold.

In 3 patients the veins of the nerve were found by ultrasound Doppler without varicose externalization.

Small saphenous vein was normal in 30 legs and in 6 legs it was insufficient.

30 patients presented no pathology in the deep venous system and 6 patients presented just mild and segmentary valvular insufficiency of essential type.

The treatment consisted of surgery in 11 cases, sclerotherapy in 6 and medical treatment and regular monitoring in 17.

The surgery was performed together with surgery on varicose veins of other origin, having no recurrences up to date.

## Discussion

The first case of this disease was reported by **P. Verneuil** [13] in 1890, and the second case almost 100 years after the first one, reported by **L.Thieri** [6].

**Seung Chai Yung** [10] globally analyzed the **frequency** of the origins of the varicose disease.

He found that 85% corresponded to insufficient saphenous arch, 4.7% to insufficient perforators and the rest (10%) to unusual causes.

The 83.5% of the latter was due to vulvoperineal varicose veins, 5% of the round ligament, 5% to the persistent sciatic vein, 2% to intraosseous perforators, 2.2% to Klippel-Trenaunay syndrome, 1.4 % to congenital venous malformations and 0.7% to porto-systemic collateral veins.

This analysis is generally accepted and shows the low frequency of the pathology analyzed.

It is necessary to clarify that sometimes this condition is called persistence of the sciatic vein, instead of varicose veins of the sciatic nerve or of the external popliteal sciatic nerve.

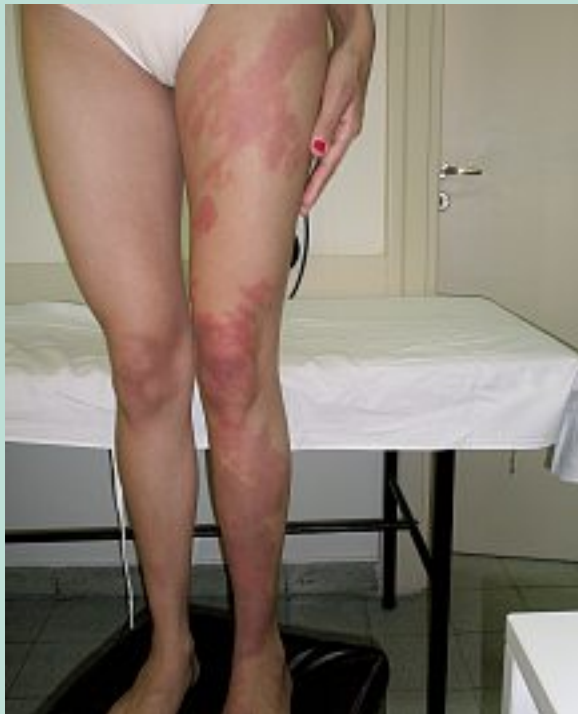**Embryonic persistence of the sciatic vein, originated at the axial plexus nerve has as manager angio nerve the sciatic nerve.**

Normally it atrophies and forms discontinuous arches along the nerve ending in the deep femoral vein or the superficial femoral.

On very few occasions persists as a tubular vein and without valves sharing venous return with normal veins, but on other occasions it becomes the main drainage path due to the atrophy of the superficial femoral vein.

**Embryonic sciatica vein** may remain complete or segmented, located at the top or the bottom of the thigh section.

## Varicose veins of external popliteal sciatic nerve.



**FIGURE 1 :** *Klippel-Trenaunay syndrome.*

This condition is usually seen in **Klippel-Trenaunay** [11] (**Figure 1** and **Figure 2**) **syndromes** as part of the characteristic triad (flat angioma, increased leg volume and varicose veins) with or without the presence of micro fistulas.

**Persistent embryonic sciatic vein** may facilitate the appearance of varicose veins in the sciatic nerve due to the hemodynamic alteration it generates.

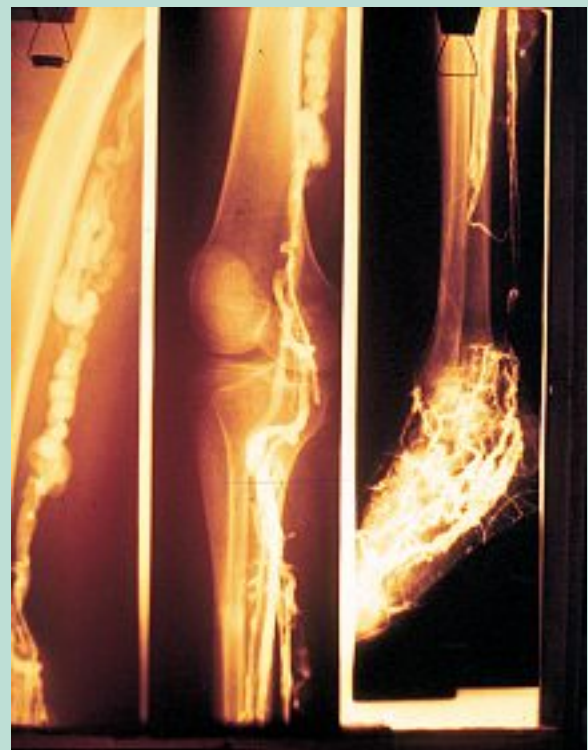Also **post-thrombotic syndromes**, which cause deep venous hypertension, can dilate veins of the sciatic nerve when mechanisms which compensate blood pressure like shunts to the deep femoral and the development of the competent satellite veins are inefficient (**Figure 3**).

Another invoked reason is **pelvic varicose pathology** with retrograde flow through ischial and/or gluteal veins, which would alter the venous drainage of nerves.

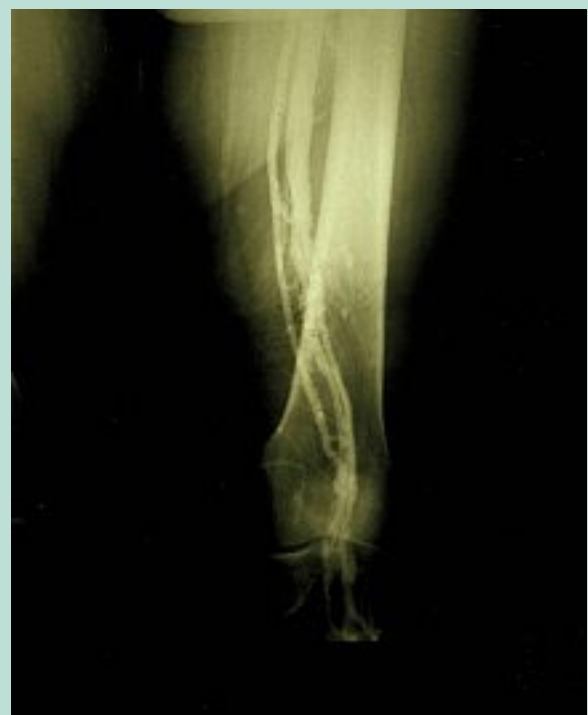About this topic **Nicos Labropoulos** [6] has described four plexuses that might be affected:

- a) direct venorum veins, the most common, from nerve to concomitant veins.
- b) indirect venorum veins, which leave the nerve and are connected with other large veins.
- c) peri-arterial no valvular venous plexus.
- d) peri-venous plexus, which is connected to thick cutaneous veins.

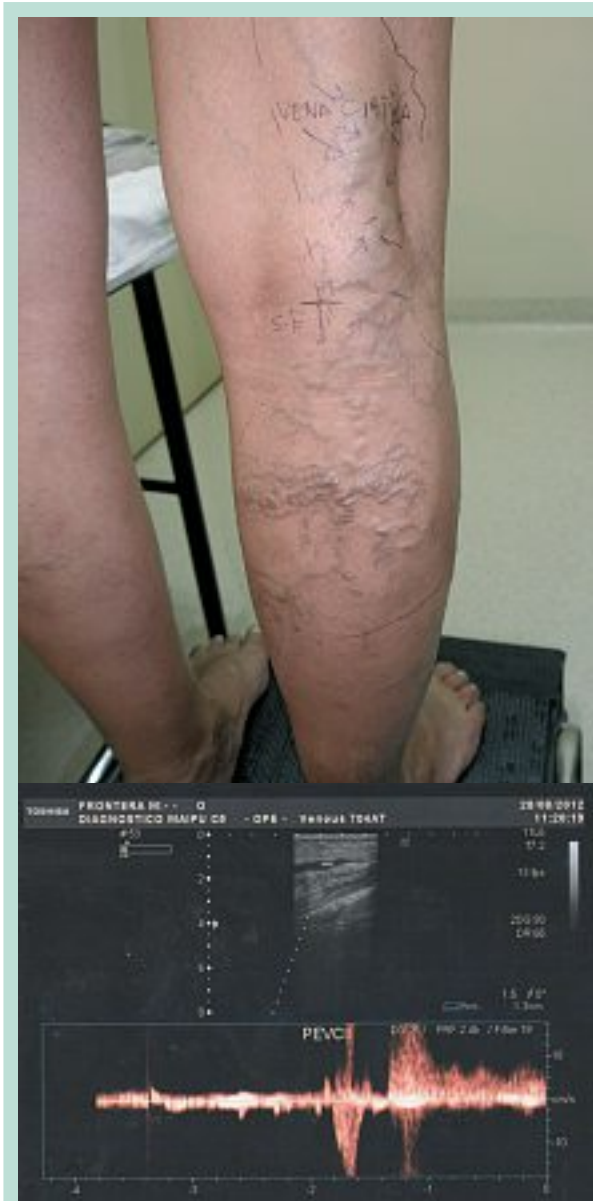These varicose veins due to reflux of peri-nervous veins appear dilated and become detectable with Doppler ultrasound, fact that does not normally happen.



**FIGURE 2 :** *Klippel-Trenaunay syndrome. Ascending phlebography, image showing the left and continuing embryonic persistence of the sciatic vein.*



**FIGURE 3 :** *Ascending phlebography, showing satellite vein of superficial femoral vein, in post-thrombotic syndromes.*

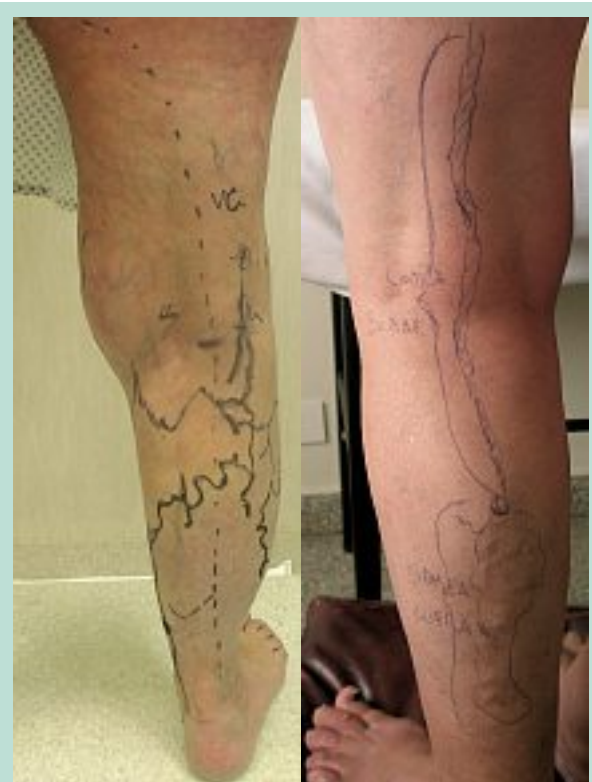

**FIGURE 4 :** Clinical manifestation and Doppler ultrasound study in a patient with varicose veins of the sciatic nerve during pregnancy.

Veins can run between the fibers of the sciatic nerve and even spiral to the main trunk in the epineurium, which leave in the popliteal fossa and superficialize on its outer face and back.

Thus they leave the external popliteal sciatic nerve with less circulation, which would explain the increased susceptibility to injury.

Interestingly there is no further description of varicose veins in the internal popliteal sciatic nerve, probably due to the permanent depth at which this nerve is in the leg.



**FIGURE 5 :** Left: clinical preoperative manifestation showing varicose veins of the sciatic nerve, accompanied by insufficient small saphenous vein and post-axial vein. Right: varicose veins of the sciatic nerve. The upper section is sub-aponeurotic and the lower section is supra-aponeurotic.

The fourth reason given is the **essential parietal valvular predisposition** indispensable for the emergence of this pathology.

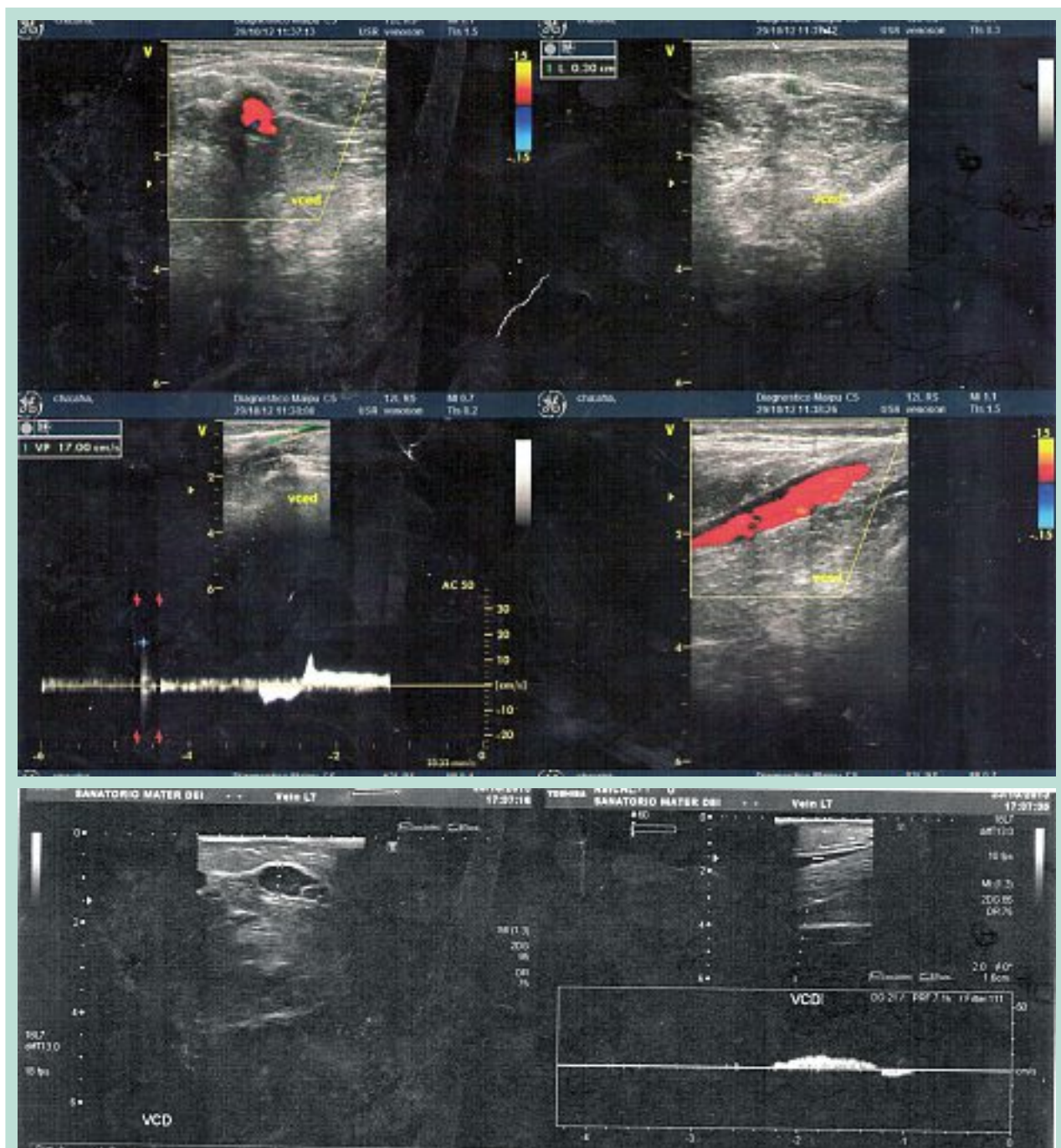
In women it can be triggered or aggravated by the **hormonal impregnation during pregnancy**. This was detected in a pregnant patient, disappearing in the postpartum, but relapsing in the second pregnancy with greater intensity, as sometimes happens in vulvar pathology (**Figure 4**).

Regarding the etiology, as a **conclusion**, it can be argued that the embryonic sciatic vein is a remanant of the post-axial vein.

On the other hand, varicose veins of the sciatic nerve, or peroneal sciatic nerve, are secondary to pelvic varicose veins, to primary hormonal varicose pathology, and less frequent of post thrombotic or embryonic origin.

The main **clinical manifestation** is the presence of varicose veins in the postero-external sector of the leg with a branch that follows the nerve around the fibular head and another to the external malleolus with probable connection with the external saphenous vein in the middle part of the leg (**Figure 5**).

Varicose veins of external popliteal sciatic nerve.



**FIGURE 6 :** Doppler ultrasound study showing varicose veins of the sciatic nerve with reflux.

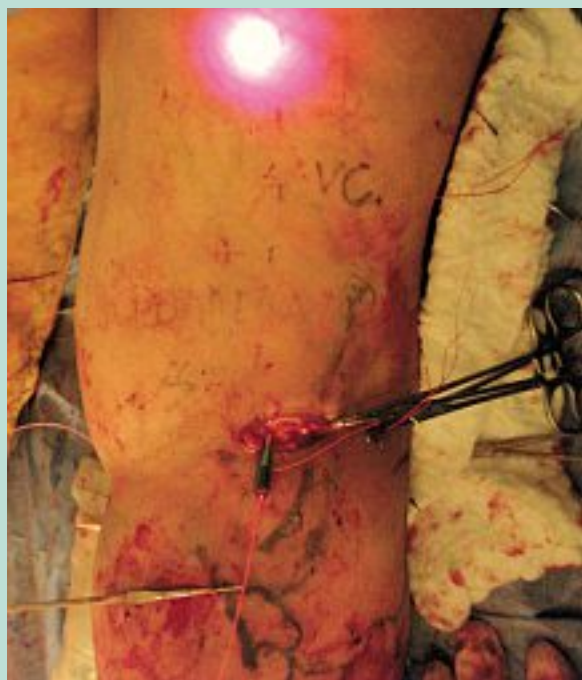Pain, heaviness or tiredness along the sciatic nerve, which increases when sitting and improves when standing or walking, was present in one third of patients. In those operated the symptoms disappeared.

The clinical **diagnosis** was supplemented by **Doppler ultrasound** [3].

This test first locates the external saphenous vein between the two calves, in the sub-aponeurotic displacement.

The sciatic nerve vein lays 3 cm outside the saphenous vein, as a tubular vein very next to the aponeurosis along the external popliteal sciatic nerve (**Figure 6**).

Upwards it follows the path of muscle mass being located out and in depth with respect to the post-axial vein, which is a continuation of the external saphenous vein. Downwards, it looks for the path of the external popliteal sciatic nerve, trying to become superficial.



**FIGURE 7 :** Endovascular laser treatment of post-axial vein. On the right the vein of the sciatic nerve can be observed.

According **P. Lemasle** [2, 4] these findings are pathognomonic, being the Doppler ultrasound more than enough to complete the diagnosis.

In the **differential diagnosis** perforators of the popliteal fossa should be considered, especially when they are located on the outer half backside of this area. When in doubt, Doppler ultrasound clarifies the diagnosis.

When considering **therapy** should be remembered that varicose veins of other origins mainly of the saphenous arches mostly accompany this pathology.

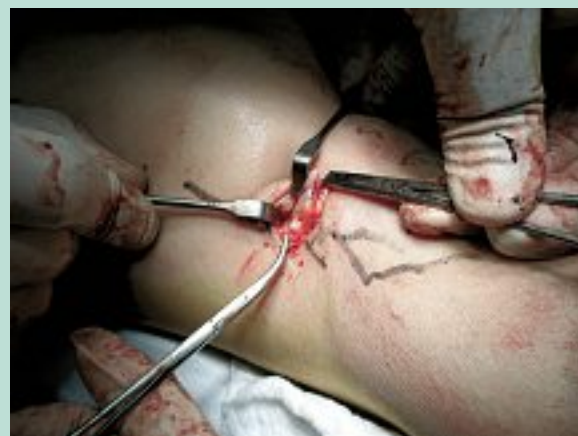In isolation, is generally not severe at all.

**Determining factors** that should be considered for surgical indication are: age of patients, association with disease of greater importance, and the speed of growth over time and aesthetics.

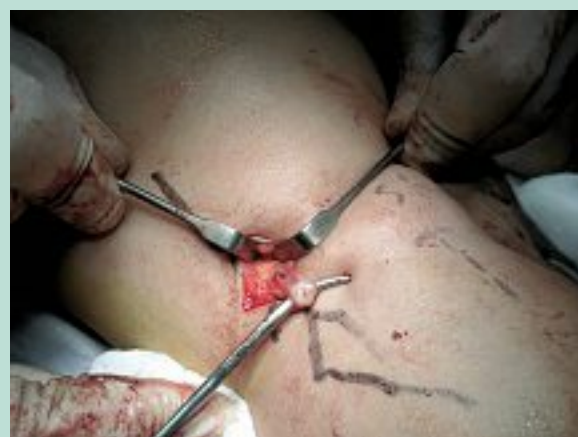**Sclerotherapy and further echo-guided one**, is an important alternative, but not without risks.

The depth of the vein below the upper angle of the popliteal fossa can enable the puncture of the nerve during maneuvers, especially when Doppler ultrasound is not sufficiently clear [8].

In addition, as highlighted by **Nicos Labropoulos** [6] the vein may take the form of perinervous plexus even within or closely related to the epineurium, which would cause an inflammatory reaction of the nerve of varied magnitude and duration.



**FIGURE 8 :** Varicose veins of the sciatic nerve separated from the nerve.



**FIGURE 9 :** Varicose veins of the sciatic nerve. On the right small saphenous vein marked.

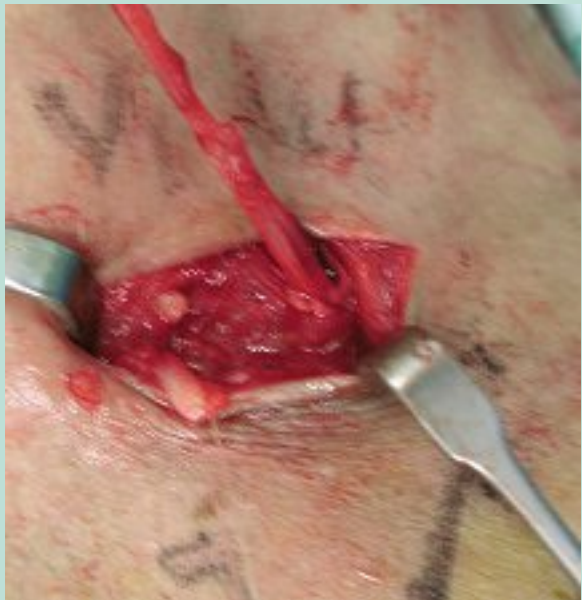Also in the tibial nerve veins, as continuation of the internal sciatic popliteal, sclerotherapy is risky in the area that lies between the external saphenous and the popliteal vein, either by direct injury or inflammatory spread.

More safe, though less effective, is sclerotherapy of the supra-aponeurotic veins. The most desirable product is the 1% sodium tetradecyl sulfate. This procedure was used in 8 cases in our series without consequences.

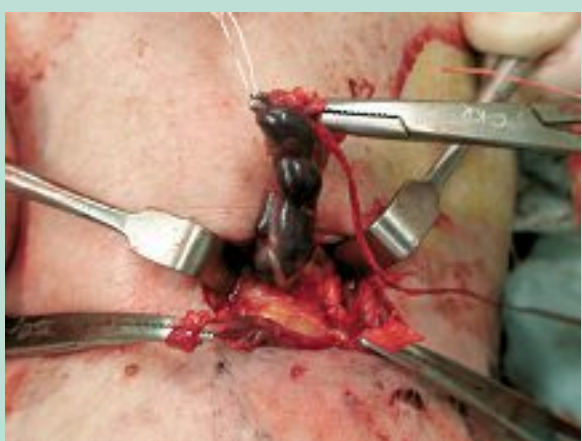**The indicated surgery** consists in ligation and section of the sciatic vein as high as possible in the popliteal fossa under Doppler ultrasound monitoring with extreme care to avoid traction injury of the nerves. It is known the extreme lability of external sciatic popliteal nerve. (**Figure 7, Figure 8, Figure 9 and Figure 10**).

At supra-aponeurotic level, **superficial phlebectomies** are appropriate choices.

Varicose veins of external popliteal sciatic nerve.



**FIGURE 10 :** Left small saphenous vein and right varicose veins of the sciatic nerve.



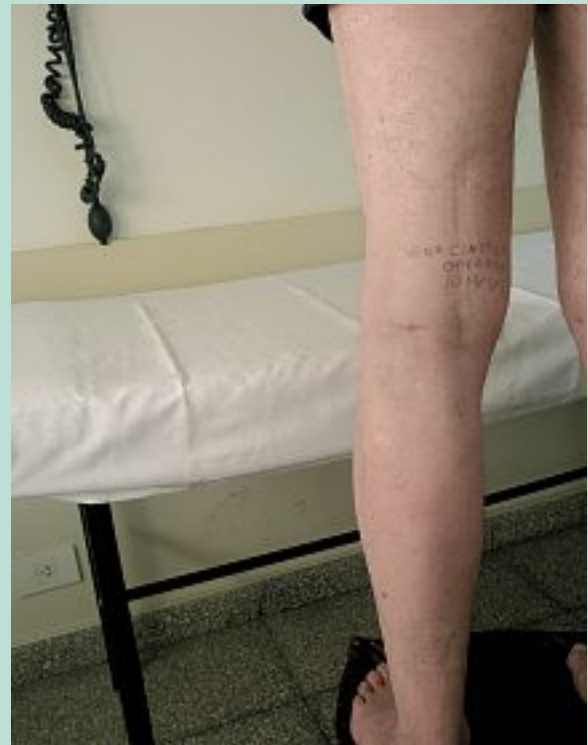**FIGURE 11 :** Extirpation of sciatic vein.

Care must be taken in the therapy of the branch around the fibular head to avoid injury to the peroneal sheath of the external popliteal sciatic.

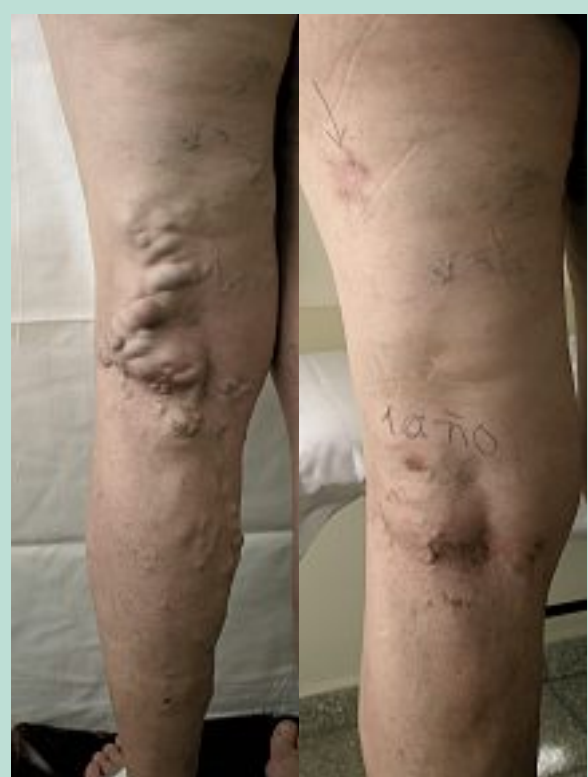**Ligation and section of the vein** added to superficial phlebectomies bring excellent results (**Figure 11**, **Figure 12** and **Figure 13**).

In our series of 11 cases with this procedure, a temporary paresis of an external popliteal sciatic nerve was recorded, which was afterwards explored surgically, noting its indemnity and response to electrical stimulation.

Facing reflux as consequence of insufficiency of inferior ischial or gluteal veins a selective embolization according to the magnitude can be proposed.



**FIGURE 12 :** Postoperative of 10 months.



**FIGURE 13 :** Varicose veins of the sciatic nerve. Pre and postoperative of 1 year.

## Conclusions

Varicose veins of external popliteal sciatic nerve constitute a clinical entity perfectly distinguishable from persistence of the embryonic sciatic vein.

Clinical and Doppler ultrasound allow a certain diagnosis and a scheduled treatment.

According to the size and age, surgery is the therapy of choice; sclerotherapy may also be an alternative.

## References

1. Van der Stricht J. Varices du nerf sciatique. *Phlébologie* 1999 ; 52, 3 : 349-50.
2. Lesmale P. De la clinique aux ultrasons : varicose du nerf sciatique. *Phlébologie* 2003 ; 56, 1 : 67-8.
3. Ricci S. Observation ultrasonique du nerf sciatique et de ses branches de la fosse poplitée : toujours visible, jamais observé. *Phlébologie* 2005 ; 58, 2 : 197-202.
4. Lesmale P., Uhl J., Lefebvre-Vilardebo M., Guillot C., Baud J., Vin F. Veine du nerf sciatique et maladie variqueuse. Aspects écho-anatomiques et hémodynamiques. *Phlébologie* 2001 ; 54, 2 : 219-28.
5. Pozzi J. Varices de la région poplitée : diagnostic, traitement, expérience. *Corpus Ed.* 1<sup>o</sup> Edición, 31-34-44-48-50-58.
6. Labropoulos N., Tassiopoulos A., Gasparis A., Phillips B., Pappas P. Veins along the course of the sciatic nerve. *J. Vasc. Surg.* 2009 ; 49 : 690-6.
7. Parry D., Aldoori M., Hammoud R., Kessel D., Westin M. Persistent sciatic vessel, varicose veins and lower limbs hypertrophy an unusual case of discrete clinical syndrome? *J. Vasc. Surg.* 2008 ; 36, 2 : 386-400.
8. Hill D. Nerve injury associated with sclerotherapy. *Phlébologie* 2010 ; 63 : 55-7.
9. Byung-Boong Lee. Venous embryology: the key to understanding anomalous venous conditions. *Phlebology* 2012 ; 19, 4 : 170-2.
10. Seung Chai Yung, Whal Lee, Jin Wook Jae, Eun-An Park, Kwang Nam Jim, Cheong-II Shain, Joe Hyung Park. Unusual cases of a varicose vein in the lower extremities: CT venography and Doppler US findings. *RadioGraphics* 2009 ; 29 : 525-36.
11. Cherry K., Gloviczki P., Stanton A. Persistent sciatic vein: Diagnosis and treatment of a rare condition. *J. Vasc. Surg.* 1996 ; 23, 3 : 490-7.
12. Trigaux J.P. Sciatic venous drainage demonstrated by varicography in patients with patent deep venous system. *Cardiovasc. Interv. Radiol.* 1989 ; 12 : 103-6.
13. Verneuil A. *Traité de chirurgie de Duplay et Reclus.* Paris 1890 ; Tome II 221. Cited by Van der Stricht J.