



Effects of medical compression stockings on epi-fascial veins: their applications to foam sclerotherapy.

Effets des bas médicaux de compression sur les veines épi-fasciales et leurs conséquences sur la sclérothérapie à la mousse.

Rastel D.¹, Lun B.²

Summary

Objectives: Medical compression stockings are recommended following sclerotherapy. Nevertheless, the question of its effect either in reducing side effects or in improving results remains to be clarified. Reduction of micro-thrombectomies following spider or reticular vein injections was shown. However no effect was demonstrated following saphenous veins sclerotherapy. The objective of this trial was to study the morphology of superficial veins under compression stockings to try to explain this difference.

Superficial veins were studied using ultra-sounds in the absence or and through medical compression stockings (MCS).

Material and method: Five varicose vein areas in two volunteers with superficial venous insufficiency (C2EPAsPR) were studied.

The patients were in standing position with one leg placed in a windowed box filled with water to prevent direct contact between the skin and the probe.

MCS pressure was 20 mmHg (MCS of French Class 2, Sigvaris®) at the varicose vein areas.

The curvature radius of the skin deformation due to varicosis, the sections and surfaces of the epi-fascial and saphenous veins were measured. Two operators using software on Matlab analysed images. The medians were compared.

Results: Median curvature radius of skin due to varicose epi-fascial veins was increased under MCS ($p = 0.0001$). The area of pathologic epi-fascial veins was reduced ($p = 0.018$). There was no variation in morphology of the incompetent saphenous veins ($p = 0.190$).

The skin curvature due to varicosis diminished more than epi-fascial veins diameters.

Résumé

Objectifs : Le rôle des bas médicaux de compression (BMC) utilisés en post-sclérothérapie soit pour réduire les effets secondaires soit pour en améliorer l'efficacité est débattu. La littérature montre une réduction du nombre de micro-thrombectomies sur certaines veines épi-faciales. En revanche les BMC n'auraient aucun effet sur les veines grandes saphènes. L'objectif de ce travail est d'étudier le comportement des veines épi- et sous-faciales sous compression pour tenter d'expliquer ces divergences.

Matériel et méthode : Les veines du plan cutané ont été étudiées par échographie mode B sous BMC au niveau de 5 zones de varices jambières chez deux volontaires avec insuffisance veineuse superficielle notée C2EPAsPR, en position debout. Un dispositif spécifique a été mis au point pour pallier à tout biais lié à la pression de la sonde sur la peau. Un BMC de classe 2 déjà commercialisé (Sigvaris®), a été utilisé. Le rayon de courbure local du plan cutané en regard des varices, les sections intraluminales des veines ont été mesurées par traitement d'image numérique, par deux opérateurs, les surfaces furent calculées puis les médianes comparées.

Résultats : Le rayon de courbure médian de la peau en regard des veines pathologiques épi-faciales est augmenté ($p = 0,0001$) sous compression, la section des veines est diminuée ($p = 0,018$). Il n'y a pas de variation significative des paramètres en ce qui concerne les veines dans les compartiments saphéniens ($p = 0,190$).

Les veines épi-faciales modifient donc peu leur forme et moins que la courbure de la peau due à la veine variqueuse qui s'efface sous compression. Aux pressions exercées la section des veines sous-faciales n'est pas modifiée par les BMC.

1. Rastel D., médecine vasculaire, SELURL Philangio, 30, place Louis-Jouvet, 38100 Grenoble, France.
E-mail : d.rastel@wanadoo.fr – Fax : 04 76 24 02 38. Tel : 06 83 70 72 19.

2. Lun B., Service de recherche appliquée, Sigvaris, Saint-Just Saint-Rambert, France.

Accepté le 13 novembre 2013

Effects of medical compression stockings on epi-fascial veins: their applications to foam sclerotherapy.

❖❖❖ **Conclusion:** We postulate that MCS act mainly by pressing epi-fascial varicose veins into the skin, with little deformation, increasing extra vascular pressure and so create what could be a protective environment to epi-fascial veins which was not necessary in the case for saphenous veins already located in their saphenous compartment.

Keywords: *compression therapy, sclerotherapy.*

❖❖❖ **Conclusion :** *Les varices de tributaires saphène, sous l'effet des BMC de classe 2, se déforment peu, sans écrasement, et s'enfoncent dans le plan cutané. Il n'y a pas de modification morphologique des grandes saphènes. Une augmentation de la pression extra-vasculaire est donc la conséquence ce qui équivaudrait à créer un effet compartiment pouvant réduire les effets secondaires de la sclérothérapie des veines épi-fasciales.*

Mot-clés : *compression médicale, sclérothérapie.*

Introduction

Foam sclerotherapy is one of the major treatments of superficial venous disorders with results probably as good as surgery, laser or radiofrequency procedures [1, 2].

The results of foam sclerotherapy published in the literature are related mainly to treatment of the great saphenous veins and less to the tributaries [3, 4]. However, leg varicosis associated (or not) with saphenous incompetency is the most frequent pattern seen in our consultations [5].

Moreover, foam sclerotherapy is an ambulatory technique with a low rate of side-effects in experienced hands and any side-effects, when they occur, are generally not severe [6, 7].

Thus, the use of medical compression stockings seems in this case of little value in the short term. It does not improve the occlusion rate of saphenous trunks, which is already high, and does not reduce side effects, which are already very low [8].

Conversely, it could reduce the number of sessions of injections and for reticular veins and telangiectasias, compression therapy seems to improve results and reduce the number of micro-thrombectomies [9, 10].

Hence, compression therapy is recommended following foam injection but with benefit that is matter of debate due to the fact that compression therapy, although without any severe side-effects, is often not well tolerated [11].

Above all, the physical effects of compression therapy on superficial veins remain to be understood.

The present test aims to study superficial veins, mainly epi-fascial veins, and their behaviour under compression and thus to endeavour to explain how compression could act following sclerotherapy, which has never yet been done.

Material and methods

The objective of this study was to evaluate the variation of the morphology of incompetent superficial veins of the lower limbs during the application of medical compression stockings with calibrated pressure.

The main investigated criteria were the variations of the curvature radius of the skin deformed by the varicosis and the intra-venous sections and the area of epi-fascials and sub-fascials of incompetent superficial veins.

The effects of medical compression stockings (MCS) on the veins were studied directly through the applied stockings by ultrasound examination using a ultra-sound probe of 12 to 15 MHz (LA435 probe, ESAOTE MyLab25 Gold device).

The veins that were studied were located at different points of the leg. Volunteers were in a standing position (the position of the vein is therefore influenced by gravity) and legs were placed in a special designed device shaped in the form of a boot and filled with water (**Figure 1**).



FIGURE 1 : *Device with apertures filled with water.*

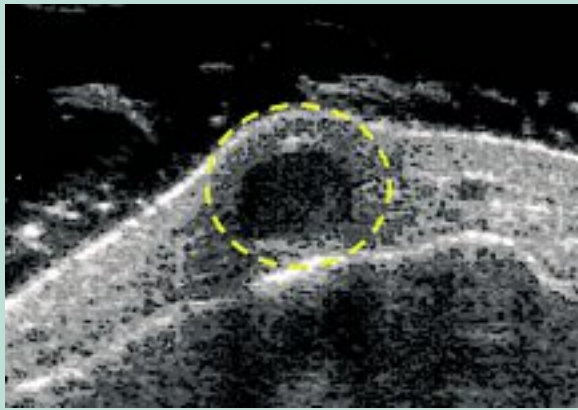


FIGURE 2 : Curvature radius of the varicose vein.

At specific areas in “the boot” a flexible membrane is mounted on its rigid plastic and transparent walls. By placing the probe against the flexible membrane the evaluation of the superficial vein anatomy – in the vertical position – is thus possible without artefact as the applied ultrasound can be transmitted to the skin *via* the membrane and water.

The pressure of the probe on the skin (a non neglectable source of artefact) is consequently avoided.

The immersed limb experiences hydraulic pressure due to water depth, which is taken into account to determine the effective external pressure on the skin.

Commercially available MCS (Diaphane[®], manufactured by Sigvaris, Saint-Just Saint-Rambert, France) of French class 2 (defined according to French standard AFNOR G 30102 B) were chosen, pressures at the ankle ranged from 15 mmHg to 20 mmHg (19.9 hPa to 26.6 hPa).

5 varicose vein areas (varicose vein caliber greater than 3 mm) related to incompetent tributaries (termed as epi-fascial veins) of the great saphenous veins (GSV) were studied on three different lower legs of two volunteers who gave their informed consent.

Moreover, one incompetent GSV (reflux more than 0.5 s) was also studied at the same leg level. Volunteers were classified according to CEAP classification in C2sEpRAs.

Cross sections and curvature radii were measured (**Figure 2**).

To ensure that the measuring point is always at the same location, plastic strips were stuck on the skin (**Figure 3**).

Curvature radius and cross sections (ratio R/r) were measured using a MATLAB[®] program. Area was calculated for each of the varicose vein cross section. Statistical analysis was performed using XLStatR software. Medians were compared using a student t test and a difference was stated at a 95% IC (p value ≤ 0.05).

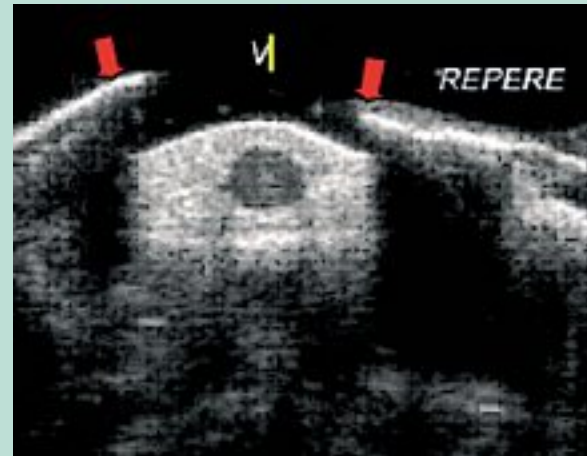


FIGURE 3 : Thin plastic strip adhered to the skin to localize precisely the measuring point.

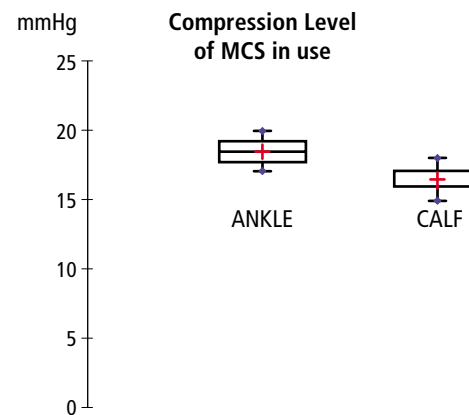


FIGURE 4 : Pressure of the compression stockings at various locations. Median, range (in blue), 25-95% (black box).

Results

Ankle and calf pressures applied by the MCS were in the range of 15 mmHg to 20 mmHg. The pressure under the MCS on the areas were incompetent veins were studied, had a median pressure of 20 mmHg \pm 3 mmHg depending on the curvature radius at the level of the varicosis (**Figure 4**).

The diameters of the epi-fascial veins examined ranged between 2 mm to 3 mm without and under compression. Since for each varicose area similar behaviour was observed, the overall data were plotted together for each parameter.

Effects of medical compression stockings on epi-fascial veins: their applications to foam sclerotherapy.

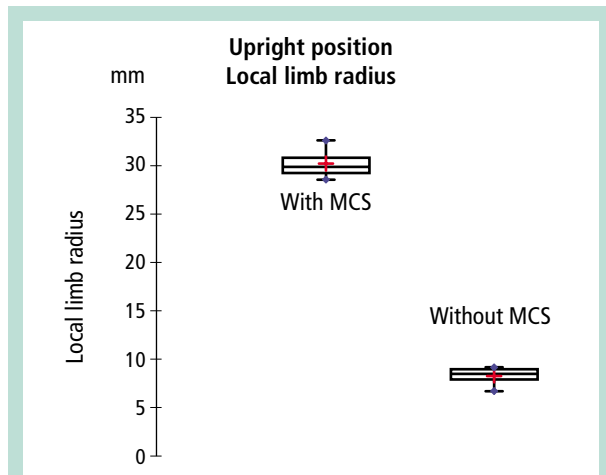


FIGURE 5 : Local limb curvature radius of the varicose veins with and without medical compression stockings.

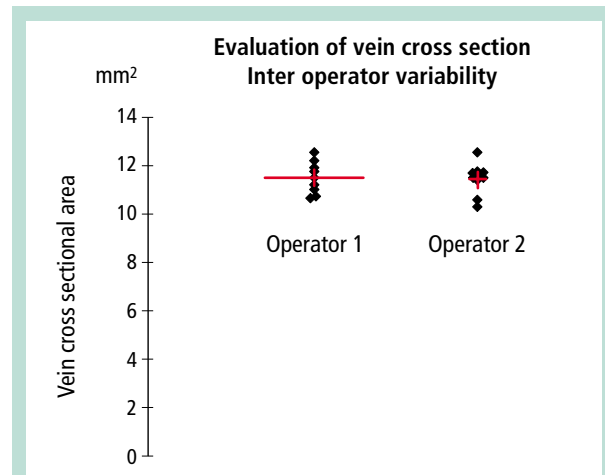


FIGURE 6 : Measurement of vein diameter, between operator variability (p = 0.80).

Median curvature radius of epi-fascial veins without compression is 8.6 mm ± 2.1 mm, for a patient in a standing position and 29.9 mm ± 3.5 mm with compression stockings (Figure 5). There is a difference with a p value of 0.0001.

Median area of epi-fascial veins without compression stocking and for a patient standing is 31.5 mm² ± 1.4 mm². Under compression stockings the median area of epi-fascial veins is 26.9 mm² ± 1.5 mm². There is a difference with a p value of 0.018.

Median area of fascial veins (great saphenous vein) without any compression stocking and for a patient standing is 11.85 mm² ± 1.02 mm² and 14.2 mm² ± 3.53 mm² under compression stockings. There is no significant difference with a p value of 0.19 (Table 1).

The investigator variability in measuring vein section is negligible with a p of 0,80 (Figure 6).

Discussion

Compression therapy is recommended after liquid or foam sclerotherapy procedures by both the relevant European recommendations (grade 2C) and the French recommendations and the range of recommended pressure should be between 23 to 33 mmHg for telangiectasias, and between 15 to 46 mmHg for other superficial veins [1, 12].

It is simply a practitioners agreement since there is little scientific evidence in favor of transitory or long term wearing of medical compression after foam or liquid injections.

It is however expected that compression therapy following sclerotherapy could either:

- reduce the superficial or deep venous thrombosis risk
- reduce pain or drug prescriptions
- reduce adverse cutaneous effects
- reduce the thrombectomy rate
- or improve results by eliminating vein dilation, varicosis, and reflux (increasing the length of occluded vein)
- reduce the number of sessions to achieve treatment
- reduce the time to transform sclerus to fibrous vein and of course fulfill patient expectations.

The effects of compression therapy following sclerotherapy are in fact controversial.

Two major trials have shown opposite results [3, 10]. Both studies target superficial veins but do not test the same veins.

Positive results (reduction of side-effects and improvement of visual aspects) are reported for the treatment of epi-fascial veins and no effects are reported for saphenous trunks foam injections either in improving results or reducing adverse effects. There is, at this time, no explanation and more recent results are puzzling [9].

		Without MCS	MCS	p
Epi-fascial vein	Curvature radius (mm)	8.6	29.9	0.0001
	Area (mm²)	31.5	26.9	0.018
Great saphenous vein	Area (mm²)	12.7	14.2	0.19

TABLE 1 : Curvature radius and area of epi-fascial varicose veins without and with compression stockings at 20 mmHg of local pressure. Values for the great saphenous vein surface at a similar pressure.

First indications are appearing from the published trials on sclerotherapy: regarding saphenous trunks short term results for foam sclerotherapy are very good, thus, it seems of little interest to additionally use compression therapy or any other therapy to improve results on immediate occlusion rate.

On a similar point, side effects are at a very low level and when they occur most are not severe when superficial (at the skin level). When severe it is mainly thrombosis and, very rarely, arterial injections.

And perhaps the recommendation to use compression therapy in foam sclerotherapy is in fact mainly linked to the fear of deep vein thrombosis and pulmonary embolism occurrences.

To use compression therapy to reduce this low risk could be an interesting and worthwhile objective but the trial that would be required to prove it would require a considerable investment in time and number of patients.

There remains the possible reduction of side effects when sclerotherapy is used for varicosis of tributaries, for which the aesthetic aspects are often motivated by patient expectancy, or sclerotherapy is used by young and/or poorly trained phlebologists.

In the former case, the reduction of the level of micro-thrombectomies following sclerotherapy of spider and reticular veins appears to be achieved by compression.

However the published results use MCS with strong pressure (30 mmHg at the ankle) and the compression must be worn over a long time (3 weeks). It is understandable that phlebologists are reluctant to apply such a therapy if it is not confirmed by strong evidence: "adherent patient is a convinced physician".

Moreover we cannot forget that the most frequent pattern that phlebologists deal with every day is varicosis and not saphenous incompetence [5].

On the other hand how the compression works is still a matter of debate and basically the haemodynamic effect is the major expected effect.

It is stated by up to date experts, that narrowing the veins is the mandatory pre-requisite for haemodynamic changes, whereas for other physicians, the objective is to re-equilibrate the trans-mural pressure, with or without narrowing the veins [13, 14].

Nevertheless, it has been shown using an indirect method that only pressure superior than 60 mmHg could narrow the saphenous vein (using a device which is a compromise between Laplacian and fluid pressures and do not use compression stockings) but no direct reliable data exists for epifascial veins [15].

The results demonstrate that using a moderate pressure of 20 mmHg neither the epi-fascial nor the saphenous veins reduce significantly their caliber.

Demonstrated here, but daily visually observed by any phlebologists, the dilation of the skin due to varicose of saphenous tributaries disappears when a MCS of 20 mmHg is applied against the dilation. This means that even without any reduction in caliber there is an effect. The dilated epi-fascial veins sink in the cutaneous tissues and, since the muscle fascia does not change its morphology, the consequence is an increase in the external pressure which plays a direct role in the transmural pressure equilibrium.

The dilated epifascial veins are again totally included in the skin tissue whose physical characteristics are known. It was recently shown by modeling the vein behaviour, and thus mechanically explaining it, that the external pressure is modified differently on epifascial thus on saphenous veins, less affected in the latter case [16]. The major subcutis component involved in this pressure change is the fat tissue whose behaviour is modified by the compression [16].

The behaviour of the vein depends also on its location (near or far from the bones,...), the patients, resting or walking, cutaneous thickness, curvature radius of the different parts of the limb, compliance to treatment and less on material [17]. In this situation the venous hypertension at the vein wall is reduced and the external pressure at which the epi-fascial veins are subjected under the compression stockings is closer to the pressure surrounding the saphenous veins.

The results presented here can give explanations to the debate and bring data to strengthen the case for the use of compression following sclerotherapy of epi-fascial veins.

Varicose of tributaries is the medical profile that we meet with every day and whose disappearance is the patient expected end-point. Compression therapy of tributaries treated by foam sclerotherapy should be recommended and pressure should be at the same level at each treated point and 20 mmHg seems a good compromise that future studies should investigate to demonstrate its efficacy.

Conclusion

The effect of compression following sclerotherapy of varicose veins is still matter of debate. At a pressure of 20 mmHg medical compression stockings do not reduce significantly the caliber of varicosis but increase the external pressure reducing subsequently the transmural pressure of vein walls. This effect could play a protective role against the side effects of sclerotherapy. It is a possible explanation of the positive results from post-sclerotherapy compression of telangiectasias and an explanation of the lack of positive effect of compression following sclerotherapy of saphenous veins, that are already "protected" by the surrounding saphenous compartment.

The use of MCS following foam sclerotherapy of epifascial veins is recommended.

Thanks to Dr Claudine Gehin and Dr Eric McAdams (INSA Lyon) for their comments and English corrections.

Effects of medical compression stockings on epi-fascial veins: their applications to foam sclerotherapy.

References

1. Rabe E., Breu F., Cavezzi A., Smith PC., Frullini A., Gillet J., Guex J., Hamel-Desnos C., Kern P., Partsch B., Ramelet A., Tessari L., Pannier F.; for the Guideline Group. European guidelines for sclerotherapy in chronic venous disorders. *Phlebology* 2013 ; Apr 4. [Epub ahead of print].
2. Coleridge Smith P. Sclerotherapy and foam sclerotherapy for varicose veins. *Phlebology* 2009 ; 24 : 260-9.
3. Hamel-Desnos C., Ouvry P., Benigni J-P., Boitelle G., Schadeck M., Desnos P., Allaert F-A. Comparison of 1% and 3% Polidocanol foam in Ultrasound guided sclerotherapy of the Great Saphenous Vein: a randomised, Double-blind Trial with 2 Year-follow-up. The 3/1 Study. *Eur. J. Vasc. Endovasc. Surg.* 2007 ; 34(4) : 180-9.
4. Rabbe E., Otto J., Schliephake D., Pannier F. Efficacy and safety of great saphenous vein sclerotherapy using standardized polidocanol foam (ESAF): a randomized controlled multicenter clinical trial. *Eur. J. Vasc. Surg.* 2008 ; 8 : 940-6.
5. Labropoulos N., Kokkosis A.A., Spentzouris G., Gasparis A.P., Tassiopoulos A.K. The distribution and significance of varicosities in the saphenous trunks. *J. Vasc. Surg.* 2010 ; 51(1) : 96-103.
6. Guex J.J., Allaert F.A., Gillet J.L., Chleir F. Immediate and midterm complications of sclerotherapy: report of a prospective multicenter registry of 12,173 sclerotherapy sessions. *Dermatol. Surg.* 2005 ; 31(2) : 123-8.
7. Gillet J.L., Guedes J.M., Guex J.J., Hamel-Desnos C., Schadeck M., Lauseker M. Side-effects and complications of foam sclerotherapy of the great and small saphenous veins: a controlled multi-center prospective study including 1025 patients. *Phlebology* 2009 ; 24 : 131-8.
8. Hamel-Desnos C., Guías B., Jousse S., Desnos P., Mesgard A. Foam sclerotherapy of the saphenous veins: randomised control trial with or without compression. *Eur. J. Vasc. Endovasc. Surg.* 2010 ; 39 : 500-7.
9. Zarca C., Bailly C., Gachet G., Spini L. ClassMousse 1 study: compression hosiery and foam Sclerotherapy. *Phlébologie* 2012 ; 65 : 11-20.
10. Kern P., Ramelet A.-A., Wütschert R., Hayoz D. Compression after sclerotherapy for telangiectasias and reticular leg veins: a randomized controlled study. *J. Vasc. Surg.* 2007 ; 45 : 1212-6.
11. Raju S., Hollis K., Neglen P. Use of compression stockings in chronic venous diseases: patient compliance and efficacy. *Ann. Vasc. Surg.* 2007 ; 21 : 790-5.
12. HAS, Haute Autorité de Santé. Dispositifs de Compression Médicale à usage individuel. Utilisation en pathologies vasculaires. Révision de la liste des produits et prestations remboursables. Service Évaluation des Dispositifs. Septembre 2010. 301 pages.
13. Partsch H., Mosti G., Mosti F. Narrowing of leg veins under compression demonstrated by magnetic resonance imaging (MRI). *Int. Angiol.* 2010 ; 29 : 408-10.
14. Franceschi C., Zamboni P. Principles of Venous Hemodynamics. Nova Biomedical. 2009.
15. Partsch B., Partsch H. Which pressure do we need to compress the great saphenous vein on the thigh? *Dermatol. Surg.* 2008 ; 34(12) : 1726-8.
16. Rohan C.P., Badel P., Lun B., Rastel D., Avril S. Biomechanical response of varicose veins to elastic compression: a numerical study. *J. Biomech.* 2013 ; 46(3) : 599-603.
17. Blättler W., Lun B., Uhl J.-F., Bringer Y. Determinants of pressure exerted by medical compression stockings. *Phlebologie* 2007 ; 36 : 237-44.