



New concepts on recurrence of varicose veins according to the different treatment techniques.

Nouveaux concepts dans les récïdïves en fonction des différentes techniques de traitement des varices.

De Maeseneer M.G.R.^{1,2}, Biemans A.A.¹, Pichot O.³

Summary

Recurrent varicose veins remain a common problem after varicose vein treatment. Several etiologies have been recognized: tactical and technical failure, neovascularisation, and recanalisation of a previously obliterated trunk and progression of the disease.

With the widespread use of duplex ultrasound and increasing experience in the field of ultrasound-guided procedures, the impact of both **tactical and technical failure** is likely to diminish.

However this issue still needs our attention, as it may induce early recurrence after all types of intervention. Another etiologic factor is **neovascularisation**, occurring in particular after surgery at the level of the saphenofemoral junction (SFJ) or saphenopopliteal junction (SPJ).

To explain recurrence after endovenous ablation (EVA) the focus has rather been on **recanalisation** of a previously obliterated trunk. It is well known that such recanalisation occurs more frequently after chemical ablation with sclerosant foam than after thermal ablation.

The incidence of neovascularisation at the SFJ or SPJ is much lower after EVA than after surgical procedures. However this does not mean that the junctions are never involved in recurrence after EVA. It is therefore also important to follow the evolution at the level of the SFJ or SPJ by means of duplex ultrasound, as new (or persistent) reflux may be detected sonographically.

Progression of the disease cannot be avoided and is an important contributory factor in the pathophysiology of recurrence at long term. Apart from genetic factors, other patient-related factors (BMI \geq 30, pregnancy after the intervention...) have been claimed to be responsible for progression of the disease and hence recurrence.

Résumé

Les récïdïves de varices post-thérapeutiques sont un problème commun. Diverses étiologies ont été reconnues : défaillance tactique et technique, néo-vascularisation et recanalisation d'une oblitération tronculaire antérieure, ainsi que progression de la maladie.

*Avec l'utilisation généralisée de l'écho-Doppler et l'expérience accrue dans le domaine des procédures guidées par ultrasons, il est vraisemblable que l'impact de la **défaillance tactique et technique** diminue.*

*Cette question nécessite toutefois que nous y prêtions attention, puisqu'elle peut induire des récïdïves précoces, à la suite de tous les types d'interventions. Un autre facteur étiologique est la **néo-vascularisation**, qui survient en particulier à la suite d'une chirurgie au niveau de jonction saphéno-fémorale (JSF) ou de la jonction saphéno-poplitée (JSP).*

*Afin d'expliquer la récïdïve suivant une ablation endoveineuse (AEV), l'accent a plutôt été mis sur la **recanalisation** d'une oblitération tronculaire antérieure. Il est bien connu que la dite recanalisation a le plus souvent lieu à la suite d'une ablation chimique avec une mousse sclérosante, plutôt qu'après une ablation thermique.*

L'incidence de la néo-vascularisation au niveau de la JSP ou de la JSF est nettement moindre après AEV, qui est bien plus fréquente à la suite des procédures chirurgicales. Toutefois, cela ne signifie pas que les jonctions ne soient jamais impliquées dans la récïdïve suivant une AEV. Il est par conséquent également important de suivre l'évolution au niveau de la JSF ou de la JSP, au moyen d'un écho doppler, puisqu'un reflux nouveau (ou persistant) peut se révéler par cet examen.

*La **progression de la maladie** ne peut pas être évitée et elle constitue un facteur important dans la pathophysiology des récïdïves à long terme. Outre les facteurs génétiques, d'autres facteurs liés au patient (IMC \geq 30, grossesse après la chirurgie...) ont été accusés d'être responsables de la progression de la maladie et donc de la récïdïve.*

Presented at the Congrès national de la Société Française de Phlébologie in Paris, 8 December 2012.

1. Department of Dermatology, Erasmus Medical Centre, PB 2040, 3000 CA Rotterdam, Netherlands.

2. Faculty of Medicine and Health Sciences, University of Antwerp, Antwerp, Belgium.

3. Department of Vascular Medicine, Department of Vascular Surgery, CHU Grenoble, France.

E-mail: m.demaeseneer@erasmusmc.nl – marianne.demaeseneer@uantwerpen.be

Accepted on July 28th, 2013

New concepts on recurrence of varicose veins according to the different treatment techniques.

Due to disease progression after several years, tortuous neovascular veins or (newly) refluxing veins at the junction may connect with superficial varicose veins of the thigh or leg, acting as a 'joint venture' and in this way lead to the clinical situation of a full-blown recurrence of varicose veins.

To increase our understanding of varicose vein recurrence, future studies are needed, including adequate preoperative duplex ultrasound investigation and long-term follow-up with serial duplex scans, after different forms of varicose vein treatment.

Keywords: varicose veins, recurrence, pathophysiology.

En raison de la progression de la maladie après plusieurs années, des néo-réseaux veineux tortueux ou de nouveaux reflux veineux jonctionnels peuvent se connecter avec des varices superficielles de la cuisse ou de la jambe, agissant comme une «joint-venture» et peuvent de cette manière conduire à la situation clinique d'une récurrence à part entière de varices.

Afin d'accroître notre compréhension de la récurrence variqueuse, des études nouvelles sont nécessaires, incluant une exploration et un suivi répété au long cours par des examens écho-doppler adéquats préopératoire et postopératoires, suivant les différentes modalités de traitement des varices.

Mots-clés : varices, récurrence, pathologie.

Introduction

Recurrent varicose veins remain a common problem. It has been extensively studied after surgical treatment of varicose veins, but is now also increasingly encountered in patients treated with endovenous techniques (**Figure 1**).

After surgery the incidence of clinical recurrence after 5 years is estimated to be between 25 and 50% according to prospective studies [1, 2].

After endovenous thermal ablation (EVTA) the 5 years incidence of recurrence is less well documented so far, as studies with long term follow-up are still scarce. After treatment of the great saphenous vein (GSV) with radiofrequency, using the Closure Plus® system, Merchant et al. [3] reported an incidence of 27% of varicose vein recurrence after 5 yrs.

According to the 3-year results after treatment with radiofrequency powered segmental ablation (Closure Fast®), the incidence of recurrent varicose veins was 33% [4].

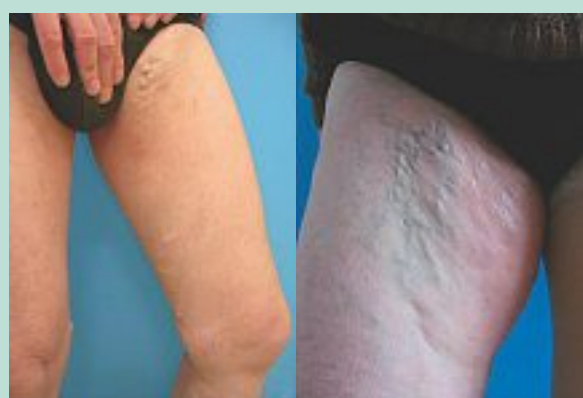

FIGURE 1 : Similar clinical appearance of recurrence 5 years after surgery (left) and 5 years after endovenous laser ablation (right).

Five years after endovenous laser ablation, recurrent varicose veins were present in 31% of limbs treated without SFJ ligation and in 49% of those treated with additional high ligation [5].

Finally, although occlusion rates seem to be inferior after ultrasound guided foam sclerotherapy (UGFS), clinical results are very comparable to those of surgery and EVTA, at least at short- and mid-term follow-up, according to recently published randomised controlled trials [6, 7].

Five year results of these ongoing trials, including those after UGFS, are still awaited. In summary, the available data illustrate that clinical reappearance of varicose veins definitely remains a problem after whatever technique used for primary treatment of patients suffering from varicose veins (C2) with or without chronic venous insufficiency (C3-C6).

Etiology of varicose vein recurrence

Although duplex ultrasound has been introduced in phlebological practice all over the world, there may still be a problem of insufficient understanding of venous anatomy and haemodynamics, which may indeed be very complex in certain cases. This may lead to **tactical failure**. On the other hand, incorrect or insufficient surgical or endovenous intervention may lead to **technical failure**. Both tactical and technical failures are obvious causes of recurrence of varicose veins after treatment.

Neovascularisation has been extensively studied as another cause for developing recurrence.

This term describes new, usually tortuous, venous channels at the site of a previous (high) ligation e.g. between the saphenous stump on the common femoral vein (CFV) and a residual GSV, anterior accessory saphenous vein (AASV), posterior accessory saphenous vein, Giacomini vein or superficial thigh tributaries [8].

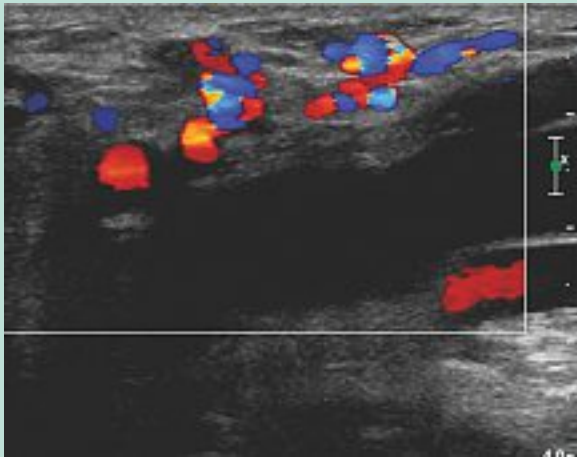


FIGURE 2 : Duplex ultrasound of the popliteal fossa. Longitudinal image. Neovascularisation at the saphenopopliteal junction after small saphenous vein surgery.

It is easily detectable by means of duplex ultrasound after an intervention for varicose veins [9].

It has mainly been studied at the saphenofemoral junction (SFJ) after GSV treatment. However it may equally be seen at the saphenopopliteal junction (SPJ) after small saphenous vein (SSV) surgery (**Figure 2**), as well as after ligation of incompetent perforating veins, or even after phlebectomies.

The term neovascularisation has now been recognized as one of the Vein Terms, and has been defined as: 'presence of multiple small tortuous veins in anatomic proximity to a previous intervention' [10].

A more purely sonographic descriptive term may be used for the typical appearance of these veins at duplex ultrasound, namely 'groin varicose network' at the SFJ or 'popliteal fossa varicose network' at the SPJ [9].

Neovascularisation can also be observed after surgery in the strip track. It appears as a single usually very tortuous refluxing vessel in the saphenous compartment (**Figure 3**). In such case, the source of reflux is usually a persisting incompetent junction, an incompetent perforating vein, or incompetent tributaries draining into the tortuous vein.

Recanalisation of the ablated trunk (after initial obliteration) is a specific concern after endovenous thermal or chemical ablation. Duplex ultrasound then reveals partial or complete reopening of the trunk, with or without reflux (**Figure 4**) [9].

There may be a connection with a persisting incompetence of the SFJ terminal valve or of the SPJ, an incompetent perforating vein, or tributaries with or without reflux.

Finally, the most important cause of recurrence is **progression of the disease**. One should never forget that superficial venous disease is a chronic condition, which tends to progress over time.

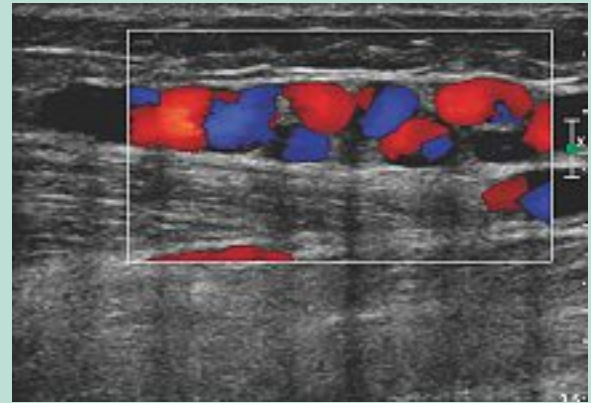


FIGURE 3 : Duplex ultrasound of the posterior calf (longitudinal image). Neovascularisation in the strip track of the small saphenous vein, 7 years after stripping.

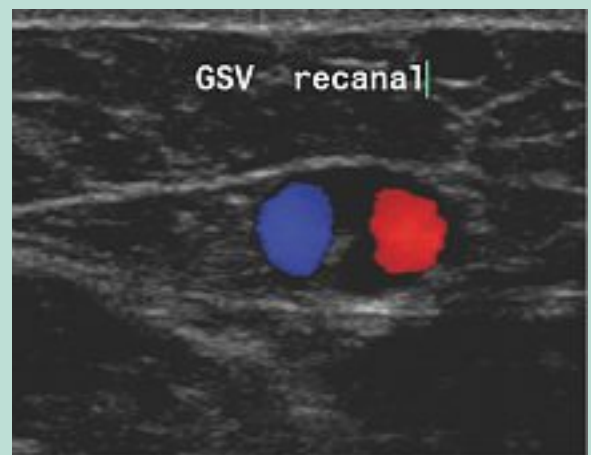

FIGURE 4 : Duplex ultrasound of the great saphenous vein 10 cm under the saphenofemoral junction (transverse image). Recanalisation with 2 tortuous channels 3 years after endovenous laser ablation.

This means that after an intervention, other previously unaffected superficial veins or perforating veins may become incompetent and truncal reflux may extend to a previously competent segment.

In some cases abdomino-pelvic venous insufficiency may also play a role in progression of the disease [11].

Other underlying genetic and constitutional risk factors for disease progression are poorly understood up until now. It is generally accepted that there is a strong family predisposition, not only for having varicose veins but also for developing recurrence.

The exact nature of the genetic basis for this family predisposition, however, is far from clear. To shed more light on this issue, it will not be sufficient to study single genes, potentially implicated in venous disease.

New concepts on recurrence of varicose veins according to the different treatment techniques.

Instead, genome wide association studies will be needed using very large sample sizes, to further unravel the genetic basis of chronic venous disorders [12].

Several constitutional risk factors, which could possibly enhance the tendency for developing varicose vein recurrence, have been recognized, such as female gender, left sided disease, obesity, multiple pregnancies and subsequent pregnancies after initial treatment, severe chronic venous disease (C4-C6 of the CEAP classification), and associated deep vein incompetence [13].

Pathophysiologic mechanisms

Tactical and technical failure

The pathophysiology of varicose vein recurrence due to tactical and technical failure is rather obvious. If treatment has been incorrect or incomplete, incompetence may persist which may lead to early clinical recurrence.

If incompetence persists at the SFJ, the 'pathway' of reflux may typically run through the residual AASV, from the SFJ to mid thigh, and then further down, presenting as recurrent varicosities on the anterior thigh and leg. This case can occur after surgery but more typically after endovenous ablation.

If only the refluxing GSV has been ablated, and a large refluxing AASV has been left untreated, reflux can persist in the incompetent SFJ and AASV. This may occur even after correct position of the tip of the thermal ablation device during the initial procedure, as the AASV usually joins the SFJ only cranially from the highest point of ablation. Therefore, if both GSV and AASV are large and refluxing, it is wise to ablate both at once.

Neovascularisation

After a classic surgical intervention for varicose veins, the role of neovascularisation at the junction has been extensively investigated. It has been reported to account for 8 to 60% of varicose vein recurrences [2, 8, 14, 15, 16, 17].

Contrarily, after EVTA, neovascularisation at the SFJ or SPJ is a very exceptional finding, with an incidence between 0-1% and this process does not seem to play an important role in recurrence [5, 18].

After surgery including high ligation, various pathophysiologic mechanisms may be involved inducing neovascularisation: angiogenic stimulation in the stump endothelium, transnodal lymphovenous connections, dilatation of small adventitial vessels, vasa vasorum of the femoral vein, and disturbed venous drainage of the ligated tributaries of the SFJ [8, 19, 20, 21, 22].

After EVTA, physiologic drainage of abdominal and pelvic tributaries is maintained, as ablation only is started distally from the ostium of the superficial epigastric vein.

It is also possible to mimick this situation by performing a surgical intervention, consisting of ligation of the SFJ distally from the orifice of the superficial epigastric vein, instead of a 'flush' ligation at the very junction.

Pittaluga et al. [23] reported a very low rate of neovascularisation (1.8%) two years postoperatively after this kind of procedure.

Future prospective studies will be needed to further elucidate this pathophysiologic issue.

Recanalisation

After endovenous thermal or chemical ablation, recurrence is mainly due to recanalisation of the ablated trunk. Several factors may influence the rate of recanalization, such as the vein diameter and the amount of energy delivered to the vein wall.

Larger veins, treated with UGFS, tend to recanalise more easily than smaller veins [24].

After thermal ablation recanalisation may occur more easily if the vein has been treated with insufficient energy [25].

After EVTA, it has also been suggested that vasa vasorum could play a role in the recanalisation process.

Labropoulos et al. [26] described tiny arterial vessels entering the vein and postulated these could be responsible for recanalisation and recurrence. As this issue is far from clear, it would be worthwhile to investigate this further by means of detailed duplex ultrasound studies after different types of ablation procedures.

Progression of the disease

The above described underlying pathophysiologic mechanisms probably interact with progression of the disease to cause early or late recurrent varicose veins in an individual patient.

In some patients early recurrence may appear within the first year after a previous intervention, whereas it may take several years for recurrent varicose veins to develop in other patients.

Probably there is always a 'joint venture' between phenomena occurring at the junction and the presence of superficial refluxing veins in the thigh or leg (**Figure 5**).

It is not yet clearly understood why these (new) refluxing superficial veins tend to reconnect over time with those at the junction.

Probably there are some chemotactic signs involved in this reconnection process in addition to other, still to be unraveled, mechanisms.

Such a 'joint venture' can be observed after initial surgical treatment as well as after endovenous ablation:

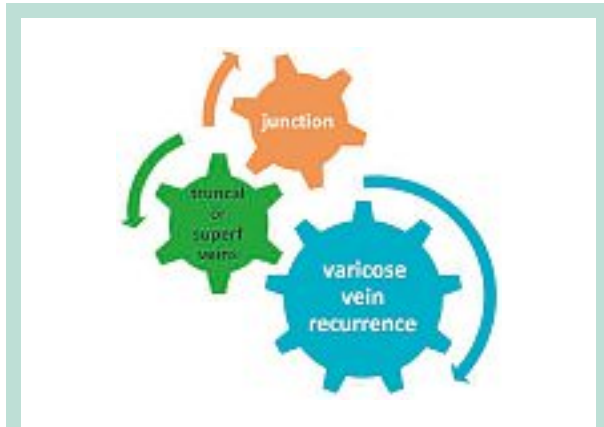

FIGURE 5 : Joint venture between phenomena at the saphenofemoral or saphenopopliteal junction and truncal or superficial veins in the periphery may lead to clinically relevant varicose vein recurrence.

Recurrence after surgical treatment

After high ligation and stripping of the GSV, recurrence can appear in the **early** postoperative stage if residual varicose veins or a refluxing GSV, anterior or posterior accessory saphenous vein, or Giacomini vein, persist.

Prompt reconnection between the latter pathologic veins and neovascular veins can be quite evident in such situation [16].

Recurrence developing **late** after surgery is more often primarily due to progression of the disease with neovascularisation playing only a secondary role in these cases. After a few years new varicose veins develop in the leg and these can connect with initially tiny neovascular veins in the groin, which at the long term can become larger and refluxing. This leads to the typical clinical presentation of thigh or whole leg varicose vein recurrence several years after surgery (**Figure 6**). In other cases, one or more perforating veins (e.g. at mid thigh) are acting as a source of reflux, due to progression of the disease.

At the level of the SPJ pathophysiology of recurrent reflux has not been studied that extensively.

If surgery has been limited to flush ligation at the SPJ – a common practice in certain countries like e.g. the Netherlands – large tortuous neovascular vessels can reconnect the SSV stump with the refluxing SSV trunk.

In such case, the refluxing SSV can be easily treated by means of EVTA or UGFS.

After initial stripping of the SSV to mid-calf level, neovascularisation at the SPJ may result in formation of new tortuous veins running from the popliteal fossa downwards, either in the saphenous compartment of the SSV (**Figure 3**) or as superficial veins in the calf.

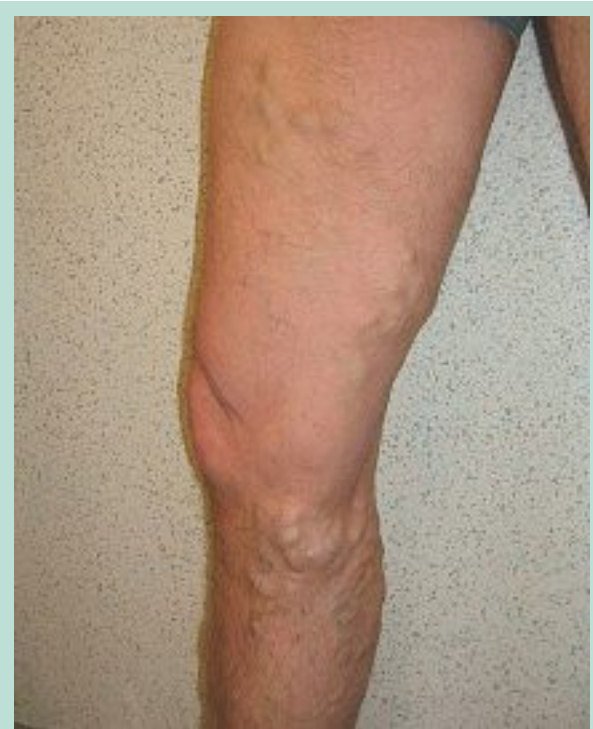

FIGURE 6 : Patient operated on 12 years earlier (high ligation and stripping of the great saphenous veins + phlebectomies) by one of the authors (MDM). Recurrent varicose veins due to neovascularisation at the saphenofemoral junction reconnecting with the anterior accessory saphenous vein and extensive varicose tributaries.

Another particular feature in the popliteal fossa is the presence of a popliteal fossa perforating vein, which is easily recognised in front of the lateral condyle of the femur and gives rise to typical tortuous veins running from the lateral popliteal fossa towards the calf [9].

This vein usually has no connection with the SSV and therefore such varicose veins may rather be related to progression of the disease after any previous treatment.

Recurrence after endovenous treatment

Similar to what can be observed after surgery, there can be interaction between recurrent or persisting reflux at the junction and superficial refluxing veins after endovenous ablation as well.

Unfortunately, in the majority of studies looking at outcome after EVTA of the GSV the fate of the SFJ is not even mentioned. Only a few randomised trials, which compare EVTA with surgery, have investigated the incidence of new reflux at the SFJ.

In the recently published German RELACS-study [27], duplex-detected reflux at the SFJ appeared to occur significantly more frequently after endovenous laser ablation (17.8%) than after high ligation and stripping (1.3%).

New concepts on recurrence of varicose veins according to the different treatment techniques.

It should be mentioned that in the surgical group a particular technique had been used to mitigate the effect of neovascularisation at the SFJ, by invaginating the GSV stump with a non-absorbable suture.

This might explain somehow why the incidence of postoperative recurrent reflux at the SFJ was so low.

Moreover, all procedures were performed under local tumescent anesthesia, which facilitates dissection at the SFJ and minimizes blood loss. It may be hypothesized that both these factors reduced surgical trauma and haematoma formation, and hence the incidence of neovascularisation [19, 27].

In the recent UIP Consensus Document on duplex evaluation after treatment the importance of reporting the findings at the SFJ or SPJ after all types of treatment has been extensively discussed [9].

After endovenous thermal or chemical ablation, persistence or re-appearance of reflux at the SFJ or SPJ and/or at the level of the saphenous stump is always to be considered pathological.

In such case, serial duplex ultrasound examinations can demonstrate reconnection between the incompetent most cranial part of the GSV in the groin and recurrent thigh varicosities, even if the main trunk remains obliterated.

In case of partial or complete recanalisation of the GSV after ablation, reflux may of course be transmitted from the SFJ directly to the recanalised GSV trunk.

The same may occur at the level of the SPJ and SSV.

To further clarify this issue, more studies looking at the fate of the SFJ or SPJ after different treatment forms are to be awaited.

References

- van Rij A.M., Jiang P., Solomon C., Christie R.A., Hill G.B. Recurrence after varicose vein surgery: A prospective long-term clinical study with duplex ultrasound scanning and air plethysmography. *J. Vasc. Surg.* 2003 ; 38 : 935-43.
- Kostas T., Ioannou C.V., Touloupakis E., Giannoukos A.D., Tsetis D., Katsamouris A.N. Recurrent varicose veins after surgery: a new appraisal of a common and complex problem in vascular surgery. *Eur. J. Vasc. Endovasc. Surg.* 2004 ; 27 : 275-82.
- Merchant R.F., Pichot O., Closure Study Group. Long-term outcomes of endovenous radiofrequency obliteration of saphenous reflux as a treatment for superficial venous insufficiency. *J. Vasc. Surg.* 2005 ; 42 : 502-9.
- Proebstle T.M., Alm J., Göckeritz O., Wenzel C., Noppeney T., Lebard C., et al. Three-year European follow-up of endovenous radiofrequency-powered segmental thermal ablation of the great saphenous vein with or without treatment of calf varicosities. *J. Vasc. Surg.* 2011 ; 54 : 146-52.
- Disselhof B.C., der Kinderen D.J., Kelder J.C., Moll F.L. Five-year results of a randomised clinical trial of endovenous laser ablation of the great saphenous vein with and without ligation of the saphenofemoral junction. *Eur. J. Vasc. Endovasc. Surg.* 2011 ; 41 : 685-90.
- Rasmussen L.H., Lawaetz M., Bjoern L., Vennits B., Eklöf B. Randomised trial comparing endovenous laser, radiofrequency, foam sclerotherapy and stripping of the great saphenous vein in patients with varicose veins. One-year results. *Br. J. Surg.* 2011 ; 98 : 1079-87.
- Shadid N., Ceulen R., Nelemans P., Dirksen C., Veraart J., Schurink G.W., et al. Randomized clinical trial of ultrasound-guided foam sclerotherapy versus surgery for the incompetent great saphenous vein. *Br. J. Surg.* 2012 ; 99 : 1062-70.
- De Maeseneer M.G.R. The role of postoperative neovascularisation in recurrence of varicose veins: from historical background to today's evidence. *Acta Chir. Belg.* 2004 ; 104 : 283-9.
- De Maeseneer M.G.R., Pichot O., Cavezzi A., Earnshaw J., van Rij A., Lurie F., Smith P.C. Duplex ultrasound investigation of the veins of the lower limbs after treatment for varicose veins – UIP consensus document. *Eur. J. Vasc. Endovasc. Surg.* 2011 ; 42 : 89-102.
- Eklöf B., Perrin M., Delis K.T., Rutherford R.B., Gloviczki P. Updated terminology of chronic venous disorders: The VEIN-TERM transatlantic interdisciplinary document. *J. Vasc. Surg.* 2009 ; 49 : 498-501.
- Asciutto G., Asciutto K.C., Mumme A., Geier B. Pelvic venous incompetence: reflux patterns and treatment results. *Eur. J. Vasc. Endovasc. Surg.* 2009 ; 38 : 381-6.
- Krysa J., Jones G.T., van Rij A.M. Evidence for a genetic role in varicose veins and chronic venous insufficiency. *Phlebology* 2012 ; 27 : 329-35.
- Fischer R., Chandler J.G., Stenger D., Puhan M.A., De Maeseneer M.G., Schimmelpfennig L. Patient characteristics and physician-determined variables affecting saphenofemoral reflux recurrence after ligation and stripping of the great saphenous vein. *J. Vasc. Surg.* 2006 ; 43 : 81-7.
- van Rij A.M., Jones G.T., Hill G.B., Jiang P. Neovascularization and recurrent varicose veins: more histologic and ultrasound evidence. *J. Vasc. Surg.* 2004 ; 40 : 296-302.
- Perrin M.R., Labropoulos N., Leon L.R. Jr. Presentation of the patient with recurrent varices after surgery (REVAS). *J. Vasc. Surg.* 2006 ; 43 : 327-34.
- Jones L., Braithwaite E.D., Selwyn D., Cooke S., Earnshaw J.J. Reprinted article "Neovascularisation is the principal cause of varicose vein recurrence: results of a randomised trial of stripping the long saphenous vein". *Eur. J. Vasc. Endovasc. Surg.* 2011 ; 42 Suppl 1 : S 57-60.
- Brake M., Lim C.S., Shepherd A.C., Shalhoub J., Davies A.H. Pathogenesis and etiology of recurrent varicose veins. *J. Vasc. Surg.* 2013 ; 57 : 860-8.
- Pichot O., Kabnick L.S., Creton D., Merchant R.F., Schuller-Petrovic S., Chandler J.G. Duplex ultrasound findings two years after great saphenous vein radiofrequency endovenous obliteration. *J. Vasc. Surg.* 2004 ; 39 : 189-95.

19. Fischer R., Chandler J.G., De Maeseneer M.G., Frings N., Lefebvre-Vilardebo M., Earnshaw J.J., et al. The unresolved problem of recurrent saphenofemoral reflux. *J. Am. Coll. Surg.* 2002 ; 195 : 80-94.
 20. Rewerk S., Noppeney T., Winkler M., Willeke F., Duczek C., Meyer A.J., et al. Pathogenesis of primary and recurrent varicose veins at the sapheno-femoral junction. The role of VEGF and VEGF-receptor. (German) *Phlebologie* 2007 ; 36 : 137-42.
 21. Lemasle P., Lefebvre-Vilardebo M., Uhl J.F., Vin F., Baud J. Postoperative recurrence of varices: what if inguinal neovascularisation was nothing more than the development of a pre-existing network? (French) *Phlébologie* 2009 ; 62 : 42-8.
 22. Chandler J.G., Pichot O., Sessa C., Schuller-Petrovic S., Osse F.J., Bergan J.J. Defining the role of extended saphenofemoral junction ligation: A prospective comparative study. *J. Vasc. Surg.* 2000 ; 32 : 941-53.
 23. Pittaluga P., Chastanet S., Guex J.J. Great saphenous vein stripping with preservation of sapheno-femoral confluence: Hemodynamic and clinical results. *J. Vasc. Surg.* 2008 ; 47 : 1300-5.
 24. Myers K.A., Jolley D., Clough A., Kirwan J. Outcome of ultrasound-guided sclerotherapy for varicose veins: medium-term results assessed by ultrasound surveillance. *Eur. J. Vasc. Endovasc. Surg.* 2007 ; 33 : 116-21.
 25. Proebstle T.M., Moehler T., Herdemann S. Reduced recanalization rates of the great saphenous vein after endovenous laser treatment with increased energy dosing: definition of a threshold for the endovenous fluence equivalent. *J. Vasc. Surg.* 2006 ; 44 : 834-9.
 26. Labropoulos N., Bhatti A., Leon L., Borge M., Rodriguez H., Kalman P. Neovascularization after great saphenous vein ablation. *Eur. J. Vasc. Endovasc. Surg.* 2006 ; 31 : 219-22.
 27. Rass K., Frings N., Glowacki P., Hamsch C., Gräber S., Vogt T., et al. Comparable effectiveness of endovenous laser ablation and high ligation with stripping of the great saphenous vein. Two-year results of a randomized clinical trial (RELACS study). *Arch. Dermatol.* 2012 ; 148 : 49-58.
-