

## Laser assisted foam sclerotherapy (LAFOS): a new approach to the treatment of incompetent saphenous veins.

### *Sclérothérapie à la mousse assistée par laser (LAFOS) : une nouvelle approche pour le traitement de l'insuffisance des veines saphènes.*

Frullini A.<sup>1</sup>, Fortuna D.<sup>2</sup>

#### Summary

In order to enhance the treatment of insufficient saphenous vein with sclerosing foam, we used a new technique called **LAFOS (Laser Assisted FOam Sclerotherapy)** in which a new specifically designed Ho: YAG 2100 nm laser has been used to shrink the vein immediately before sclerosing foam injection.

This laser pretreatment is capable to significantly reduce vein diameter thus less foam volume is necessary to ablate the vein with lower chance of complications.

The procedure is performed in ambulatory setting as anesthesia is not required.

We are presenting the short time results of the first 50 cases treated by LAFOS.

**Keywords:** foam sclerotherapy, laser, chronic venous insufficiency, chemical ablation.

#### Résumé

*Dans le but d'améliorer le traitement de l'insuffisance veineuse par sclérothérapie à la mousse, nous avons développé et utilisé une nouvelle technique : **LAFOS (Laser Assisted FOam Sclerotherapy)**, qui nécessite l'utilisation d'un laser Ho:YAG 2100 nm afin de réduire immédiatement le diamètre de la veine avant l'injection de la mousse sclérosante.*

*Le pré-traitement par laser holmium permet d'obtenir une réduction significative du diamètre de la veine, et ainsi de limiter le volume de mousse sclérosante nécessaire, tout en réduisant les risques d'effets secondaires.*

*La procédure est totalement ambulatoire et ne nécessite aucune anesthésie.*

*Nous présentons les premiers résultats sur 50 cas traités par « LAFOS ».*

**Mots-clés :** sclérothérapie à la mousse, laser, insuffisance veineuse chronique, ablation chimique.

## Introduction

Foam sclerotherapy (FS) has represented a true revolution for the treatment of chronic venous insufficiency (CVI).

For the first time sclerotherapy was able to achieve very high early occlusion rate of great and short saphenous vein (GSV-SSV) with minimal discomfort for the patient [1, 2, 3].

This is particularly true for veins with a diameter inferior to 7 mm where the excellent immediate success rate was associated to good medium and late occlusion rate [4, 5].

For larger veins, especially for those exceeding 1 cm diameter, more controversial data are present in literature but it is generally agreed that poorer outcome is expected for immediate result and for late follow up [6, 7].

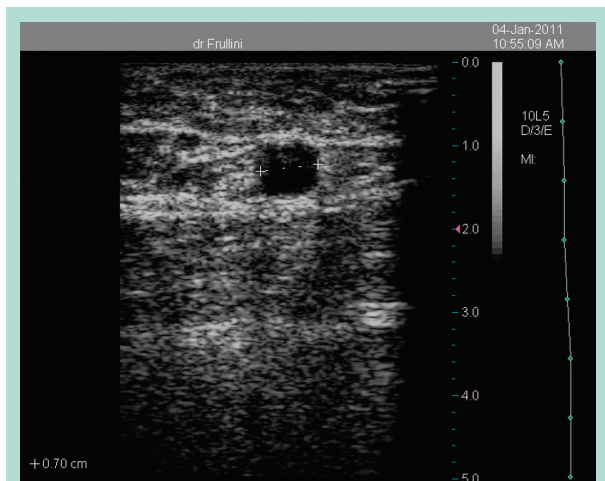
1. Alessandro Frullini, Studio medico flebologico Figline Valdarno, Florence, Italy.

2. Damiano Fortuna, Photobiolab Research Unit, El. En Group, Calenzano, Florence, Italy.

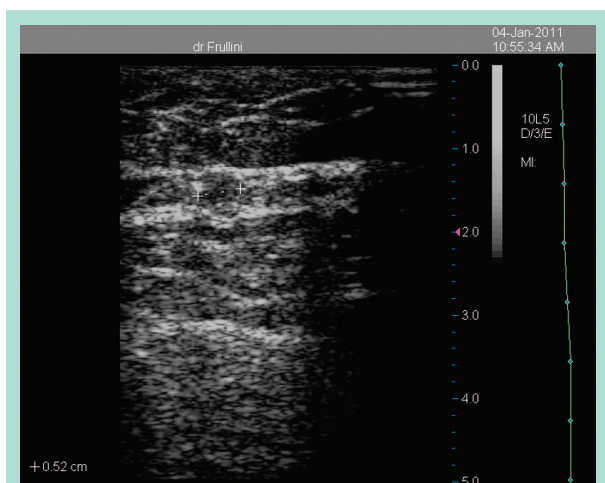
Loc Viesca al Borro 104. 50066 Reggello, Florence, Italy.

E-mail : [info@venevaricose.it](mailto:info@venevaricose.it)

Accepté le 24 janvier 2013



**FIGURE 1 :** GSV before holmium laser treatment.



**FIGURE 2 :** The same vein after holmium laser shrinkage with external diameter reduction and significant thickening of the vein wall (inner lumen diameter below 3 mm).

This is also due to the limited volume of sclerosing foam (SF) that can be injected in a single session in order to limit the risk for side effects.

In fact there is evidence that some side effects are related to the volume of extemporaneous foam used per session as most guidelines limit to 8-10 ml [8].

In order to improve the treatment of larger veins with foam sclerotherapy we have used a new holmium laser (HL) capable to reduce the diameter of the target vein prior to sclerotherapy without damaging vein's intima.

This is achieved inserting the laser fiber through the same cannula used for the foam treatment immediately before the injection and doesn't require anesthesia as the procedure is painless.

This produces an immediate and significant reduction of vein diameter transforming the large vessel in a smaller one that can be treated with better chance of success with a limited dose of SF (**Figure 1** and **Figure 2**).

Moreover, this laser produces significant shrinkage on the media thus possibly enhancing the final result of sclerotherapy.

In fact chemical ablation produces its effects mostly on the endothelium and we hypothesize that thermal shrinking of the media could ameliorates the late occlusion rate.

In this study we are reporting our initial experience in the first 50 cases performed from late 2009 to June 2012.

We used a pulsed Ho:YAG laser (HL) to shrink the saphenous vein followed by foam sclerotherapy on patients with GSV or SSV insufficiency.

This is a not randomized study aimed to assess feasibility and tolerance of this new procedure.

The laser system we used has a 5 W max average power with max 500 mJ per pulse. This laser system has been expressly designed to avoid endothelium damaging while induces the coarctation of the vein wall by mean of the shrinkage of collagen fibers.

The idea is that pulsed holmium laser when used at appropriate setting is able to accumulate heat in the media preserving the endothelium integrity.

Therefore this new procedure called LAFOS (Laser Assisted FOam Sclerotherapy), tested in this study, is conceptually very different from classical endovenous laser ablation (EVLA).

Conversely to EVLA, LAFOS must be considered as an evolution of foam sclerotherapy.

In LAFOS the laser induces the coarctation of the vein wall and ablation will be obtained coupling laser coarctation and foam sclerotherapy.

## Materials and method

From late 2009 to June 2012 we treated 50 patients with chronic venous insufficiency. The treatment was performed on 38 with insufficient greater saphenous vein (GSV) and 12 short saphenous vein (SSV).

Greater saphenous mean diameter was 9.17 (SD 1,8; min 7 and max 15). Shorter saphenous vein (SSV) mean diameter was 7.91 (SD 3,1; min 5 and max 15 mm).

Two GSV were previously unsuccessfully treated with two sessions of echoguided foam sclerotherapy (vein diameter 10 and 12 mm).

This is a pilot study where a true randomization was not done.

## Laser assisted foam sclerotherapy (LAFOS): a new approach to the treatment of incompetent saphenous vein.

The patients were studied before the procedure with clinical and colour-doppler evaluation in standing position (Terason 2000® with 10 MHz linear probe).

Reflux was considered as positive when exceeded 1 second and was elicited using a compression/release manoeuvre.

Diameter was measured and recorded in standing position.

Every patient gave a written informed consent to treatment that was performed in an ambulatory setting. Patients were premedicated with a low molecular weight heparin (LMWH) and aminaftone.

With the patient in lying position for the GSV or prone position for the SSV we gained access to the vein using a 17 G short catheter (Delta Ven® Italy) positioned with the ultrasound guidance.

With the catheter firmly secured to the skin a 5 ml syringe with saline solution was attached and the cannula flushed.

The HL fiber was then entered through the short catheter and fiber position was checked with the duplex.

The tip of the cannula has been usually placed 1-2 cm below the sapheno-femoral or the sapheno-popliteal junction and manually retracted while delivering energy.

Echographic monitoring of the vein was used to check diameter reduction.

Fluency levels ranged from 150 to 400 mJ and were adjusted according to vein size and distance to the skin (when the vein was closer to the skin patients could feel some discomfort during the procedure requiring lower fluences to perform LAFOS).

At the end of laser phase we used the same 17 G catheter to inject a sclerosing foam (SF) produced with polidocanol (3% for GSV or 2% for SSV - Atossisclerol®, Chemische Fabrik Kreussler & Co. GmbH, Wiesbaden - Germany) and room air in 1:4 ratio using the three way technique with 10 complete passages [1]. The mean amount of SF was 5 ml for GSV and 2 ml for SSV.

After foam injection the patient was asked to lie down for 3 minutes and an above knee 30-40 mmHg stocking (Gloriamed®, Italy) for GSV (a similar but below knee stocking for SSV) was positioned on the leg by a nurse in order to avoid any effort to the patient.

**An eccentric compression using a pad** was used at the thigh level for the first 48 hours but not below knee. The garment was prescribed continuously for 48 hours then only during the day for one month on average.

We asked the patient to then walk for 30 minutes after discharge and to walk daily for at least one hour in the treatment period.

Despite additional treatments with SF were given in some patients on tributaries in the follow up, in this study we evaluated only the effect of the LAFOS procedure on the saphenous vein.

Results evaluation was done considering as:

A- total occlusion.

B- partial occlusion with antegrade flow.

C- partial occlusion with retrograde flow.

## Results

- Vein cannulation was easily achieved in most patients.
- In SSV cannulation and progression was always gained.
- In GSV positioning of the short catheter was not possible in 3 cases and this was due to deeper position of the vein (> 1.4 cm).
- Fiber progression was difficult in another 3 patients.
- In the late cases correct positioning and progression were more easily achieved with appropriate external manipulation or longer catheter.
- Vein shrinkage was easily achieved and the internal lumen diameter was reduced in association with thickening of the vein wall.
- Two veins showed a true ablation in a short tract and were injected with foam with direct puncture.
- No complications due to foam sclerotherapy were observed with the exception of minor bruising that resolved uneventfully.
- Echo-guided aspiration of intraluminal clots was routinely performed without retrieving very significant volume of lysed blood.
- Complete occlusion (A) was always observed at one month, even in the two cases resistant to conventional treatment with sclerosing foam.
- No patient referred extreme pain during the laser procedure requiring anesthesia.
- In 8 patients adjustment of laser energy was necessary to avoid discomfort and, with the exception of three patients who referred a painless tickling sensation, the other patients were unaware of the laser action.

## Discussion

Chemical and laser ablation are today the very popular form of treatment [9, 10, 11] but for larger veins, particularly when GSV exceed 7 mm there is still some problems in achieving immediate results comparable to surgical stripping.

**In this pilot study we showed that vein reduction before chemical ablation is a simple and feasible procedure that doesn't require anesthesia.**

In order to induce the shrinkage of collagen fiber of the tunica media of vein, without damaging the intima of vein, we used a 5 W pulsed Ho:YAG laser (Sclerolux® by Techlamed Srl, Italy) characterized by low energy (500 mJ max) and short pulses (350 µs max) and low pulse repetition frequency (10 Hz max).

In our experience we mostly used following signals: 250 mJ, 7 Hz @ 10 Joule/cm in pulling down.

## Conclusions

The immediate reduction of the vein caliber makes possible treatment of large veins, that otherwise require surgical procedure and the reduction of the vein diameter allowed to use low volume of sclerosing foam.

Thanks to a very low amount of energy delivered, anesthesia was never required. Moreover to preserve physiological sensitivity was useful to protect patients from from possible too aggressive laser emission in specific conditions (e.g. close to nerves).

**We believe that LAFOS could represent a true enhancement of foam sclerotherapy allowing better immediate occlusion rate and possibly better late outcome.**

### Acknowledgements

This work was supported by Italian Tuscany Region, action 1.1 P.I.R. 1.1.B, PAR FAS 2007-2013, project: MILORDS.

## References

1. Cavezzi A., Frullini A. Preliminary experience with a new sclerosing foam in the treatment of varicose veins. *Dermatol. Surg.* 2001; 27: 58-60.
2. Cavezzi A., Frullini A., Ricci S., Tessari L. Treatment of varicose veins by foam sclerotherapy: Two clinical series. *Phlebology* 2002; 17: 13-8.
3. Chapman-Smith P., Browne A. Prospective five year study of ultrasound guided foam sclerotherapy in the treatment of great saphenous vein reflux. *Phlebology* 2009; 24: 183-8.
4. Alos J., Carreno P., Lopez J.A., et al. Efficacy and safety of sclerotherapy using Polidocanol foam: A controlled clinical trial. *Eur. J. Vasc. Endovasc. Surg.* 2006; 31: 101-7.
5. Bradbury A.W., Bate G., Pang K., Darvall K.A., Adam D.J. Ultrasound-guided foam sclerotherapy is a safe and clinically effective treatment for superficial venous reflux. *J. Vasc. Surg.* 2010; 52: 939-45.
6. Blaise S., Bosson J.L., Diamand J.M. Ultrasound-guided sclerotherapy of the great saphenous vein with 1% vs. 3% Polidocanol foam: a multicentre double-blind randomised trial with 3-year follow-up. *Eur. J. Vasc. Endovasc. Surg.* 2010; 39: 779-86.
7. Ceulen R.P.M., Bullens-Goessens Y.I.J.M., Pi-Van De Venne S.J.A. Outcomes and side effects of duplex-guided sclerotherapy in the treatment of great saphenous veins with 1% versus 3% Polidocanol foam: Results of a randomized controlled trial with 1-year follow-up. *Dermatol. Surg.* 2007; 33: 276-81.
8. Breu F.X., Guggenbichler, Wollmann J.C. 2nd European Consensus Meeting on Foam Sclerotherapy, 28-30 April 2006, Tegernsee, Germany. *Vasa* 2008; 37 Supplement 71: 1-32.
9. Rasmussen L.H., et al. Randomized clinical trial comparing endovenous laser ablation, radiofrequency ablation, foam sclerotherapy and surgical stripping for great saphenous varicose veins. *Br. J. Surg.* 2011; 98: 1079-87.
10. Shadid N., Ceulen R., Nelemans P., Dirksen C., Veraart J., Schurink G.W., van Neer P., Vd Kley J., de Haan E., Sommer A. Randomized clinical trial of ultrasound-guided foam sclerotherapy versus surgery for the incompetent great saphenous vein. *Br. J. Surg.* 2012; 99: 1062-70.
11. Figueiredo M., Araujo S., Barros N., Miranda F. Results of surgical treatment compared with ultrasound-guided foam sclerotherapy in patients with varicose veins: a prospective randomised study. *Eur. J. Vasc. Endovasc. Surg.* 2009 Dec; 38(6): 758-63.