

ETIOLOGY and NATURAL HISTORY of VENOUS THROMBOSIS of ATYPICAL LOCATION

ÉTIOLOGIE et HISTOIRE NATURELLE de la THROMBOSE VEINEUSE PROFONDE de LOCALISATION ATYPIQUE

W.E. WYSOKINSKI M.D.*†, I. GOSK-BIERSKA M.D.,
P.D.Y. KRYSZTOF KARNICKI M.D.†, R.D. MCBANE, II, M.D.*†

R É S U M É

Dans leur majorité, les processus thrombotiques veineux se développent au niveau des extrémités du corps. Cependant une thrombose veineuse peut survenir dans n'importe quelle localisation, par exemple les sinus veineux cérébraux, les veines rénales, hépatiques, splanchniques...

L'évaluation et le traitement ont été parfaitement codifiés pour la maladie thrombo-embolique veineuse des membres inférieurs ; ils sont beaucoup moins clairs pour les autres localisations.

Le but de ce travail est de récapituler les données de la littérature afin d'en tirer des recommandations pour la mise en place d'un traitement anticoagulant.

Mots-clefs : thromboses veineuses des membres, autres localisations, littérature, traitement anticoagulant.

INTRODUCTION

Deep venous thrombosis commonly involves the venous vasculature of the lower extremity with or without embolism to pulmonary arteries. In the modern era of central venous catheter use and growing cardiac device implantation, the incidence of venous thrombosis of the upper extremity is increasing. Venous thrombosis however may occur at any location including cerebral venous sinuses, renal veins, hepatic veins and other splanchnic veins. Although the diagnosis of venous thrombosis at unusual locations is increasing with the evolution of imaging technology and growing physician awareness, the epidemiology and appropriate treatment remain relatively undefined. Indeed, therapeutic recommendations vary from simple observation to fibrinolytic treatment of the involved venous segments. Some have suggested that venous thrombosis occurring at an unusual location mandate indefinite therapy with warfarin. The purpose of this review is to summarize the corporate literature on which these recommendations are based. Herein, we provide a focused appraisal of the literature of venous thrombosis involving cerebral venous sinuses, renal veins, and hepatic veins (Budd-Chiari Syndrome).

S U M M A R Y

The majority of venous thrombotic events involve the extremities, however venous thrombosis may occur at any location including cerebral venous sinuses, renal veins, hepatic veins and other splanchnic veins. The appropriate evaluation and treatment has been well defined for venous thromboembolism of the legs but it remains less clear for venous thrombosis involving other venous segments. The purpose of this review is to summarize the corporate literature on which to base recommendations for anticoagulant therapy.

Keywords : venous thrombotic events of the extremities, other localisations, literature, anticoagulant therapy.

CEREBRAL VENOUS SINUS THROMBOSIS

Cerebral venous sinus thrombosis (CVST) is an uncommon condition with an often dramatic clinical presentation which affects primarily young-to-middle-aged women [1]. Although initially described nearly two centuries ago [2], only in recent years has the ante-mortem diagnosis been made with increasing frequency largely owing to a better awareness among clinicians and improved non-invasive neuro-imaging techniques. This thrombotic process may involve any combination of venous sinuses, superficial or deep cerebral veins. The superior sagittal and lateral sinuses are most commonly affected and account for 70% of cases (Fig. 1).

Epidemiology

The epidemiology of CVST has not been adequately defined, in part because of its rare occurrence. Furthermore, the demographics of the disease depend largely on ascertainment of cases. In an autopsy series of 182 individuals, Towbin found an incidence of 9.3% with an average age of 73 years [3]. Bienfait et al. however found only one case in 102 consecutive

Division of Cardiovascular Medicine†, Section of Hematology Research, Department of Biochemistry and Molecular Biology, Mayo Clinic and Foundation for Education and Research, Rochester, MN 55905.
University Medical School of Wroclaw, Poland.

© Éditions Phlébologiques Françaises, vol. 60, n° 1/2007, p. 63-75

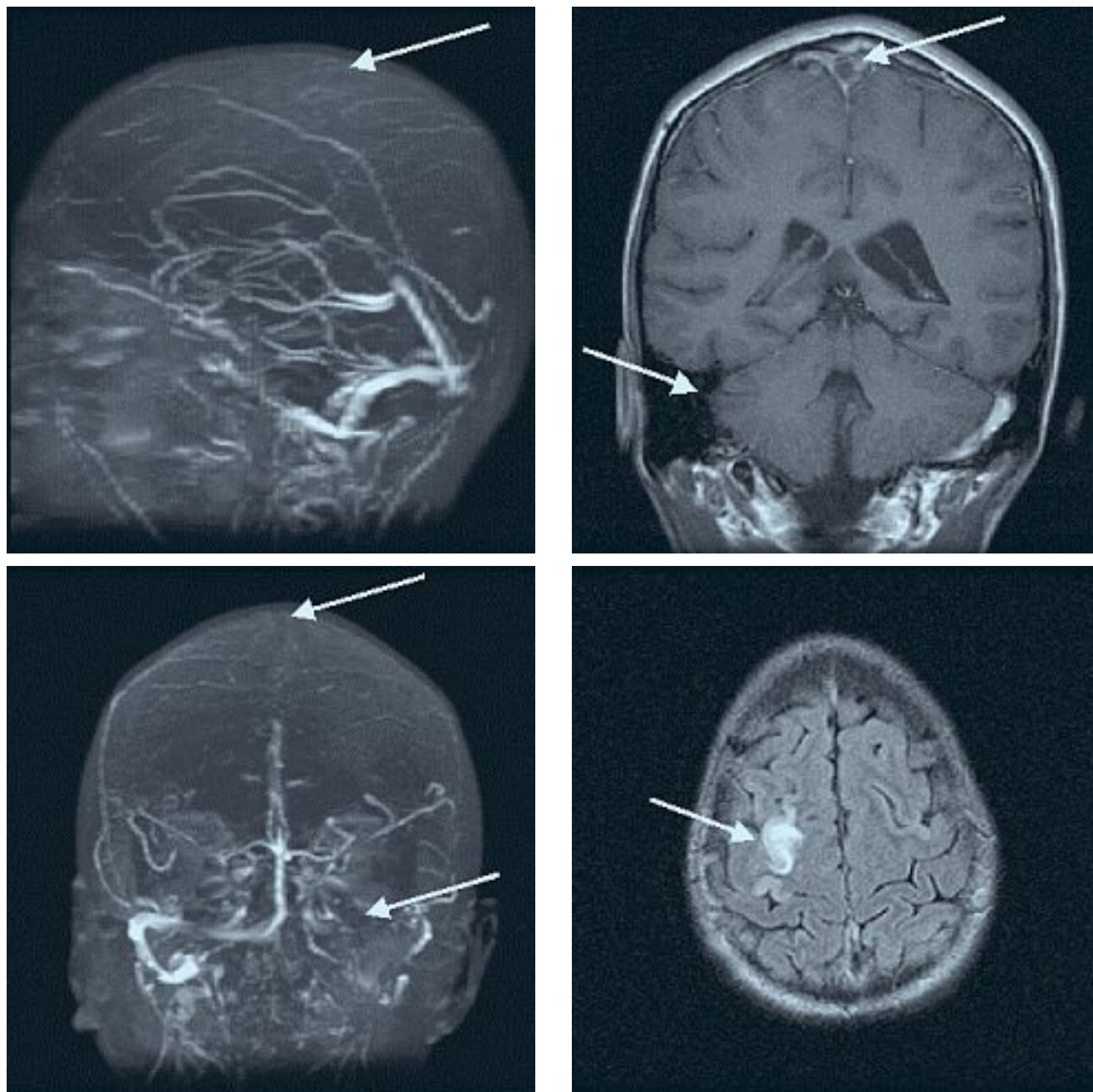


Fig. 1. – Cerebral Venous Sinus Thrombosis. MR images of head without/with gadolinium including axial FLARE images, axial diffusion-weighted images, and MR venography of the major dural venous sinuses. Acute thrombosis (arrows) can be seen throughout the superior sagittal sinus extending into the left transverse sinus and portions of the left sigmoid sinus (Figure 1A-C). An acute venous infarct is evident involving the posterior frontal lobe near the vertex (Fig. 1D)

brain autopsies for an incidence of less than 1% [4]. In comparison, Lanska et al. queried a national health-care utilization database to provide an estimate of peri-partem cerebrovascular events and found 170 cases among 1,408,015 sample deliveries for a national representative risk of 11.6/100,000 deliveries [5]. Not surprisingly, all patients in this latter series were under age 44 (range 15-44). In the Canadian Pediatric Ischemic Stroke Registry, 160 consecutive children with CVST from 16 pediatric tertiary care centers in Canada were enrolled for an incidence of 0.67 cases per 100,000 children [6].

Etiology

Many references relating CVST to an underlying causative condition consist of case reports or small case series. The purported etiology of CVST is therefore myriad encompassing more than 100 unique causes including trauma [7], craniotomy [8], infection [9], arteriovenous malformation [10], central venous catheterization [11] and malignancy [12]. Both acquired and inherited thrombophilias have been implicated including the antiphospholipid antibody syndrome [13], factor V Leiden [14] and prothrombin G20210A

mutations [15], protein C [16], protein S [17], and antithrombin III deficiencies [18]. Deschiens et al. found that an inherited thrombophilia however explained only 15% of the 40 patients with CVST seen at their institution and studied formally for a clotting disorder [19]. Factor V Leiden mutation accounted for 4 of the 6 cases in this series. The use of oral contraception has been found to be an important contributing variable in affected young women and particularly those with an hereditary thrombophilia. De Bruijn et al. found an age adjusted odds ratio of 13 (95% CI, 5-37) for the association between CVST and oral contraception [20]. The prevalence of an inherited thrombophilia in affected women using oral contraception was 19% compared to 7% for the general population for an odds ratio of 3.2. Indeed, pregnancy and the puerperium has been recognized as a vulnerable period for this condition. In the previously cited study of pregnant women by Lanska, caesarian delivery (odds ratio OR 4.10), hypertension (OR 2.42), coexisting pneumonia or influenza (OR 3.45) or other infection (OR 3.10) and excessive vomiting (OR 14.25) were strongly associated with CVST in the post-partum period by multivariate analysis [4]. Hormonal manipulation including replacement therapy in women and androgen use in males may also be contributing causes [21, 22].

Clinical presentation

The clinical presentation of CVST spans a broad spectrum from no symptoms to profound neurologic deficit and mortality. Venous congestion from impaired venous drainage may raise dural venous sinus and central spinal fluid pressure with varying degrees of parenchymal edema, venous infarction and hemorrhage and subsequent clinical and neurologic sequelae. Headache, focal neurologic deficits, seizures, or altered consciousness may occur in isolation or in combination and may begin abruptly or evolve over weeks [1]. De Bruijn et al. found that headache was the most common presenting symptom occurring in 95% of 59 patients participating in their study [23]. Focal neurologic deficits, seizures, and impaired level of consciousness were also common and present in 39-47% of patients. Papilledema was observed in 41% of these patients yet only 15% of patients were comatose on presentation.

Diagnosis

Demonstration of the sinus thrombosis by neuroimaging is crucial in establishing the diagnosis. Computed tomography (CT) especially if performed without contrast can miss the diagnosis of CVST in up to 20% of cases. Furthermore, the findings may be misinterpreted as subarachnoid or intraparenchymal hemorrhage [24-26]. Although contrast enhanced CT can be accurate, the 'typical' empty delta sign representing enhancement of the posterior sagittal sinus wall outlining the luminal clot is infrequently seen [27]. Alterations in blood flow and hemoglobin degradation products in thrombosed veins may produce signal changes on magnetic resonance imaging (MRI) which may suggest

the diagnosis of CVST however such findings may be subtle [28, 29]. Thus, the diagnosis of CVST can be missed, particularly in clinically unsuspected cases, unless gadolinium enhancement is used [26, 30]. Although cerebral angiography remains definitive for the diagnosis of CVST, MR venography has recently become the imaging modality most widely used to establish the diagnosis [26, 31]. Lumbar puncture is usually not helpful, but may be required in severely-ill patients to exclude other diagnoses.

Therapy

Therapeutic recommendations regarding anticoagulant use vary greatly and remain controversial [32]. Although the use of heparin has been long advocated, there is little evidence supporting its use. There have been two small randomized trials of heparinoid therapy with differing results. The first trial which compared heparin to placebo was stopped after enrolling only 20 patients because of the superior efficacy of heparin [33]. Of the heparin-treated patients, 8 recovered and 2 had slight residual neurologic deficits at 3 months. In the placebo arm, one patient recovered, 6 had residual neurological deficits and 3 died. The second trial randomized 59 patients to receive either low molecular weight heparin (nadroparin 90 anti-Xa U/kg bid) for three weeks followed by oral anticoagulation for 3 months or placebo [23, 34]. Three out of 30 patients in the anticoagulation group and 6 of 29 patients in the placebo group had a poor outcome, for an absolute benefit of 7% and a relative risk reduction of 38% favoring anticoagulation. Although this difference did not reach statistical significance, the risk of hemorrhage was not significantly increased in the treatment arm suggesting that this therapy is safe. It is likely that neither trial was sufficiently powered to address this question. In summary, heparin would appear to be a reasonable treatment for this condition with acceptably low hemorrhagic complications. The optimal dose, duration and preparation of heparin, whether standard heparin or low molecular weight heparin, for the treatment of CVST remain to be clarified. Furthermore, the role of oral anticoagulant therapy is uncertain, though likely reasonable.

Use of systemic thrombolysis for dural sinus thrombosis was first reported over 30 years ago using urokinase [35]. There followed a series of open case studies using local infusions either via a frontal burr-hole, or more commonly, via selective venous catheterization [36, 37]. Although the reported experience was generally positive with no excessive hemorrhagic complications, the lack of appropriate control subjects makes these reports difficult to interpret and the absolute benefit remains unknown. Two series studied catheter directed thrombolysis using recombinant tissue plasminogen activator (rtPA) in a limited number of patients [38, 39]. Both employed post-lysis heparin and warfarin therapy. The outcomes were favorable with nearly 60% of patients recovering completely in the larger study [39].

Morbidity can be significant in those surviving an episode of CVST and may be greater than previously

thought. De Bruijn et al. found that one year after the onset of CVST, 35% of survivors had cognitive impairments, 6% were dependent, 40% had lifestyle restrictions, and 40% were unable to return to work [40]. Little is known about the risk of recurrence of cerebral venous sinus thrombosis, although one study reports a frequency as high as 12% [41]. Patients recovering from CVST appear to have an increased risk (14%) of recurrent venous thrombosis in other locations (DVT, PE). Studies assessing venous sinus recanalization following CVST have shown it may be incomplete in some cases [42]. Raised intracranial pressure may also persist following the acute presentation [43]. The mortality for patients with CVST is generally low but ranges from 5 to 30% [20, 23, 35]. Factors associated with a poor outcome include papilledema, impaired consciousness, increased age, delayed diagnosis, intracerebral hemorrhage, and involvement of the straight sinus [23]. Additional factors predicting poor outcome include involvement of the cerebellar veins, uncontrolled seizures, an infectious or malignant etiology. While these thrombi may embolize to the pulmonary vasculature, this is relatively uncommon (11.3%) but associated with significant mortality rate when it occurs [44]. Hypopituitarism may result from cavernous sinus thrombosis [45].

In summary, cerebral venous sinus thrombosis represents a unique clinical syndrome comprising various local and systemic etiologic factors. While treatment with anticoagulants seems warranted, the risk of recurrence for CVST alone is sufficiently vague so as not to justify indefinite anticoagulant therapy unless non-correctable risk variables are found. Recommendations for treatment duration mandate an aggressive search for precise causative variables. Elimination of such acquired variables may reduce the risk to that of the general population.

RENAL VEIN THROMBOSIS

The first description of renal vein thrombosis (RVT) is attributed to Hunter [46] and it was Rayer in 1840 who first recognized its relationship to the nephrotic syndrome [47]. Since this study, much attention has been focused on the association between nephrosis and RVT and most descriptions are derived from patients with this underlying disease substrate. Like CVST however, the epidemiology of RVT in the general population is poorly defined and dependent largely upon case ascertainment. Early studies focused primarily on the *post mortem* diagnosis of RVT found at autopsy. Among 29,280 unselected adult autopsies performed at the Mayo Clinic from 1929 to 1961, only 17 cases of bilateral renal vein thrombosis were found for an incidence of approximately 0.6 per 1,000 autopsies [48]. Among these 17 cases, only 2 had the nephrotic syndrome, males predominated (2.5:1 over females), and the average age was 47 years. Several prospective studies have evaluated the incidence of RVT in the nephrotic syndrome and reported incidences ranging from 1.9 to as high as

42% [49, 50]. Of patients with nephrotic syndrome, membranous glomerulopathy is felt to be most often associated with RVT. Llach prospectively evaluated 151 patient with nephrotic syndrome and found RVT in 22% [51]. Of patients with membranous nephropathy, the incidence was nearly one third. The mechanism for this association is not known, but associated hypercoagulability has been implicated.

Etiology

Although many studies have focused on the association between RVT and nephrotic syndrome, the causes are many (Table I). Several classification schemes have been proposed [48, 52, 53] for dividing contributing variables into systemic and local categories. Primary renal disease is likely the most common cause particularly if renal malignancy is added to this group [48]. Both acute and chronic nephropathic conditions can be complicated by venous thrombosis, particularly membranous glomerulonephritis. The prevailing theory is that RVT results from the underlying kidney disease rather than is its cause. Renal vein thrombosis complicates the nephrotic syndrome one third of the time on average. There are several proposed mechanisms which may contribute to the hypercoagulable state of the nephrotic syndrome. These include increased levels of factors V and VIII [54, 55], reduced AT-III concentration [56, 57], and altered protein S metabolism with reduced free

A. Systemic causes:	
1. Thrombophilia, congenital or acquired	
2. Altered in renal perfusion	
a. Sickle cell disease	e. Hypoglycemia
b. Diarrhea	f. Seizure disorders
c. Sepsis	g. Cyanotic heart disease
d. Adrenal hemorrhage	
3. Right heart failure	
a. Tricuspid insufficiency	b. Constrictive pericarditis
4. Polyarteritis nodosa	
5. Lupus erythematosus	
B. Local causes:	
1. Renal malignancy	
a. Renal cell carcinoma	b. Wilms tumor
2. Glomerulopathies	
a. Membranous glomerulonephritis	b. Lupus nephritis
c. Amyloidosis	
3. Acute pyelonephritis	
4. Altered renal blood flow (extrinsic or intrinsic vascular compression)	
a. Renal vein leiomyosarcoma	
b. Nutcracker syndrome	
c. Abscess	
d. Retroperitoneal tumor or lymphoma	
e. Retroperitoneal fibrosis	
f. IVC filter obstructing renal vein	
5. Renal transplantation (OKT3 and cyclosporine therapy)	
6. Trauma	
7. Surgical ligation or dissection	

Tableau I

protein S and elevated C4b-binding protein, the carrier protein for protein S [58]. Only free protein S maintains anticoagulant activity. Elevated fibrinogen concentrations and thrombocytosis may also contribute. Immunologic injury induced by subepithelial deposition of various antigen and antibody complexes may result in endothelial injury providing a nidus for thrombus formation. In general, any acute and chronic renal disease can be complicated by renal vein thrombosis [59-63]. The prevalence appears to be greater in primary as opposed to secondary glomerular disease [64-68].

Renal cell carcinoma has the propensity to invade the venous system and is associated with venous tumor thrombus in 4% to 25% of cases [69-71]. When present, tumor thrombus heralds a worse prognosis with larger, more advanced grade and stage malignancy and more frequent metastases. Inferior vena caval thrombus propagation with retrograde involvement of renal veins is always a concern particularly in those patients with a supra-renal IVC filter or cephalad filter migration.

Congenital and acquired thrombophilias have been reported including deficiencies of antithrombin III, protein C, protein S deficiencies, hyper-homocysteinemia, and the antiphospholipid syndrome, however these are primarily limited to case reports [72-76]. Oral contraception, pregnancy and the puerperium have also been described as causative factors [75-78].

Renal blood flow is robust comprising 20% of cardiac output. Therefore, rapid efflux of blood from the renal veins may be protective and limit formation of venous clots [79]. Indeed, alterations in renal hemodynamics alone may precipitate RVT thus underlining the relevance of this variable. Dehydration induced by febrile illness, diarrhea, or sepsis has been shown to cause RVT particularly in the infant and neonate. Other causes of hemodynamic instability such as adrenal hemorrhage, hypoglycemia, seizure disorders, cyanotic congenital heart disease and right heart failure have been implicated [59-61, 80].

RVT may be induced by extrinsic and/or intrinsic involvement of the renal vascular pedicle. A primary tumor of the venous wall, usually leiomyosarcoma arising in the inferior vena cava, serves as an example of intrinsic obstruction. Of 86 vascular leiomyosarcomas in one study, 33 involved the inferior vena cava and nearly all were accompanied by thrombus [81]. Renal venous ostia and the retrohepatic portion of inferior vena cava were involved in the majority. Retroperitoneal processes such as tumor, lymphoma, retroperitoneal fibrosis, or abscess may precipitate RVT by extrinsic compression or involvement of the renal veins [82-83]. The "nutcracker phenomenon" involves compression of the left renal vein between the abdominal aorta and the superior mesenteric artery [84]. This syndrome produces left RVT and provokes symptoms of pelvic congestion, which include dysmenorrhea, dysuria with microhematuria, dyspareunia, vulvar and pelvic varices in the female, and varicoceles in males [85].

RVT may occur in transplanted renal allografts which unlike the native kidney have a single drainage system. Bakir et al. [86] reviewed 558 consecutive cadaveric kidney transplants and noted a 6% incidence of RVT, which accounted for one third of all early (90 days) graft failures. Living related donor renal transplant is associated with significantly lower rate of RVT [87]. Predisposing factors may include the use of OKT3 and cyclosporine therapy [88, 89].

Vascular injury due to trauma or surgery may also precipitate RVT. Renal vein thrombosis secondary to trauma is usually accompanied by renal artery thrombosis and is suggested by the history and a palpable flank mass on examination [90, 91].

Clinical Presentation

The clinical manifestation of RVT may range from a complete lack of symptoms to renal failure [48-51, 59-61, 82]. The clinical spectrum of RVT varies extremely depending on the dynamic and extension of venous occlusion, the development of collateral circulation, and underlying disease. After thrombotic renal vein occlusion, venous outflow occurs by subcapsular plexus collaterals or by collateral drainage to ureteral, gonadal and adrenal veins when the left kidney is affected [79, 85]. The outcome is unpredictable and depends on the acuity and severity of thrombosis, response of the collateral circulation and the extent and gravity of the predisposing disease.

Acute complete occlusion, seen more often in neonates and dehydrated infants, results in rapid congestion and hemorrhagic infarction of the affected kidney with subsequent atrophy. If the occlusion occurs gradually, collateral vessels may develop providing adequate venous drainage preventing renal damage. Clinical signs and symptoms may be absent, vague or nonspecific. In contrast, various degrees of upper abdominal and/or flank pain may be the presenting symptom [48-51].

Diagnosis

Duplex ultrasound is useful in the diagnostic evaluation of RVT with direct visualization of thrombi within the renal vein and inferior vena cava, demonstration of renal vein dilatation proximal to the point of occlusion, and increase in renal size during the acute phase of venous congestion [92, 93]. Following infarction, renal atrophy results in a small nonfunctional kidney with abnormal renal structure. Both computerized tomography (CT) and magnetic resonance imaging (MRI) can provide a definitive diagnosis based on visualization of the clots within the vein and inferior vena cava [94-98]. Indirect signs include distention of the affected renal vein, renal enlargement, persistent parenchymal opacification, capsular venous collaterals, and thickening of Gerota's fascia. These studies also provide assessment of abdominal and pelvic contents for other non-genitourinary variables which may be relevant to the etiology of RVT.

Inferior venacavography with selective catheterization of the renal vein establishes the diagnosis of RVT

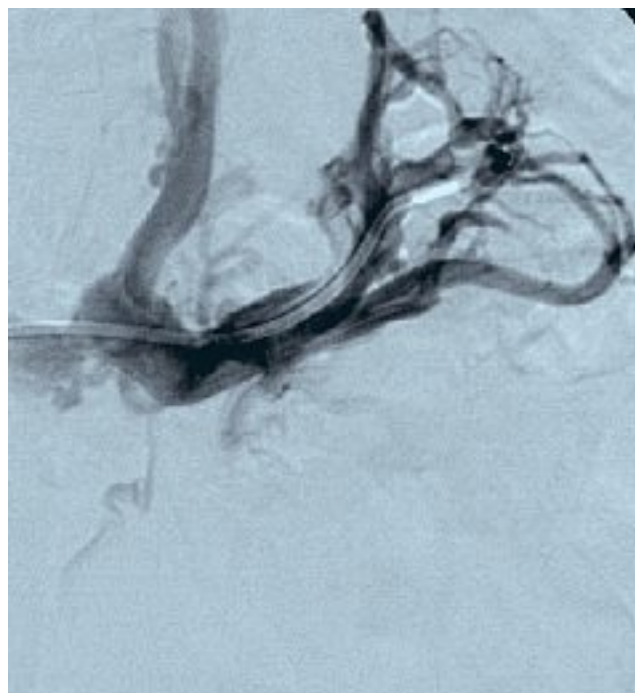
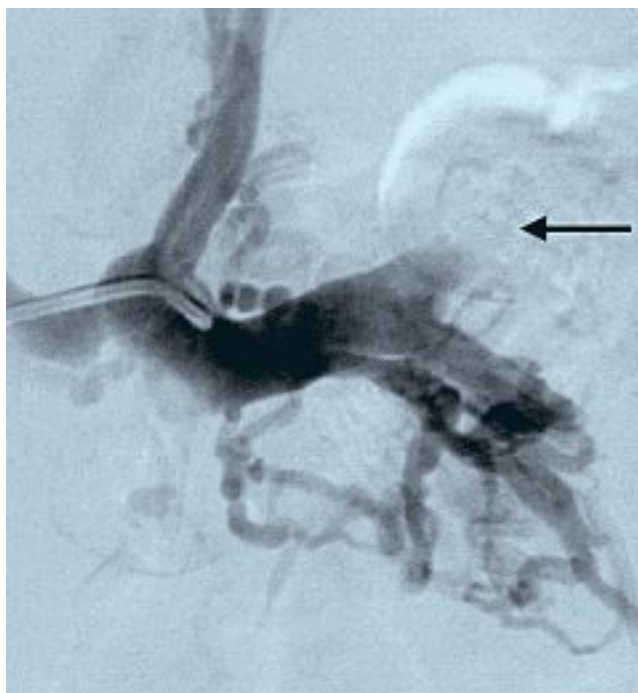

Fig. 2. – Renal Vein Thrombosis. Selective venogram of the left renal vein reveals an acute thrombotic occlusion of the upper pole venous segment (arrow) with stenosis of the central segment and collateral drainage via the adrenal vein (Fig. 2A). Recanalization of the venous occlusion was accomplished with interventional therapy (Fig. 2B)

most reliably [99, 100]. Patent inferior vena cava, free of filling defects, and easily wash out of contrast from the vena cava by good streaming of unopacified renal blood makes a diagnosis of RVT rather unlikely. Selective renal venography may show partial defects indicating clot or stenosis if occlusion is incomplete or an image of amputation in cases of complete occlusion of the renal vein (Fig. 2). The collateral network is often easily demonstrated with this procedure, usually reflects the chronicity of the RVT and explain the lack of renal functional deterioration [101]. Lack of detail in the venous phase limits the utility of renal arteriography in the diagnosis of RVT. Acute RVT will show in arteriography an enlarged kidney, poor filling of cortical arteries and no renal vein drainage if renal vein is completely occluded. Only delayed venous phase films will envisage larger renal veins and site of obstruction [102].

Excretory urography (IVP) reflects interstitial swelling from venous congestion that causes stretching and compression of the collecting system by decreased or absent opacifications [103]. Renal technetium scan findings include persistent concentration on delayed scans with enlargement of the involved kidney [104]. Renal technetium scanning, IVP with retrograde pyelography can help establish the diagnosis of RVT indirectly though have notable pitfalls [99].

Treatment and Prognosis

The main goals of therapy should be to conserve renal parenchyma and protect renal function. To date nephrectomy has been abandoned except in an acute life threatening hemorrhage as a result of capsular rupture [105], renal cell carcinoma, trauma, and extrinsic

compression of the vascular pedicle. In infants with acute severe RVT the initial treatment is management of the underlying condition particularly dehydration, but concomitant anticoagulation treatment is also essential [106, 107].

Conservative approach with anticoagulation as a main therapeutic modality seems to be the best for most cases in adults. There is no up to data any prospective randomized study looking at the effectiveness of anticoagulation in RVT. Most clinical observations of thromboembolic complications and anticoagulation effect came from nephritic patients. These data show high incidence of thromboembolic phenomena and poor prognosis [51, 64, 106-109]. Andrassy and Ritz [110] observed 84 nephrotic cases and found during a period of three years 37 episodes of thromboembolic complications in 30 patients. Among those there were 23 events of deep vein thrombosis, an incidence of 44%, probably the highest number encountered in medical patients. Other investigators reported lower incidence of thromboembolic complications in children and adults patients with nephritic syndrome (27% to 8.5%), but still relatively high compare to classic thromboembolic disease [50, 111-113]. Lower extremity deep vein thrombosis and pulmonary embolism were the most frequently complications. Also prospective study revealed 17% incidence of thromboembolic complications in these patients, with abnormal ventilation-perfusion scan in 21% of cases [51].

Renal function may dramatically improve in patients with acute RVT treated with anticoagulant therapy [48, 51, 59-61, 108, 109]. Relapses with new episodes of acute RVT have been observed after cessation of anticoagulant therapy [114].

These clinical observations seem to indicate that patients with RVT should be treated with heparin and warfarin, that warfarin needs to be continue for at least 6 months, but some recommend anticoagulation to continue until predisposing factor exist [48, 51, 59-61, 115]. Recently, thrombolytic agents, such as urokinase, streptokinase, and tissue plasminogen activator have been used in the management of acute and even chronic renal vein thrombosis, with restoration of renal venous drainage and immediate improvement in function of the affected kidney within 1 to 4 days of the initiation of fibrinolytic therapy [116, 118].

BUDD-CHIARI SYNDROME

Budd-Chiari syndrome (BCS) syndrome results when hepatic venous drainage is obstructed from a variety of causes including thrombosis, tumor, primary veno-occlusive disease or congenital obstruction [119-121]. Of these, hepatic vein thrombosis is the most common particularly in western societies and therefore will be the primary focus of this discussion. Budd-Chiari Syndrome can be classified according to the location of the venous occlusion: Type 1 occurs when the inferior vena cava is occluded with or without obstruction of the hepatic veins; Type 2 involves occlusion of major hepatic veins; and Type 3 occurs when only the small centrilobular venules are involved. The latter results primarily from a fibrous obliteration of small intra-hepatic venules as a complication of bone marrow transplantation. Depending on the nature and extent of venous obstruction, the clinical course may range from a slow insidious onset of symptoms to rampant progression of acute hepatic failure. Hepatic venous outflow obstruction in the chronic setting leads to portal venous flow reversal as blood from hepatic veins and arteries are shunted to the portal system. Hepatocyte injury with atrophy ensues following deprivation of portal venous blood supply, particularly at the periphery of the liver whereas more central regions and the caudate lobe tend to be relatively spared due to independent venous drainage [122].

Etiology

Precise identification of causative variables and their frequency is limited by the rarity of this syndrome and lack of large epidemiology studies. The various implicated etiologies appear to differ by geographical region and are summarized in *Table II*. Congenital membranous obstruction of the IVC is the classic cause of BCS in eastern countries [123] whereas in western culture, thrombosis is the predominant ascribed etiology. The underlying substrate for hepatic venous thrombosis includes inherited or acquired thrombophilic states, myeloproliferative diseases [124, 125], paroxysmal nocturnal hemoglobinuria [126], pregnancy, or the use of oral contraception [127, 128]. Connective tissue diseases and other inflammatory disorders have also been reported causes particularly Behçet syndrome but also systemic lupus erythematosus, Sjögren syndrome, sarcoidosis, and ulcerative

colitis [129-132]. Hepatic venous obstruction may result from extrinsic compression or endoluminal invasion by malignant tumors. Of these, hepatocellular carcinoma, renal cell carcinoma, and Wilms tumor rank highly [119-122, 133, 134].

Deficiencies of antithrombin, protein C and protein S, factor V Leiden and prothrombin G20210A gene mutations, and antiphospholipid antibody syndrome have been reported [133-136]. However, the contribution of either inherited or acquired thrombophilic states is unclear due to the limited number of epidemiological studies with complete coagulation testing. In most studies coagulation testing was performed in less than one third of involved individuals. In a series of 32 patients, Denninger found [134] that one or more thrombophilic variables were present in 33.3% of these patients. A chronic myeloproliferative disorder was identified in 31.2% and 22% of patients this was combined with a thrombophilia. Of those patients with a defined thrombophilia, factor V Leiden was the most common, found in 21.8% followed by antiphospholipid antibodies in 18.7%. Espinosa reported [136] 4 cases of BCS associated with the antiphospholipid antibody syndrome and added 39 cases from a review of the literature for this association. They found that 74% of patients in their series had primary antiphospholipid syndrome as the underlying etiology. In a series of 120 patients [137], the cause of hepatic venous obstruction was identified in 69% of the cases. Nearly three quarters of these patients had a chronic myeloproliferative disorder including polycythemia vera and essential thrombocythemia; paroxysmal nocturnal hemoglobinuria was present in 8%.

Clinical Presentation

As with venous thrombosis at other atypical locations, the clinical consequences of this disorder depend on the extent and rapidity of hepatic venous obstruction. Whereas hepatic venous outflow is accomplished by 3 veins, impairment of a single vein may be clinically silent [119, 120]. More extensive venous involvement causes painful hepatic congestion with stretching of Glisson's capsule and hepatomegaly. Within the confined capsule, sinusoidal congestion with venous hypertension, stasis and hypoxia may lead to hepatocyte necrosis, hemorrhage, and parenchymal damage. The degree of injury may vary from mild to fulminant hepatic failure. In those with a fulminant presentation, rapid decompression is essential to prevent an otherwise invariably poor outcome. Survival of the acute episode does not ensure a good outcome whereby hepatic fibrosis may eventually progress to cirrhosis. A more insidious onset may only come to clinical attention with the development of portal hypertension complicated by ascites, variceal hemorrhage or overt chronic liver failure [119-121, 137].

Diagnosis

The differential diagnosis involves a long list of injurious clinical entities to the liver and other abdominal

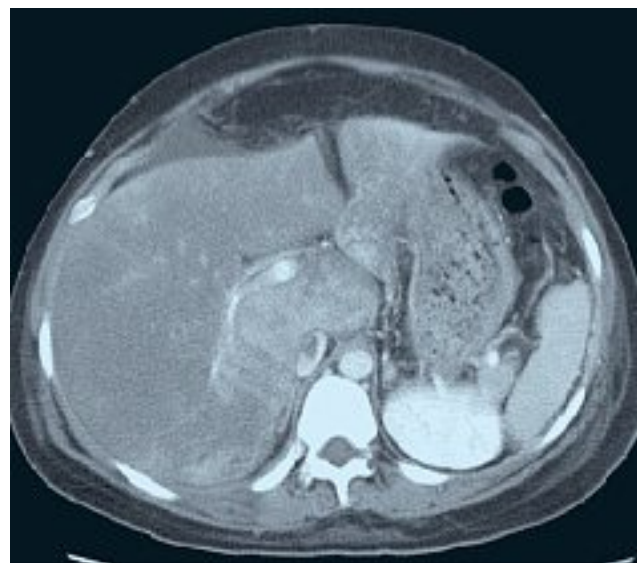
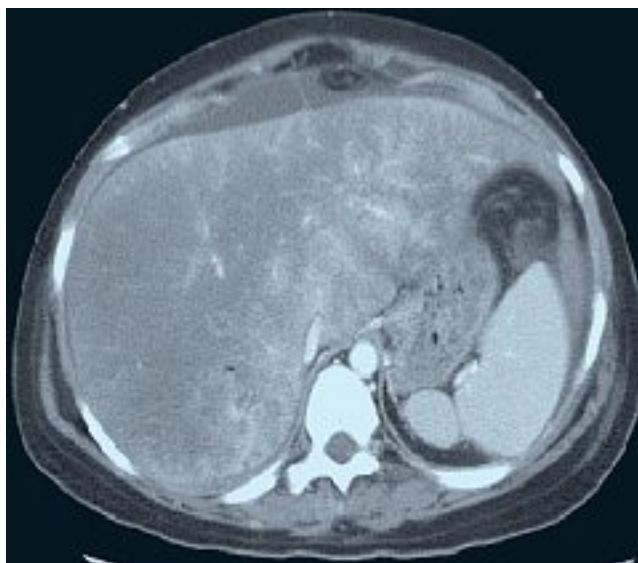


Fig. 3. – Budd-Chiari Syndrome. Contrast computed tomography of the abdomen reveals marked hepatic parenchymal heterogeneity (Figure 3A) with alternating areas of enhanced and decreased perfusion. Non-obstructing thrombus is noted within the inferior vena cava consistent with a type I Budd-Chiari pattern (Fig. 3B)

organs. Although laboratory testing may be helpful to assess hepatic injury and synthetic function, suspected venous obstruction requires imaging for an accurate diagnosis. Doppler ultrasound, magnetic resonance imaging (MRI) and computed tomography (CT) all provide the dual advantage of evaluating liver structure and visualization of hepatic venous with or without IVC thrombosis [122, 138-141]. Both Doppler US and MR angiography allow quantitative measurement of flow velocity, flow profile, and directionality. Acute thrombosis may yield markedly hypointense signal within hepatic veins however, a typical pattern in chronic Budd-Chiari is a marked reduction in the caliber of the hepatic veins, sometimes to the point that they are not identifiable (Fig. 3). The only finding in this setting may be increased intrahepatic collateral veins [139-141]. Associated parenchymal changes include atrophy of the peripheral liver with hypertrophy of the central liver and caudate lobes and dilatation of the hepatic sinusoids. During the healing phase, nodular regenerative hyperplasia may be seen with prominent varices [140].

Treatment and Prognosis

The primary treatment objectives in BCS are to hepatic decompression, functional restoration, and prevention of thrombus propagation and recurrence. Specific treatment depends on the cause and extent of venous obstruction and the reversibility of hepatic injury. Although anticoagulation is often used to prevent venous thrombus propagation and recurrence and to maintain patency of intravascular or surgical shunts, the benefits of chronic anticoagulation therapy remains controversial [142, 143] and have not been proven in randomized controlled trials. Furthermore, the optimal duration and intensity of anticoagulation is unknown. Mechanical or fibrinolytic therapy alone or

in combination to recanalize obstructed hepatic veins have been met with anecdotal success however their optimal role in the treatment of this disorder remains speculative [144-147]. Primary patency rates of angioplasty is as high as 90% for focal disease [148], but in diffuse hepatic vein thrombosis success drops to 56% even with additional thrombolysis [149]. The role of post-procedural anticoagulant use remains an important area of investigation in this and other venous locations to promote long-term patency.

A. Systemic causes:

1. Thrombophilia, congenital or acquired
2. Myeloproliferative disorders
 - a. Essential thrombocythemia
 - b. Polycythemia rubra vera
3. Right heart failure
 - a. Tricuspid insufficiency
 - b. Constrictive pericarditis
4. Pregnancy/Postpartum
5. Oral contraceptive pills
6. Connective tissue diseases
 - a. Bechets syndrome
 - b. Systemic lupus erythematosus
 - c. Sjögren syndrome
7. Inflammatory bowel disease
 - a. Ulcerative colitis

B. Local causes:

1. Intrinsic or extrinsic vascular compromise
 - a. Congenital membranous obstruction
 - b. Malignant hepatic venous invasion
 - c. Posttraumatic/Postsurgical
2. Liver disease
3. Liver metastases
4. Infection
 - a. Abscess
 - b. Filariasis
 - c. Schistosomiasis
 - d. Hydatid cyst
 - e. Syphilis
 - f. Tuberculosis

Tableau II

Surgical shunts decompress hepatic venous circulation by diverting hepatic venous outflow through the portal vein into the inferior vena cava. This procedure relieves sinusoidal congestion and hemorrhage, and reduces hepatocyte necrosis. Potential surgical options include side-to-side portacaval shunt, mesocaval shunt [150] and an H-graft between the portal vein and IVC [151]. Surgical decompressive therapy has been shown to be superior to chronic anticoagulation and medical management in patients with severe BCS [143]. The long-term success of these surgeries in patients varies with five-year survival rates ranging from 57-83%.

Transjugular intrahepatic portasystemic shunts (TIPS) represent another method of mechanically decompressing hepatic venous flow. Using angiographic guidance, a trans-hepatic parenchymal shunt is created between the intrahepatic portal vein and hepatic vein and maintained using stents. Physiologically similar to the surgical portacaval shunt, the TIPS procedure is performed without the risks of general anesthesia or surgery [152].

Lastly, end-stage liver disease may require orthotopic liver transplantation (OLT). In some but not all circumstances, liver transplantation may not only correct hepatic failure and portal hypertension but also remove the underlying cause of hypercoagulability. The organ availability, cost, the potential need for dissection and repair of the suprahepatic vena cava, and the risks of long-term immunosuppression limit the wide implementation of this procedure [150].

In summary, an integrated approach to the management of Budd-Chiari syndrome is appropriate. For those with extensive hepatic vein involvement resulting

from malignancy, palliative therapy is reasonable. In other instances, attempts at hepatic decompression and functional restoration should be considered. While still unproved by randomized controlled trials, the use of anticoagulants for the prevention of thrombus propagation and recurrence should be considered. Irreversible liver injury in a setting of acute BCS, or the presence of cirrhosis and moderate to severe liver failure usually should mandate consideration for liver transplant. Creation of a shunt for hepatic decompression either by TIPS or surgery may provide palliation while waiting for a suitable donor.

DISCUSSION

In summary, venous thrombosis occurring at sites remote from extremity veins represent distinct clinical entities with unique etiology, clinical presentation and natural history relative to the location of thrombosis. Although sharing the common feature of thrombosis at an unusual site, statements regarding appropriate treatment cannot be generalized. While some disorders such as Budd-Chiari Syndrome may herald a malignant clinical course, the outcome of cerebral venous sinus thrombosis is generally more benign. In addition to systemic prothrombotic variables which are shared with typical venous thrombo-embolism of the extremities, local factors unique to the specific organ may play a significant role in thrombogenesis and a decisive role in individuals prognosis. Because of the rarity of these disorders, cooperative multicenter and multidisciplinary efforts are needed to better define the epidemiology and best therapy for each of these syndromes.

REFERENCES

- 1 Kimber J. Cerebral venous sinus thrombosis. *Qjm* 2002; 95: 137-42.
- 2 Ribes M.F. Des recherches faites sur la phlébite. *Revue Médicale Française Etrangère Journal de Clinique de l'Hôtel-Dieu et de la Charité de Paris*. 1825; 3; 5-41.
- 3 Towbin A. The syndrome of latent cerebral venous thrombosis: its frequency and relation to age and congestive heart failure. *Stroke*. 1973; 4 (3): 419-30.
- 4 Bienfait H.P., van Duinen S., Tans J.T. Latent cerebral venous and sinus thrombosis. *J Neurol* 2003; 250: 436-9.
- 5 Lanska D.J., Kryscio R.J. Risk factors for peripartum and postpartum stroke and intracranial venous thrombosis. *Stroke* 2000; 31: 1274-82.
- 6 deVeber G., Andrew M., Adams C., et al. Cerebral sinovenous thrombosis in children. *N Engl J Med* 2001; 345: 417-23.
- 7 Ferrera P.C., Pauze D.R., Chan L. Sagittal sinus thrombosis after closed head injury. *Am J Emerg Med* 1998; 16: 382-5.
- 8 Ingunza I., Hacker H. Cerebral venous and sinus thrombosis in neurosurgical patients. *Radiologie* 1972; 12: 48-52.
- 9 Younis R.T., Lazar R.H., Anand V.K. Intracranial complications of sinusitis: a 15-year review of 39 cases. *Ear Nose Throat J* 2002; 81: 636-8.
- 10 Haisa T., Yoshida S., Ohkubo T., Yoshikawa K., Machida T. Primary empty sella in association with superior sagittal sinus thrombosis and dural arteriovenous malformation. Case report. *J Neurosurg* 1994; 81: 122-5.
- 11 Larkey D., Williams C.R., Fanning J., Hilgers R.D., Graham D.R., Fortin C.J. Fatal superior sagittal sinus thrombosis associated with internal jugular vein catheterization. *Am J Obstet Gynecol* 1993; 169: 1612-4.
- 12 Wester K., Mork S., Smievoll A.I. Neuroblastoma and venous sinus thrombosis in an adult patient. *Br J Neurosurg* 1997; 11: 241-4.
- 13 Arunkalaivanan A.S., Barrington J.W. Late puerperal sagittal sinus thrombosis associated with primary antiphospholipid antibody syndrome. *J Obstet Gynaecol* 2002; 22: 682.
- 14 Stephan C.L., SantaCruz K., May C., Wilkinson S.B., Cunningham M.T. Fatal dural sinus thrombosis associated with heterozygous factor V Leiden and a short activated partial thromboplastin time. *Arch Pathol Lab Med* 2003; 127: 1359-61.
- 15 Reuner K.H., Ruf A., Grau A., Rickmann H., Stolz E., Juttler E., Druschky K.F., Patscheke H. Prothrombin gene G20210. A transition is a risk factor for cerebral venous thrombosis. *Stroke* 1998; 29: 1765-9.
- 16 Ram B., Meiklejohn D.J., Nunez D.A., Murray A., Watson H.G. Combined risk factors contributing to cerebral venous thrombosis in a young woman. *J Laryngol Otol* 2001; 115: 307-10.

REFERENCES

- 17 Witt O., Pereira P.L., Tillmann W. Severe cerebral venous sinus thrombosis and dural arteriovenous fistula in an infant with protein S deficiency. *Childs Nerv Syst* 1999; 15: 128-30.
- 18 Tuite P., Ahmad F., Grant I., Stewart J.D., Carpenter S., Ethier R. Cerebral vein thrombosis due to hereditary antithrombin III deficiency. *Can J Neurol Sci* 1993; 20: 158-61.
- 19 Deschens M.A., Conard J., Horellou M.H., Ameri A., Preter M., Chedru F., Samama M.M., Bousser M.G. Coagulation studies, factor V Leiden, and anticardiolipin antibodies in 40 cases of cerebral venous thrombosis. *Stroke* 1996; 27: 1724-30.
- 20 De Bruijn S.F., Stam J., Koopman M.M., Vandenbroucke J.P. Case-control study of risk of cerebral sinus thrombosis in oral contraceptive users and in carriers of hereditary prothrombotic conditions. The Cerebral Venous Sinus Thrombosis Study Group. *BMJ* 1998; 316: 589-92.
- 21 Strachan R., Hughes D., Cowie R. Thrombosis of the straight sinus complicating hormone replacement therapy. *Br J Neurosurg* 1995; 9: 805-8.
- 22 Jaillard A.S., Hommel M., Mallaret M. Venous sinus thrombosis associated with androgens in a healthy young man. *Stroke* 1994; 25: 212-3.
- 23 de Bruijn S.F., de Haan R.J., Stam J. Clinical features and prognostic factors of cerebral venous sinus thrombosis in a prospective series of 59 patients. For The Cerebral Venous Sinus Thrombosis Study Group. *J Neurol Neurosurg Psych* 2001; 70: 105-8.
- 24 Zilkha A., Stenzler S.A., Lin J.H. Computed tomography of the normal and abnormal superior sagittal sinus. *Clin Radiol* 1982; 33: 415-25.
- 25 Provenzale J.M., Joseph G.J., Barboriak D.P. Dural sinus thrombosis: findings on CT and MR imaging and diagnostic pitfalls. *Am J Radiology* 1998; 170: 777-83.
- 26 Ozsvath R.R., Casey S.O., Lunstrin E.S., Alberico T., Hassankhani A., Patel M. Cerebral venography: comparison of CT and MR projection venography. *Am J Radiology* 1997; 169: 1699-707.
- 27 Virapongse C., Cazenave C., Quisling R., Sarwar M., Hunter S. The empty delta sign. *Radiology* 1987; 162: 779-85.
- 28 Bianchi D., Maeder P., Bogousslavsky J., Schnyder P., Meuli R.A. Diagnosis of cerebral venous thrombosis with routine magnetic resonance: an update. *Eur Neurol* 1998; 40: 179-90.
- 29 Selim M., Fink J., Linfante I., Kumar S., Schlaug G., Caplan L.R. Diagnosis of cerebral venous thrombosis with echo-planar T2-weighted magnetic resonance imaging. *Arch Neurol* 2002; 59: 1021-6.
- 30 Anxionnat R., Evrard S., Louaille C., Chiras J., Marsault C. MRI in cerebral venous thrombosis. *J Neuroradiol* 1994; 21: 81-99.
- 31 Mitchell P., Wilkinson I.D., Hoggard N., et al. Detection of subarachnoid haemorrhage with magnetic resonance imaging. *J Neurol Neurosurg Psychiatry* 2001; 70: 205-11.
- 32 Benamer H.T., Bone I. Cerebral venous thrombosis: anticoagulants or thrombolytic therapy? *J Neurol Neurosurg Psych* 2000; 69: 427-30.
- 33 Einhaupl K.M., Villringer A., Meister W., Mehraein S., Garner C., Pellkopfer M., Haberl R.L., Pfister H.-W., Schmiedek P. Heparin treatment in sinus venous thrombosis. *Lancet* 1991; 338: 597-600.
- 34 de Bruijn S., Stam J. Randomized placebo controlled trial of anticoagulant treatment with low molecular weight heparin for cerebral sinus thrombosis. *Stroke* 1999; 30: 484-8.
- 35 Vines F.S., Davis D.O. Clinical and radiological correlation in cerebral venous occlusive disease. *Radiology* 1971; 98: 9-22.
- 36 Scott J.A., Pascuzzi R.M., Hall P.V., Becker G.J. Treatment of dural sinus thrombosis with local urokinase infusion. *J Neurosurg* 1988; 68: 284-7.
- 37 Horowitz M., Purdy P., Unwin H., Carstens G., Greenlee R., Hise J., Kopitnik T., Batjer H., Rollins N., Samson D. Treatment of dural sinus thrombosis using selective catheterisation and urokinase. *Ann Neurol* 1995; 38: 58-67.
- 38 Kim S.Y., Suh J.H. Direct endovascular thrombolytic therapy for dural sinus thrombosis: infusion of alteplase. *Am J Neuroradiol* 1997; 18: 639-45.
- 39 Frey J.L., Muro G.J., McDougall C.G., Dean B.L., Jahnke H.K. Cerebral venous thrombosis: combined intrathrombus rtPA and i.v heparin. *Stroke* 1999; 30: 489-94.
- 40 de Bruijn S.F., Budde M., Teunisse S., de Haan R.J., Stam J. Long-term outcome of cognition and functional health after cerebral venous sinus thrombosis. *Neurology* 2000; 54: 1687-9.
- 41 Preter M., Tzourio C., Ameri A., Bousser M.G. Long-term prognosis in cerebral venous thrombosis: follow up of 77 patients. *Stroke* 1996; 27: 243-6.
- 42 Dormont D., Anxionnat R., Evrard S., Louaille C., Chiras J., Marsault C. MRI in cerebral venous thrombosis. *J Neuroradiol* 1994; 21: 81-99.
- 43 Tsai F.Y., Wang A.M., Matovich V.B., Lavin M., Berberian B., Simonson T.M., Yuh W.T. MR staging of acute dural sinus thrombosis: correlation with venous pressure measurements and implications for treatment and prognosis. *Am J Neuroradiol* 1995; 16: 1021-9.
- 44 Diaz J.M., Schiffman J.S., Urban E.S., Maccario M. Superior sagittal sinus thrombosis and pulmonary embolism: a syndrome rediscovered. *Acta Neurol Scand* 1992; 86: 390-6.
- 45 Hladky J.P., Leys D., Vantghem M.C., Furby A., Leclerc X., Dupard T., Lefebvre J. Early hypopituitarism following cavernous sinus thrombosis: total recovery within 1 year. *Clin Neurol Neurosurg* 1991; 93: 249-52.
- 46 Hunter J. Guide to the Hunterian Collection, Part 1: Pathological Series in the Hunterian Museum. Specimen p. 389. A Case of Renal Vein Thrombosis (Lady Beauchamp). Edinburgh, Livingstone, 1966: 267.
- 47 Rayer P. *Traité des maladies des reins*. Baillière, Paris, 1840.
- 48 McCarthy L.J., Titus J.L., Daugherty G.W. Bilateral renal vein thrombosis and the nephrotic syndrome in adults. *Ann Intern Med* 1963; 58: 837-49.
- 49 Zucchelli P. Renal vein thrombosis. *Nephrol Dial Transplant* 1992; 7 (suppl. 1): 105-8.
- 50 Velasquez Forero F., Garcia Prugue N., Ruiz Morales N. Idiopathic nephrotic syndrome of the adult with asymptomatic thrombosis of the renal vein. *Am J Nephrol* 1988; 8: 457-62.
- 51 Llach F., Papper S., Massry S.G. The clinical spectrum of renal vein thrombosis: acute and chronic. *Am J Med* 1980; 69: 819-27.
- 52 Allen A.C. The clinicopathologic meaning of the nephrotic syndrome. *Am J Med* 1955; 18: 277.
- 53 Berman L.B., Schreiner G.E. Clinical and histologic spectrum of the nephrotic syndrome. *Am J Med* 1958; 24: 249.
- 54 Kanfer A., Fleinknetch D., Broyer M., et al. Coagulation studies in 45 cases of nephrotic syndrome without uremia. *Thromb Diathes Haemorrh* 1970; 24: 562-8.

REFERENCES

- 55 Thompson C., Forbes C.D., Prentice C.R.M., et al. Changes in blood coagulation and fibrinolysis in the nephrotic syndrome. *Q J Med* 1974; 43: 399-412.
- 56 Thaler E., Blazar E., Kopsa H., et al. Acquired antithrombin III deficiency in patients with glomerular proteinuria. *Hemostasis* 1978; 7: 257-62.
- 57 Ellis D. Recurrent renal vein thrombosis and renal failure associated with Antithrombin-III deficiency. *Pediatr Nephrol* 1992; 6: 131-4.
- 58 Vigano-D'Angelo S., D'Angelo A., Kauffman C.E., et al. Protein S deficiency occurs in the nephrotic syndrome. *Am Inter Med* 1987; 107: 42-51.
- 59 Duncan R.E., Evans A.T., Martin L.W. Natural history and treatment of renal vein thrombosis in children. *J Ped Surg* 1977; 12: 639.
- 60 McClelland C.Q., Hughes J.P. Thrombosis of renal vein in infants. *J Ped* 1950; 36: 214.
- 61 Stark H. Renal vein thrombosis in infancy: recovery without nephrectomy. *Amer J Dis Child* 1964; 108: 430.
- 62 Sturgill B.C., Rowe C.T. Renal vein thrombosis and the nephrotic syndrome. Immunofluorescence studies. *Arch Intern Med* 1967; 120: 708.
- 63 Khokhani R.C., Raghavan P., Sant S.M., Ganatra R.D., Sharma S.H., Shak M.I. Unilateral renal vein thrombosis with nephrotic syndrome. *Brit Med J* 1966; 5502: 1523.
- 64 McCarthy L.J., Titus J.L., Daugherty G.W. Bilateral renal-vein thrombosis and the nephrotic syndrome in adults. *Ann Intern Med* 1963; 58: 837.
- 65 Trew P.A., Biava C.G., Jacobs R.P., Hopper J., Jr. Renal vein thrombosis in membranous glomerulonephropathy: incidence and association. *Medicine* 1978; 57: 69.
- 66 McMorrow R.G., Curtis J.J., Luke R.G. Renal vein thrombosis in IgA nephropathy. *Arch Intern Med* 1980; 140: 700.
- 67 Klassen J., Sugisaki T., Milgrom F., McCluskey R.T. Studies on multiple renal lesions in Heymann nephritis. *Lab Invest* 1971; 25: 577.
- 68 Barklay G.P., Cameron H.M., Loughridge L.W. Amyloid disease of the kidney and renal vein thrombosis. *Quart J Med* 1958; 29: 197.
- 69 Ljungberg B., Stenling R., Osterdahl B., Farrelly E., Aberg T., Roos G. Vein invasion in renal cell carcinoma: impact on metastatic behavior and survival. *J Urol* 1995; 154: 1681.
- 70 Naitoh J., Kaplan A., Dorey F., Figlin R., Belldregun A. Metastatic renal cell carcinoma with concurrent inferior vena caval invasion: long-term survival after combination therapy with radical nephrectomy, vena caval thrombectomy and postoperative immunotherapy. *J Urol* 1999; 162: 46.
- 71 Zisman A., Pantuck A.J., Chao D.H., Wieder J.A., Dorey F., Said J.W., Kernion J.B., De Figlin R., Belldregun A.S. Renal Cell Carcinoma With Tumor Thrombus: Is Cytoreductive Nephrectomy For Advanced Disease Associated With An Increased Complication Rate? *The Journal of Urology* 2002; 168: 962-7.
- 72 Cosgriff T.M., Bishop D.T., Hershgold E.J., et al. Familial antithrombin III deficiency: its natural history, genetics, diagnosis and treatment. *Medicine (Baltimore)* 1983; 62: 209-20.
- 73 Wysokinski W., Verhaeghe R., Arnout J., Vermynen J. Protein C deficiency associated with venous thromboembolism. *Acta Clinica Belgica* 1990; 45: 78-84.
- 74 Formstone C.J., Hallam P.J., Tuddenham E.G., Voke J., Layton M., Nicolaides K., Hann IM., Cooper DN. Severe perinatal thrombosis in double and triple heterozygous offspring of a family segregating two independent protein S mutations and a protein C mutation. *Blood* 1996; 87: 3731-7.
- 75 Chang H., Douketis J., Nowaczyk M. Acute renal vein thrombosis, oral contraceptive use, and hyperhomocysteinemia. *Mayo Clin Proc* 2001; 76: 212-4.
- 76 Asherson R.A., Buchanan N., Baguley E., Hughes G.R. Postpartum bilateral renal vein thrombosis in the primary antiphospholipid syndrome. *J Rheumatol* 1993; 20: 874.
- 77 Vessey M.P. Oral contraceptives and thromboembolic disease. *Amer Heart J* 1969; 77: 153.
- 78 Rosario D.J., Radley S.C., Goepel J.R., et al. Renal infarction following spontaneous renal vein thrombosis in the puerperium. *Br J Obstet Gynaecol*, 1999; 106: 1223.
- 79 Harris I.D., Ehrenfeld W.K., Lee J.C., Wylie E.J. Experimental renal vein occlusion. *Surg Gynec & Obst* 1968; 126: 555.
- 80 Burack W.R., Pryce J., Goodwin J.F. A reversible nephrotic syndrome associated with congestive heart failure. *Circulation* 1958; 18: 562.
- 81 Kevorkian J., Cento D.P. Leiomyosarcoma of large arteries and veins. *Surgery* 1973; 73: 390.
- 82 Harrison C.V., Milne M.D., Steiner R.E. Clinical aspects of renal vein thrombosis. *Quart J Med* 1956; 25: 285.
- 83 Abeshouse B.S. Thrombosis and thrombophlebitis of the renal veins. *Urol Cutan Rev* 1945; 49: 661.
- 84 de Schepper A. Nutcracker fenomeen van da vena renalis en veneuz pathologie van de linker nier. *J Belge Radiol* 1972; 55: 507-11.
- 85 Zerhouni E.A., Siegelmann S.S., Walsh P.C., White R.I. Elevated pressure in the left renal vein in patients with varicocele: preliminary observations. *J Urol* 1980; 123: 512.
- 86 Bakir N., Sluiter W.J., Ploeg R.J., et al. Primary renal graft thrombosis. *Nephrol Dial Transplant* 1996; 11: 140-7.
- 87 Osman Y., Shokeir A., Ali-el-Dein B., Tantawy M., Wafa E.W., Shehab el-Dein A.B., Ghoneim M.A. Vascular Complications After Live Donor Renal Transplantation: Study of Risk Factors and Effects on Graft and Patient Survival. *The Journal of Urology* 2003; 169: 859-62.
- 88 Hay C.R.M., McEvoy P. Main graft vessel thromboses due to conventional dose OKT3 in renal transplantation. *Lancet* 1992; 339: 1612-3.
- 89 Richardson A.J., Higgins R.M., Jaskowski A.J., et al. Spontaneous rupture of renal allografts: The importance of renal vein thrombosis in the cyclosporin era. *Br J Surg* 1990; 77: 558-60.
- 90 Jennings E.R., Glucksmann M.A. Renal vein ligation. *JAMA* 1970; 213: 1905.
- 91 Clark C.D. Survival after excision of a kidney, segmental resection of the vena cava, and division of the opposite renal vein. *Lancet* 1961; 2: 1015.
- 92 Rosenfield A.T., Zeman R.K., Cronan J.J., Taylor K.J. Ultrasound in experimental and clinical vein thrombosis. *Radiology* 1980; 137: 735.
- 93 Platt J.F., Ellis J.H., Rubin J.M. Intrarenal arterial Doppler sonography in the detection of renal vein thrombosis of the native kidney. *AJR* 1994; 162: 1367.

REFERENCES

- 94 Gatewood O.M., Siegelman S.S., Fishman E.K., et al. Renal vein thrombosis in patients with nephrotic syndrome. CT diagnosis. *Radiology* 1986; 159: 117-20.
- 95 Birnbaum B.A., Bosniak M.A., Megibow A.J. Asymmetry of the renal nephrograms on CT: significance of the unilateral prolonged cortical nephrogram. *Urol Rad* 1991; 12: 173.
- 96 Tempany C.M., Morton R.A., Marshall F.F. MRI of the renal veins: assessment of nonneoplastic venous thrombosis. *J Comput Assist Tomogr* 1992; 16: 929.
- 97 Fritzsche P.J. Current state of MRI in renal mass diagnosis and staging of RCC. *Urol Rad* 1989; 11: 210.
- 98 Prince M.R., Narasimham D.L., Stanley J.C. Breath-hold gadolinium-enhanced MR angiography of the abdominal aorta and its major branches. *Radiology* 1995; 197: 785-792.
- 99 Wegner G.P., Crummy A.B., Flaherty T.T., Hipona F.A. Renal vein thrombosis: a roentgenographic diagnosis. *JAMA* 1969; 209: 1661.
- 100 Beckman C.F., Abrams H.L. Renal venography: anatomy, technique, applications, analysis of 132 venograms, and a review of the literature. *Cardiovasc. Intervent Rad* 1980; 3: 45.
- 101 Martin E.C., Gordon D.H. Selective renal venography in patients with primary renal disease and the nephrotic syndrome. *Cardiovasc. Intervent Rad* 1980; 3: 175.
- 102 Koehler P.R., Bowles W.T., McAlister W.H. Renal arteriography in experimental renal vein occlusion. *Radiology* 1966; 86: 851.
- 103 Scanlon G.T. Radiographic changes in renal vein thrombosis. *Radiology* 1963; 80: 208-19.
- 104 Park C.H., Kim S.M., Intenzo C. Scintigraphic findings of coexisting renal artery stenosis and renal vein thrombosis. *Clin Nucl Med* 1993; 18: 990.
- 105 Campbell M.F., Matthews W.F. Renal thrombosis in infancy; report of 2 cases in male infants urologically examined and cured by nephrectomy at 13 and 33 days of age. *J Ped* 1942; 20: 604.
- 106 Belman A.B., Susmano D.F., Burden J.J., Kaplan J.W. Nonoperative treatment of unilateral renal vein thrombosis in the newborn. *JAMA* 1970; 211: 1165.
- 107 Seeler R.A., Kapadia P., Moncado R. Nonsurgical management of thrombosis of bilateral renal veins and inferior vena cava in a newborn infant. *Clin Ped* 1970; 9: 543.
- 108 Richet G., Meyrier A. (eds). *Liposcélrose rétropéritonéale. Thrombose des veines rénales. Deux syndromes rétropéritonéaux.* Masson, Paris, 1970.
- 109 Lavelle M., Aguilera D., Maillet P.J., et al. The prognosis of renal vein thrombosis: A reevaluation of 27 cases. *Nephrol Dial Transplant* 1988; 3: 247-61.
- 110 Andrassy K., Ritz R. Biochemie und klinische Bedeutung von Urokinase. *Dtsch Med Wochenschr* 1978; 24: 1015-26.
- 111 Kuhlmann U., Stevner J., Rhyner K., et al. Platelet aggregation and B-thromboglobulin levels in nephrotic patients with and without thrombosis. *Clin Nephrol* 1981; 15: 229-38.
- 112 Kauffman R.H., De Graeff J., Brutel De La Riviere G., et al. Unilateral renal vein thrombosis and nephrotic syndrome. *Am J Med* 1976; 60: 1048-56.
- 113 Andrassy K., Depperman D., Walter E., et al. Is beta thromboglobulin a useful indicator of thrombosis in nephrotic syndrome? *Thromb Haemost* 1979; 42: 486-93.
- 114 Briefel G.R., Manis T., Gordon D.H. Recurrent renal vein thrombosis consequent to membranous nephropathy. *Clin Nephrol* 1978; 10: 32-9.
- 115 Llach R. Nephrotic Syndrome: Hypercoagulability, Renal Vein Thrombosis, and Other Thromboembolic Complications. In Brenner B., Stein J. (eds): *Contemporary Issues in Nephrology*, Vol 9. Churchill-Livingston, New York, 1982: 121-44.
- 116 Rowe J.M., Rasmussen R.L., Mader S.L., Dimarco P.L., Cockett A.T., Marder V.J. Successful thrombolytic therapy in two patients with renal vein thrombosis. *Amer J Med* 1984; 77: 1111.
- 117 Jaar B.G., Kim H.S., Samaniego M.D., Lund G.B., Atta M.G. Percutaneous mechanical thrombectomy: a new approach in the treatment of acute renal-vein thrombosis. *Nephrol Dial Transplant* 2002; 17: 1122-5.
- 118 Dilawari J.B., Bamberg P., Chawla Y., Kaur U., Bhusnurmath S.R., Malhotra H.S., Sood G.K., Mitra S.K., Khanna S.K., Walia B.S. Hepatic outflow obstruction (Budd-Chiari syndrome). Experience with 177 patients and a review of the literature. *Medicine (Baltimore)* 1994; 73: 21-36.
- 119 Murphy F.B., Steinberg H.V., Shires 3rd G.T. et al. The Budd-Chiari syndrome: A review. *AJR Am J Roentgenol* 1986; 147: 9-15.
- 120 Hadengue A., Poliquin M., Vilgrain V., Belghiti J., Degott C., Erlinger S., Benhamou J.P. The changing scene of hepatic vein thrombosis: Recognition of asymptomatic cases. *Gastroenterology* 1994; 106: 1042-7.
- 121 Mathieu D., Vasile N., Menu Y., et al. Budd-Chiari syndrome: Dynamic CT. *Radiology* 1987; 165: 409-13.
- 122 Lu C.L., Chou Y.H., Hwang S.J., et al. Membranous obstruction of inferior vena cava in Taiwan. *J Gastroenterol Hepatol* 1995; 10: 287-94.
- 123 Valla D., Casadevall N., Lacombe N., et al. Primary myeloproliferative disorders and hepatic vein thrombosis. A prospective study of erythroid colony formation in vitro in 20 patients with Budd-Chiari syndrome. *Ann Intern Med* 1985; 103: 325-34.
- 124 De Stefano V., Teofili L., Leone G., et al. Spontaneous erythroid colony formation as the clue to an underlying myeloproliferative disorder in patients with Budd-Chiari syndrome or portal vein thrombosis. *Semin Thromb Hemost* 1997; 23: 411-8.
- 125 Sholar P.W., Bell W.R. Thrombolytic therapy for inferior vena cava thrombosis in paroxysmal nocturnal hemoglobinuria. *Ann Intern Med* 1985; 103: 539-41.
- 126 Valla D., Le M.G., Poynard T., Zucman N., Rueff B., Benhamou J.P. Risk of hepatic vein thrombosis in relation to recent use of oral contraceptives. A case-control study. *Gastroenterology* 1986; 90: 807-11.
- 127 Ilan Y., Oren R., Shouval D. Postpartum Budd-Chiari syndrome with prolonged hypercoagulability state. *Am J Obstet Gynecol* 1990; 162: 1164-5.
- 128 Averbuch M., Levo Y. Budd-Chiari syndrome as the major thrombotic complication of systemic lupus erythematosus with the lupus anticoagulant. *Ann Rheum Dis* 1986; 45: 435-7.
- 129 Matsuura H., Matsumoto T., Hashimoto T. Budd-Chiari syndrome in a patient with Sjogren's syndrome. *American Journal of Gastroenterology* 1983; 78: 822-5.

REFERENCES

- 130 Russi E.W., Bansky G., Pfaltz M., Spinass G., Hammer B., Senning A. Budd-Chiari syndrome in sarcoidosis. *American Journal of Gastroenterology* 1986; 81: 71-5.
- 131 Chesner I.M., Muller S., Newman J. Ulcerative colitis complicated by Budd-Chiari syndrome. *Gut* 1986; 27: 1096-100.
- 132 Ganguli S., Ramzan N., McKusick M., et al. Budd-Chiari syndrome in patients with hematologic disease: a therapeutic challenge. *Hepatology* 1998; 27: 1157-61.
- 133 Denninger M.H., Chait Y., Casadevall N., Hillaire S., Guillin M.C., Bezeaud A., Erlinger S., Briere J., Valla D. Cause of portal or hepatic venous thrombosis in adults: The role of multiple concurrent factors. *Hepatology* 2000; 31: 587-91.
- 134 Janssen H.L.A., Meinardi J.R., Vlegaar F.P., van Uum S.H.M., Haagsma E.B., van der Meer F.J.M., van Hattum J., Chameleau R.A.F.M., Adang R.P., Vanderbroucke J.P., van Hoek B., Rosendaal F.R. Factor V Leiden mutation, prothrombin gene mutation, and deficiencies in coagulation inhibitors associated with Budd-Chiari syndrome and portal vein thrombosis: Results of a case-control study. *Blood* 2000; 96: 2364-8.
- 135 Espinosa G., Font J., Garcia-Pagan J.C., Tassies D., Reverter J.C., Gaig C., Cervantes F., Cervera R., Bosch J., Ingelmo M. Budd-Chiari Syndrome Secondary to Antiphospholipid Syndrome: Clinical and Immunologic Characteristics of 43 Patients. *Medicine* 2001; 80: 345-54.
- 136 Zeitoun G., Escolano S., Hadengue A., Azar N., El Younsi M., Mallet A., Boudet M.J., Hay J.M., Erlinger S., Benhamou J.P., Belghiti J., Valla D. Outcome of Budd-Chiari syndrome: A multivariate analysis of factors related to survival including surgical portosystemic shunting. *Hepatology* 1999; 30: 84-9.
- 137 Kane R., Eustace S. Diagnosis of Budd-Chiari syndrome: Comparison between sonography and MR angiography. *Radiology* 1995; 195: 117-21.
- 138 Morrin M., Pedrosa I., Rofsky N. Magnetic Resonance Imaging for Disorders of Liver Vasculature. *TMPI* 2002; 13: 177-90.
- 139 Castellano G., Canga F., Solis-Herruzo J.A., et al. Budd-Chiari syndrome associated with nodular regenerative hyperplasia of the liver. *J Clin Gastroenterol* 1989; 11: 698-702.
- 140 Lee V.S., Lavelle M.T., Krinsky G.A., et al. Volumetric MR imaging of the liver and applications. *Magn Reson Imaging Clin North Am* 2001; 9: 697-716.
- 141 Ilan Y., Oren R., Shouval D. Postpartum Budd-Chiari syndrome with prolonged hypercoagulability state. *Am J Obstet Gynecol* 1990; 162: 1164-5.
- 142 Ahn S.S., Yellin A., Sheng F.C., et al. Selective surgical therapy of the Budd-Chiari syndrome provides superior survivor rates than conservative medical management. *J Vasc Surg* 1987; 5: 28-37.
- 143 Baijal S.S., Roy S., Phadke R.V., et al. Management of idiopathic Budd-Chiari syndrome with primary stent placement: early results. *J Vasc Interv Radiol* 1996; 7: 545-53.
- 144 Bilbao J.I., Pueyo J.C., Longo J.M., et al. Interventional therapeutic techniques in Budd-Chiari syndrome. *Cardiovasc Intervent Radiol* 1997; 20: 112-9.
- 145 Pisani Ceretti A., Intra M., Prestipino F., et al. Surgical and radiologic treatment of primary Budd-Chiari syndrome. *World J Surg* 1998; 22: 48-53.
- 146 Bilbao J.I., Pueyo J.C., Longo J.M., et al. Interventional therapeutic techniques in Budd-Chiari syndrome. *Cardiovasc Intervent Radiol* 1997; 20: 112-9.
- 147 Zajko A.B., Claus D., Clapuyt P., et al. Obstruction to hepatic venous drainage after liver transplantation: treatment with balloon angioplasty. *Radiology* 1989; 170: 763-5.
- 148 Griffith J.F., Mahmoud A.E., Cooper S., et al. Radiological intervention in Budd-Chiari syndrome: techniques and outcome in 18 patients. *Clin Radiol* 1996; 51: 775-84.
- 149 Bismuth H., Sherlock D.J. Portosystemic shunting versus liver transplantation for the Budd-Chiari syndrome. *Ann Surg* 1991; 214: 581-9.
- 150 Gauthier F., De Dreuzey O., Valayer J., et al. H-type shunt with an autologous venous graft for treatment of portal hypertension in children. *J Pediatr Surg* 1989; 24: 1041-3.
- 151 Bismuth H., Sherlock D.J. Portosystemic shunting versus liver transplantation for the Budd-Chiari syndrome. *Ann Surg* 1991; 214: 581-9.
- 152 Gauthier F., De Dreuzey O., Valayer J., et al. H-type shunt with an autologous venous graft for treatment of portal hypertension in children. *J Pediatr Surg* 1989; 24: 1041-3.