



Psoriasis Improvement Following Vein Surgery. *Amélioration du psoriasis après chirurgie veineuse.*

Grondin L.

Résumé

Ce cas clinique concerne un homme de 43 ans qui présentait une insuffisance bilatérale des grandes veines saphènes et un psoriasis détériorant des deux membres inférieurs. Ce cas est intéressant car il avait été remarqué qu'un phénomène de Koebner psoriasique était survenu au niveau des deux jambes, après une sclérothérapie réalisée dix ans auparavant et qu'une amélioration significative des plaques de psoriasis était survenue après l'ablation par laser endoveineux des GVS. Cette présentation passe en revue les associations entre les réactions vasculaires inflammatoires et le psoriasis.

Mots-clés : insuffisance veineuse des grandes veines saphènes, psoriasis, phénomène de Koebner, sclérothérapie, laser endoveineux.

Summary

The present case concerns a 43-year-old male who presented with bilateral greater saphenous vein insufficiency and deteriorating psoriasis in both lower legs.

This case is interesting in that he had noticed Koebner-psoriatic-spread in both legs following sclerotherapy ten years prior, and significant improvement in the psoriatic plaques following endovenous laser ablation this time around. This presentation reviews the inflammatory vascular associations of psoriasis.

Keywords : venous insufficiency of the great saphenous veins, psoriasis, Koebner phenomenon, sclerotherapy, endovenous laser.

Case Presentation

Our patient is a 43-year old male who presented with heaviness and throbbing in both legs. His past medical history includes a long-standing relationship with obesity, arterial hypertension, and psoriasis. He works as a heavy equipment salesman, and has no hobbies. He takes no medications, does not smoke nor drink.

His psoriasis appeared in his early twenties involving elbows, knees and shins. He consulted a dermatologist, who recommended corticosteroid ointments. He stopped using skin care products in his late twenties when he decided to "just put up with the itch and dry skin in the winter months". He developed arterial hypertension in his mid thirties. He was initially placed on beta-blockers, which aggravated his varicose veins, his psoriasis and caused ankle edema. He has been off all medications since, and simply reduced his salt intake. He has his blood pressure taken on regular basis and claims that it is within normal limits. His weight has not changed in ten years and his only exercise is walking.

He developed varicose veins in his late twenties. He consulted a specialist and was treated with sclerotherapy. He states that the treatment improved the appearance of his legs and reduced his ankle edema.

During the treatment session he described undergoing thrombectomies in the calf veins, which resulted in new psoriatic (Koebner phenomenon) plaques that have persisted to this date. Koebner phenomenon previously has been described in association with acupuncture [1] but not following sclerotherapy. His mother had psoriasis and varicose veins. There is no family history for thrombophilia.

Physical Examination

Height: 6 feet, 4 inches; weight: 305 lbs. BP: 135/80 mmHg; pulse 74 (regular); afebrile.

Vascular examination

Revealed enlarged and tortuous greater saphenous trunks bilaterally, which were visible and palpable from the groin to the distal third of the calf. Dilated anterior genicular, anterior and posterior accessory saphenous veins of the calf were also present bilaterally. The ankle, calf, and thigh circumferences and the leg lengths were symmetrical. The femoral, popliteal, anterior and posterior tibial pulses were normal and symmetrical. The ankles demonstrated hyper-pigmentation with no "atrophie blanche".

E-mail : louis.grondin@shaw.ca

Accepté le 4 septembre 2011

Psoriasis Improvement Following Vein Surgery.

Skin examination

Showed well-demarcated dull-red plaques covering the extensor surface of the elbows and knees bilaterally. The lesions were thick and covered in white yellow scales. The shin area presented multiple bright-red nummular plaques covered with white scales. These bled easily with rubbing; three of five nails of the right and left hand had pitting, oil staining, and distal onycholysis. The nails of the feet were normal. The palms and soles were unaffected; and only a few (less than 2 cms) plaques were present on the scalp vertex.

The remainder of the physical examination was unrevealing.

Non-invasive studies

Consisted of plethysmographic and duplex color flow ultrasound studies, which confirmed recurrent GSV incompetence of sapheno-femoral origin. Synechia were present in the proximal and middle third segment of the right GSV. The deep venous system was patent and competent.

Clinical Diagnosis: Bilateral superficial venous insufficiency of the legs from Greater Saphenous Vein (GSV) incompetence and active psoriasis.

CEAP: Classification [2] (see Appendix I).

Right leg: C: 4a,s / E: p / A P s: 1r 2r 3r 5r / A P p: 18r (level 2 / X 2009).

Left leg: C: 4a,s / E: p / A P s: 1r 2r 3r 5r / A P p: 18r (level 2 / X 2009).

PASI Score: 11-A (H-3; T-0; U-3; L-5) [3].

Treatment and Evolution

Because of the presence of synechia in the lumen of the RGSV, the treatment plan was to perform EVLA for the LGSV and UGFS for the RGSV. In view of his previous experience with Kobnerization following incision punctures, surgery was avoided. With some difficulty (because of previous treatments), the LGSV was ablated using a 980 nm laser (10 watts/99.6 joules/cm) endovenously, and the RGSV was injected through a 8 micron filter with 12 cc of sodium tetradecyl sulfate in a foam state with a 1:5 mix with CO₂ gas.

Following the treatment compressive bandages (Unna paste) and (30–40 mmHg) stocking were worn for 1 week. Vessel closure was confirmed at 1 and 3 months post operatively when Gregor returned to the clinic for follow up sclerotherapy of tributary branches.

No new psoriatic lesions were observed.

At this initial stage in his treatment (after the elimination of both greater saphenous veins) the patient experienced a significant reduction in edema and in the appearance of his shin psoriasis. The psoriatic plaques received no treatment other than the occasional application of emollients, and the plaque regression has been sustained for over a year (as seen in **Figure 1** and **Figure 2**).

Discussion

Psoriasis

Long confused with leprosy, psoriasis as an illness has not significantly changed since its description by Ferdinand Von Hebra in 1841. Its estimated prevalence is still between 2%–3% of the population. Although the mechanism of disease is still debated, it is considered within the spectrum of immune-related diseases characterized by chronic inflammation in the absence of known infectious agents or antigens [4].

Psoriasis has genomic associations with ankylosing spondylitis, arthritis, Crohn's disease and diabetes [4].

Some publications point to a further association with inflammatory based vascular disorders such as ischemic heart disease, peripheral arterial occlusive disease, arterial hypertension, and stroke [5].

There is no known association between psoriasis and venous disorders except for a 1.6 fold increase of venous thrombosis in psoriatic patients [6].

Current treatment strategy for psoriasis aims at an integrated approach targeting both the cutaneous and systemic inflammatory process to improve overall quality of life and reduce the disease burden [7].

Chronic Venous Disorders (CVD)

Venous disorders encompass a wide spectrum of conditions ranging from telangiectasias to life threatening thromboembolic events [8]. Estimates of the prevalence of varicose veins vary widely from 2-56% in men and from 1-60% in women [9].

CVD reaches its phenotypic apogee with the appearance of venous ulcerations [8].

Prior to this it will have manifested as edema, dermatitis, hyper-pigmentation, eczema, and lipodermatosclerosis [10].

CVD is the single most common cause of eczema and ulceration in the lower limbs as illustrated in **Figure 3** both the progression of varicose veins and the skin manifestations of CVD are attributed to a two-staged inflammatory process [10]. Stage one is responsible for the progressive deterioration of vein segments leading to the appearance and deterioration of varicose veins.

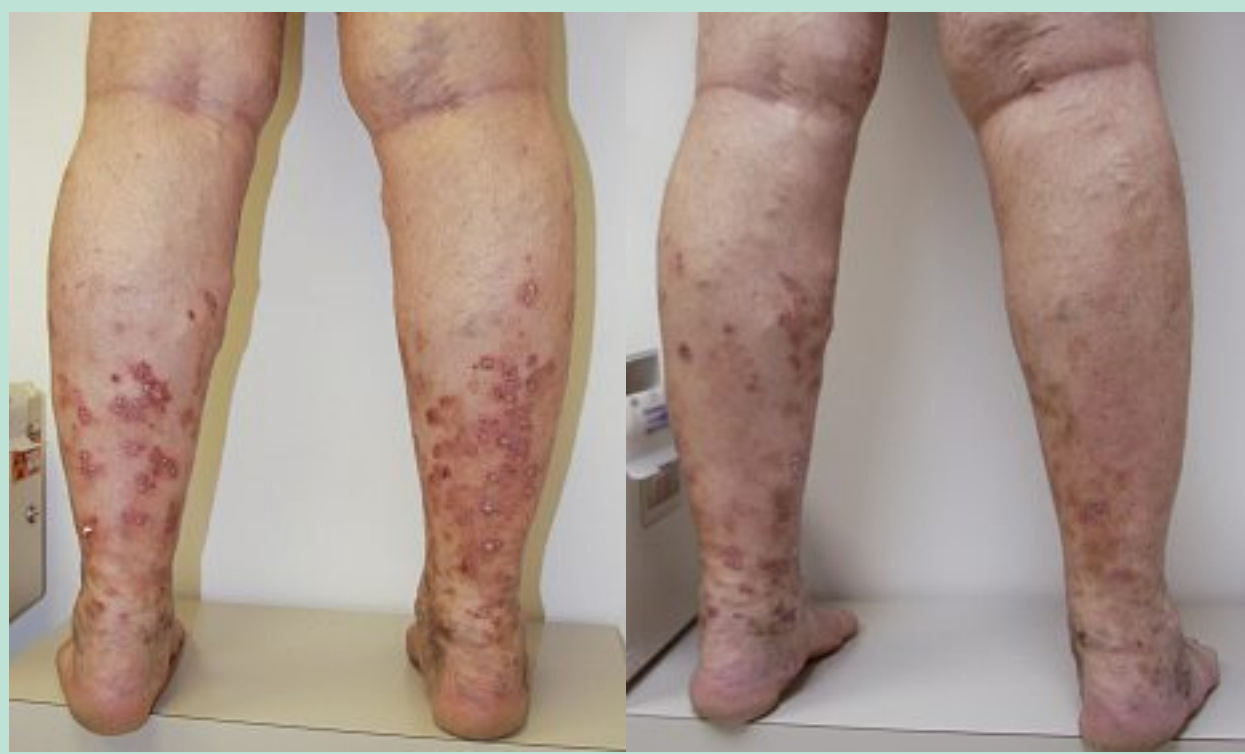
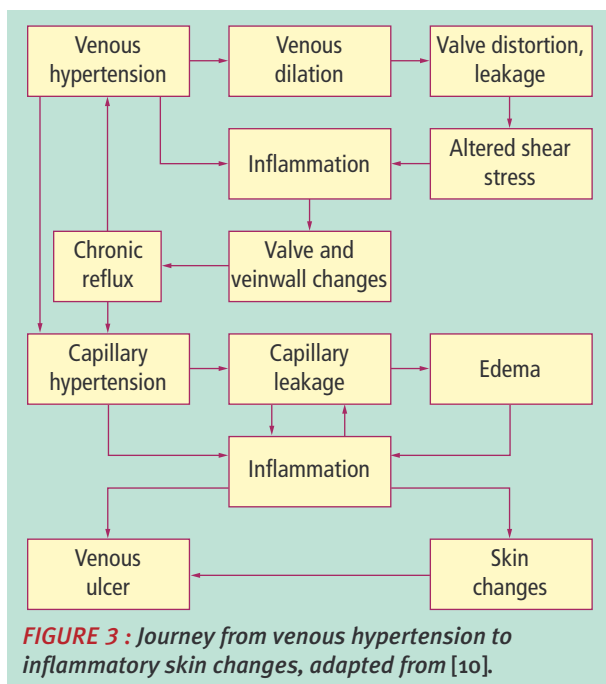


FIGURE 1 : Before and 3 months after endovenous laser ablation of both GSVs: there is significant reduction in symptoms, erythema and psoriatic plaques.

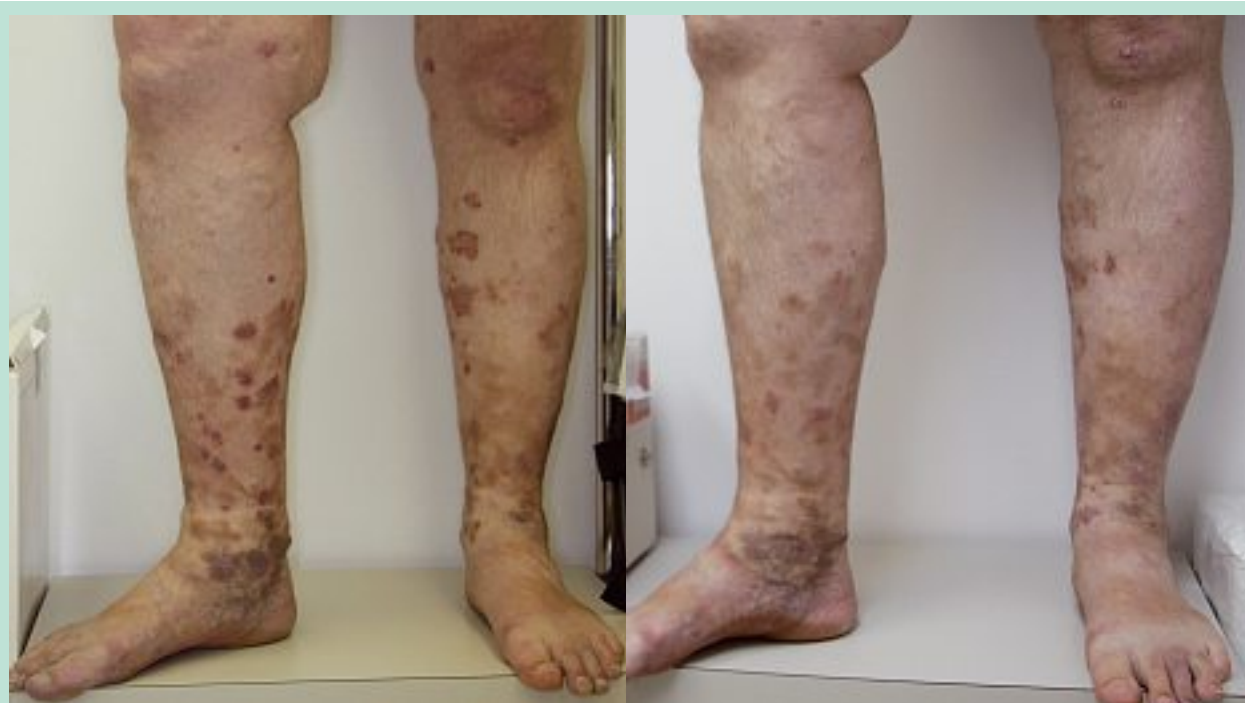

FIGURE 2 : Before and 3 months after endovenous laser ablation of both GSV's. There is significant reduction in symptoms, erythema and psoriatic plaques.

Psoriasis Improvement Following Vein Surgery.



It is induced by persistent venous hypertension and turbulent-reversing shear stress on the vessel wall.

This results in leukocyte adhesion, activation and migration into the tissues, which initiates vein-wall damage and remodeling [10].

The second stage is responsible for the skin changes of CVD, and is still a matter of research and debate. At present the increased capillary permeability that results in leukocyte, erythrocyte, and protein extravasations into the dermis and hypodermis is the accepted trigger mechanism.

There are repeated documentation of matrix metalloproteinase (MMP) and iron-dependent reactive oxygen species (ROS) production causing extracellular matrix destruction, and release of vascular endothelial growth factor (VEGF) leading to the elongation and “glomerulization” of the papillary capillaries characteristic of advanced CVD histology [11].

Of late the inflammatory cascade in CVD was found to share several aspects with that of multiple sclerosis, in which an impairment of cerebral venous outflow has also been demonstrated [11].

A possible inflammatory link

Psoriasis is a type 1 T-helper cell driven epidermal inflammatory disease [4]. Current understanding of the mechanism of disease in psoriasis divides the process into two distinct phases: 1/disease initiation and 2/ disease maintenance.

The first phase is felt to occur when, as a result of environmental triggers, plasmacytoid dendritic cells produce TNF- α , interleukin (IL)-1 β , IL-6 and nitric oxide synthase.

This activates dermal dendritic cells, which in turn recruit and activate Th-1 cells in regional lymph nodes.

Once activated Th-1 cells initiate a second inflammatory cascade, which is responsible for psoriatic disease maintenance.

This phase is strangely similar to the second inflammatory cascade of CVD with release of cytokines TGF- β , TNF- α and VEGF. This is however as far as the similarities go between the two conditions. There is no dermal destruction in psoriasis.

This may explain why our patient did not develop dermal and hypodermal manifestations of CVD. He manifested instead a constant inflammatory psoriatic eruption, which we postulate was mediated by CVD-induced cytokine release. Perhaps by reducing his ambulatory hypertension improved vascular permeability. This in turn reduced leukocyte-migration thus down-regulating the second inflammatory phase of both CVD and psoriasis.

Published trials have reported improving psoriasis by reducing vascular permeability through *selectin* blockage [12].

Conclusion

Unquestionably this obese sedentary patient with advanced venous (C4a,s) disease could have presented with stasis eczema or lipodermatosclerosis. Instead he presented with eruptive inflammatory psoriasis.

Although not previously reported in the literature his eruptive psoriasis underwent rapid involution following the treatment of both greater saphenous veins.

This, points to a CVD-driven inflammation as the driver of his established psoriasis. Perhaps the molecular cascades of these two conditions intersect in their pathogenesis.

Further studies on this nexus may advance our understanding of the molecular basis of these conditions and answer the question: “does psoriasis have a dermal protective effect in CVD?”

References

1. Kirschbaum J.O. Koebner phenomenon following acupuncture. Arch. Dermatol. 1972 Nov ; 106(5) : 767.
2. Classification and grading of chronic venous disease in the lower limbs. A consensus statement. Ad Hoc Committee, American Venous Forum. J. Cardiovasc. Surg. (Torino) 1997 Oct ; 38(5) : 437-41.

- de Rie M.A., Goedkoop A.Y., Bos J.D. Overview of psoriasis. *Dermatol. Ther.* 2004 ; 17(5) : 341-9.
- Nestle F.O., Kaplan D.H., Barker J. Psoriasis. *N. Engl. J. Med.* 2009 Jul 30 ; 361(5) : 496-509.
- Prodanovich S., Kirsner R.S., Kravetz J.D., Ma F., Martinez L., Federman D.G. Association of psoriasis with coronary artery, cerebrovascular, and peripheral vascular diseases and mortality. *Arch. Dermatol.* 2009 Jun ; 145(6) : 700-3.
- Gisoni P., Girolomoni G. Psoriasis and atherothrombotic diseases: disease-specific and non-disease-specific risk factors. *Semin. Thromb. Hemost.* 2009 Apr ; 35(3) : 313-24.
- Gulliver W. Long-term prognosis in patients with psoriasis. *Br. J. Dermatol.* 2008 Aug ; 159 Suppl 2 : 2-9.
- Grondin L. Venous physiology. *Phlebologie* 1988 Apr-Jun ; 41(2) : XXV-XXVIII.
- Robertson L., Evans C., Fowkes F.G. Epidemiology of chronic venous disease. *Phlebology* 2008 ; 23(3) : 103-11.
- Bergan J.J., Schmid-Schönbein G.W., Coleridge Smith P.D., Nicolaides A.N., Boisseau M.R., Eklof B. Chronic Venous Disease: Mechanisms of Disease. *N. Engl. J. Med.* [Review Article] August ; 355(5) : 488-98.
- Zamboni P., Lanzara S., Mascoli F., Caggiati A., Liboni A. Inflammation in venous disease. *Int. Angiol.* 2008 Oct ; 27(5) : 361-9.
- Rossi B., Constantin G. Anti-selectin therapy for the treatment of inflammatory diseases. *Inflamm. Allergy Drug Targets* 2008 Jun ; 7(2) : 85-93.

Découvrez Phlébologie Annales Vasculaires ON LINE

SOCIÉTÉ FRANÇAISE DE
PHLEBOLOGIE

The screenshot displays the website for the journal 'Phlébologie Annales Vasculaires'. At the top, the journal title is prominently displayed. Below the title, there is a navigation bar with options like 'Accueil', 'Table des matières', 'Archives', 'Contact', and 'A propos'. The main content area is titled 'N° 3 - Septembre 2011, 64e année'. It is divided into two columns: 'The Journal' on the left and 'Le Journal' on the right. The 'The Journal' column lists 'Original articles', 'Reviews', 'Phlebology of practice', 'Comments', 'SFP Magazine', 'Professional Practice', 'The SFP in the World', 'Practical Phlebology', 'SFP and Congress', 'SFP and Society', 'SFP and Education', 'SFP and Research', 'SFP and Quality', 'SFP and Ethics', 'SFP and Environment', 'SFP and Future'. The 'Le Journal' column lists 'Articles originaux', 'Mises au point', 'Phlébologie d'actualité', 'Commentaires', 'Le Magazine', 'Pratique phlébologique', 'Forme pratique', 'Actualités', 'Le SFP dans le monde', 'Analyse et avis de phlébologues experts dans divers domaines de la phlébologie', 'Prévention', 'Congrès et Journées de Phlébologie', 'Le phlébologue', 'La lettre de l'éditeur', 'SFP et Société', 'SFP et Éducation', 'SFP et Recherche', 'SFP et Qualité', 'SFP et Éthique', 'SFP et Environnement', 'SFP et Futur'. A central image shows the cover of the journal issue. At the bottom, there is a footer with the text 'LA REVUE INTERNATIONALE DE PHLEBOLOGIE' and 'Organisme officiel de la Société Française de Phlébologie et de la Société Canadienne de Phlébologie'.

SOCIÉTÉ CANADIENNE DE PHLEBOLOGIE
CANADIAN SOCIETY OF PHLEBOLOGISTS