

Congenital AV fistula of the leg with a threat in later decades.

Fistule AV congénitale de la jambe avec des risques dans les décennies venir.

Kemperman P.M.J.H., de Haas E.R.M., Neumann H.A.M.

Summary

An arteriovenous fistula was diagnosed in a woman with a progressive painful and swollen limb. Ligation of the fistula resulted in decongestion of the limb and reduction of the pain. As the history of trauma or surgery in this case was negative, it is likely the AV fistula is congenital.

Keywords: arteriovenous fistula, threatened limb, congenital.

Résumé

Une fistule artério-veineuse a été diagnostiquée chez une femme qui présentait un membre inférieur douloureux et enflé. La ligature de la fistule a conduit à la décongestion du membre et une diminution de la douleur. Puisque la femme ne présentait pas d'antécédents de traumatisme ou de chirurgie, il est probable que la fistule AV fut congénitale.

Mots-clés : fistule artério-veineuse, jambe en danger, congénitale.

We report a 87-year-old woman with progressive pain at the left lower limb known with venous insufficiency and secondary lymphedema after multiple deep venous thrombosis in antithrombin III deficiency. Patient developed the last three months two leg ulcers without any signs of improvement despite manual lymphatic drainage, pneumatic compression and intensive wound treatment. Due to worsening of the exercise-induced pain in the lower limb the patient was referred to our centre for further evaluation and treatment.

Physical examination revealed a large swollen left leg to the groin with pitting and non-pitting oedema, with two indurated painful erythematous lesions. Stemmer's sign was positive on the left foot (**Figure 1**). A phlebogram revealed a deep venous thrombosis of the popliteal- and femoral vein with drainage via the superficial veins. Angiography revealed an arteriovenous (AV) malformation in the left groin, fed by branches of the left external iliac artery. There was significant arteriovenous shunting resulting in reversal of the flow in the left femoral vein (**Figure 2**).

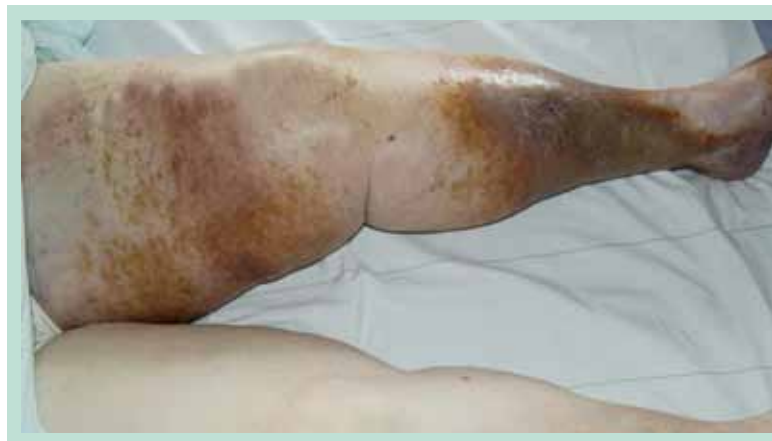

FIGURE 1 : Swollen left leg to the groin with pitting and non-pitting oedema, hyperpigmentations and with two indurated painful erythematous lesions. Painful palpation. Stemmer's sign was positive on the left foot.

Kemperman P.M.J.H., de Haas E.R.M., Neumann H.A.M., dermatologists, Erasmus MC, department Dermatology, Postbus 2040, 3000 CA Rotterdam.

E-mail: p.kemperman@erasmusmc.nl

Accepté le 29 mai 2011

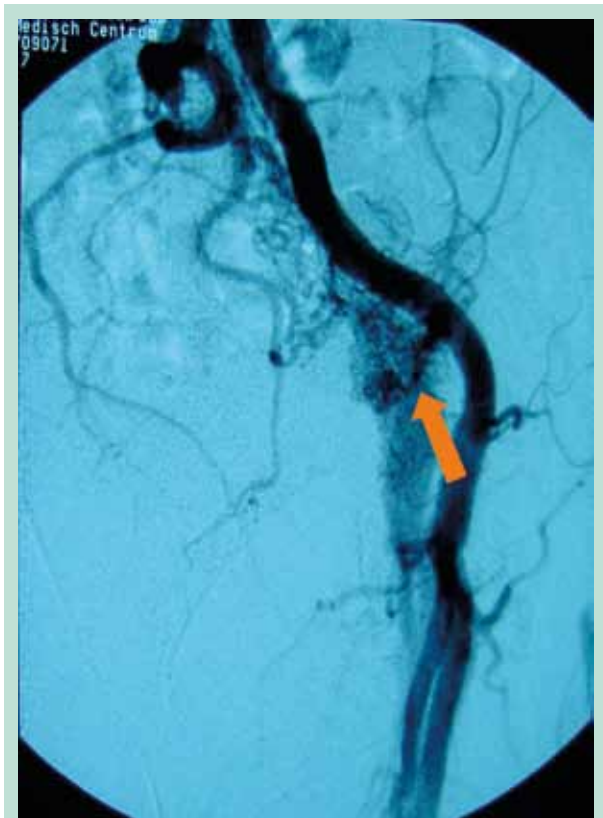


FIGURE 2 : Angiography: An AV malformation connecting the external iliac artery with the venous system resulting in retrograde venous flow.

The fistula was ligated distal from the femoral artery. Additional anticoagulation in combination with pneumatic compression resulted in decongestion of the left leg and decrease in pain.

Discussion

Descriptions of vascular malformations date from the 18th century. AV fistulas can be both from congenital and traumatic origin. Congenital AV fistulas can be idiopathic or seen as part of a congenital syndrome as Klippel-Trenaunay or von Hippel-Lindau disease. Most causes of traumatic AV fistulas are a result of penetrating injuries to arteries and veins [1]. Nowadays, most traumatic AV are due to medical procedures such as percutaneous biopsies, catheterizations or orthopaedic procedures. In times of war, AV fistulas often caused by stab wounds and blast injuries (shrapnel). Rarely, a fracture underlies the formation of an AV fistula.

The incidence of a traumatic AV fistula by vascular injury ranges from 2.3% to 3.9%.

The most frequent localization of AV fistulas concerns the extremities (with 17% involvement in the femoral vessels) and secondary vessels of the head and neck region. The clinical manifestation is caused by shunting of the arterial system to the venous system. Initially collaterals are formed at the site of the fistula due to a decreased distal arterial pressure. In severe cases, ischemia can occur [2].

Often the diagnosis of an AV fistula can be clinically made, although the fistula can be asymptomatic for years. The patient often has a history of trauma, particularly from a penetrating injury. Patients may develop symptoms of a pulsating swelling, pain and edema at the site of the fistula. Sometimes there is a souffle audible on auscultation. For long existing fistulas a pulsating mass can be felt in half of the patients. Edema, increased skin temperature and varicosis with signs of venous insufficiency may be present. The sign of Branham (a decrease in heart rate which is caused by manual compression of the fistula or the artery just proximal to the fistula) can be positive. The confirmation of an AV fistula may be done by Doppler examination, duplex scan, angiography, CT and MRI. However, angiography is the most appropriate research, it visualizes the size, location and hemodynamic effects at the site of the fistula. Asymptomatic AV fistulas usually require no intervention. The preferred therapy for symptoms is surgical correction of the flow. The fistula will be closed and the continuity of the artery and vein will be restored [3]. In some cases, embolization may be helpful when surgical reconstruction is not preferred.

Given the negative history of trauma or surgery in this case we are most likely dealing with a congenital AV fistula, which expired a long time without any symptoms. Due to thrombosis, proximal occlusion of the fistula in the deep venous system probably occurred resulting in a active shunt. Venous hypertension occurred resulting in a threatened limb. This case illustrates that a asymptomatic congenital arteriovenous malformation can result in a threatened leg in older age.

References

1. Bail H.J., Melcher I., Raschke M.J., Schroeder R.J., Schaser K.D. Unknown AV-fistula as reason for post-traumatic hematoma of the thigh. *J. Cardiovasc. Surg. (Torino)* 1984 Mar-Apr; 25(2): 165-72.
2. Weyrich G., Beck A. Traumatic fistula between internal iliac artery and external iliac vein. *Radiat. Med.* 1990 Nov-Dec; 8(6): 215-8.
3. Natali J., Jue-Denis P., Kieffer E., Benhamou M., Tricot J.F., Merland J.J., Riche M.C. Arteriovenous fistulae of the internal iliac vessels. *Vasa* 2003 May; 32(2): 108-10.