

Chapter 13

Use of intraoperative ultrasound in open varicose vein surgery (excluding endovascular techniques)

Denis Creton, Olivier Creton

Summary

In addition to endovascular techniques, intraoperative ultrasound is necessary mainly for intraoperative foam sclerosis in recurrence surgery. It is done in sterile environments at the very beginning of the operation in the anti-Trendelenburg position. It is greatly facilitated by the presence of the operating assistant who can aspirate, inject the serum, prepare the foam and inject it while the operator remains perfectly still the ultrasound probe in one hand and the needle and injection extender in the other.

Introduction

While ultrasound is essential for endovascular varicose vein surgery, it can be very useful in some circumstances in open varicose vein surgery.

Indeed, certain circumstances, obesity, visualization of a stripper, intraoperative injection of a sclerosing product, may require the assistance of an intraoperative ultrasound.

General principle of intraoperative ultrasound

It is important to be aware that the venous element sought will never be seen as well as preoperatively during the marking performed while standing.

Indeed, between the standing position and the supine position, the decrease in diameter of about 20% is even greater in small diameter veins (< 7 mm), which is a fairly common situation [1].

In addition, during the operation, the patient who is lying down has had his leg brushed and for this purpose, it has remained up for a certain time at 45° with a brushing of liquid product at room temperature, therefore colder than the leg; as a result, often the venous elements are still much less visible than when standing.

In order to optimize the visualization of the vein concerned, it will be necessary to immediately, at the beginning of the operation, put the patient on anti-Trendelenburg and perform the procedure requiring the use of the ultrasound scanner at the very beginning of the operation in this position, before the operation (phlebectomies, stripping or venous ligation approach), which will be performed in the Trendelenburg position.

When installing the patient, the ultrasound probe should generally be placed in a sterile camera cover (Hartmann Foliodrape Heidenheim Germany) with sterile gel inside (Fig. 1).

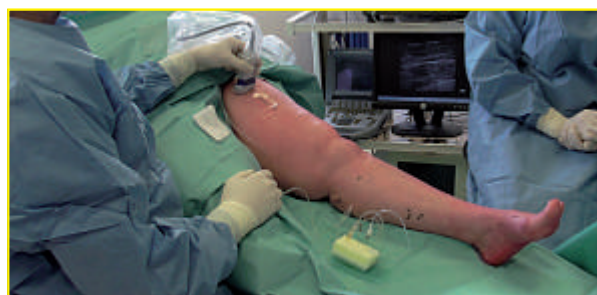

Fig. 1: Ultrasound probe and patient installation.

Use of intraoperative ultrasound in open varicose vein surgery (excluding endovascular techniques).

The ultrasound of the vessel concerned is performed with sterile gel. It is interesting to immediately orient the probe so that the lateral displacement of the probe corresponds to the same displacement of the probe on the ultrasound screen.

Right-handed people usually stand to the right of the patient with the ultrasound screen facing the patient's left (**Fig. 1**). In this way, the operator holding the probe in his left hand has his right hand to perform puncture procedures.

Since the gesture is performed in bright light, do not hesitate to change the value of the gain or contrast according to the position light. Color mode or Doppler mode are rarely used.

The exploration of the vessel, which is generally a trunk or a rectilinear varicose portion, is always highly preferable in cross-section because the slightest displacement of the probe always makes it possible to visualize the entire vessel concerned.

With the patient lying down, it is all the more important (low venous pressure) not to over-compress the vein with the probe.

Longitudinal cross-sectional exploration is rarely necessary (visualization of the passage of a guide, catheter or stripper through a venous trunk).

To obtain this longitudinal cut, the easiest way is to start from a cross section with the venous trunk perfectly in the middle of the screen and then slowly rotate the probe 90° on itself while keeping the vessel perfectly in cross section without moving it from the middle of the screen, we thus have quite quickly the same vision of the same vessel in longitudinal section.

The presence in the operating room of an assistant greatly facilitates the procedures requiring the use of ultrasound.

The operator, sitting with his elbow on the table, holding the probe on the patient's leg with one hand perfectly still, with his gaze fixed on the screen so as not to move, has two additional hands to perform the necessary movements.

Technical actions requiring the use of ultrasound

There are two frequent procedures that require the use of ultrasound in varicose vein surgery.

The introduction of a catheter (injection of sclerosing product in the form of foam, introduction of a flexible stripper for single use).

And direct puncture to inject a sclerosing product into a venous element that is inaccessible or not surgically accessible.

Placing a catheter

To place a catheter in a venous trunk, it must first be punctured with a small 18 Gauge cathelon (*Deltaven® Delta Med SpA- Via Rossa, 20 Viadana (Mn) Italy*).

The easiest way is to follow the procedure with a cross section of the trunk, in order to see the end of the needle (highlighted point) approaching (**Fig. 2**), which can be seen very clearly descending and then crossing the surface wall of the trunk to come exactly in the middle of the vein displayed in cross section (**Fig. 3**).

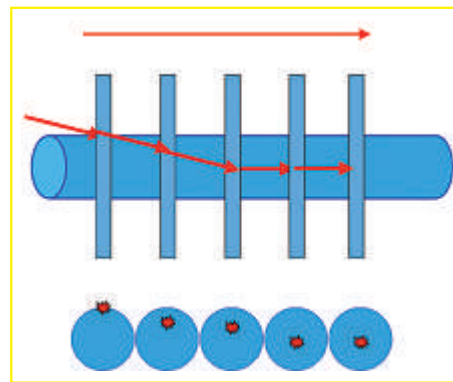


Fig. 2:
Schema of the
introduction
of a catheter
with transverse
echographic
control.

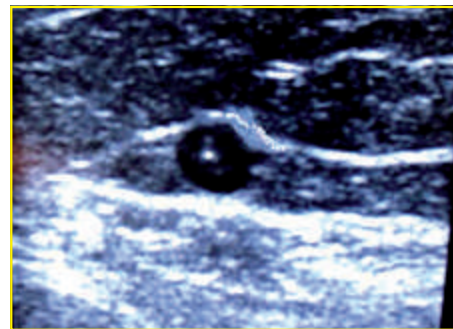


Fig. 3:
Highlighted
image of the tip
of the needle,
in the middle
of the venous
trunk.

Then, by pushing the needle, the highlighted point in the trunk must be advanced by keeping it precisely in the middle of the black ultrasound disc.

To have the best visualization of the highlight point corresponding to the end of the needle, the bevel must be oriented towards the radius or opposite the radius of the probe, i.e. towards the patient's skin or downwards [2, 3].

The plastic sheath is then pushed forward and the needle removed, usually the venous reflux is immediate. If there is no reflux, it may be that the plastic cathelon is pushed too far and touches the venous wall.

It is then sufficient to remove it by one or two millimetres to obtain a reflux.

The rest of the procedure is usual, passing a guide, then an introducer and a catheter of varying length in order to be able to deposit the sclerosing product foam in the intended place.

Monitoring this gesture by a cross section of the vessel is much safer because, even with a slight movement of the probe, the vessel always appears visible in its entirety with the bright point of the needle still as visible.

When we are in longitudinal section, the slightest movement of the probe by the movement of the hand makes the complete image of the vessel and the needle partially disappear.

| The introduction of sclerosing products

The introduction of sclerosing product by direct puncture into a surgically difficult trunk is also carried out with a transverse control of the vessel, i.e. it is seen in its entirety despite the inevitable small movements of the ultrasound probe.

The needle is inserted perpendicular to the trunk and very obliquely towards the vessel. The needle is followed in longitudinal section, it is perpendicular to the venous trunk concerned (Fig. 4).

The puncture is performed with a check of the needle in the plane of the ultrasound probe most obliquely, i.e. most parallel to the skin. It is with an angle between the needle and the ultrasound beam closest to 90° that the visualization of the needle is best [3-6]. To obtain a better angle between the needle and the radius, the probe can be tilted by pressing the skin on the side of the needle tip [6].

Of course, this manoeuvre has its limits because there is a risk of compressing the vein that you are trying to puncture.

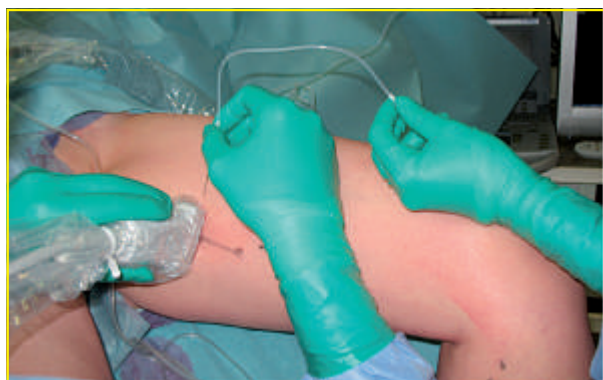

Fig. 4: Perpendicular puncture of the venous trunk with transverse ultrasound inspection of the trunk.

In addition, in this way (very oblique introduction of the needle) pressure/depression movements on the skin are less likely to cause the tip of the needle to come out of the vessel.

The needle is a black 22 Gauge needle. Smaller 20 or 22 G hands are significantly more visible than larger 17 or 18 G hands [7].

In order not to move the needle when injecting, it is safer to use a 25 cm extension tube (*Polytube, B Braun, D-34209 Melsungen*) filled with sodium chloride 0.09% and connected to a syringe maintained in slight depression by the operating aid.

In this way, the reflux is immediately visible as soon as the needle tip is correctly positioned, it is then very important to inject liquid to make sure that the entire needle bevel is in the vessel, you can see the liquid swirling in the vessel. If the needle has moved, the liquid then spreads around the vessel like a tumescent liquid, the needle must be removed and started again at another location.

When everything is in place, the assistant prepares the foam and injects it, the passage of the foam is monitored at the ultrasound (Fig. 5, 6).

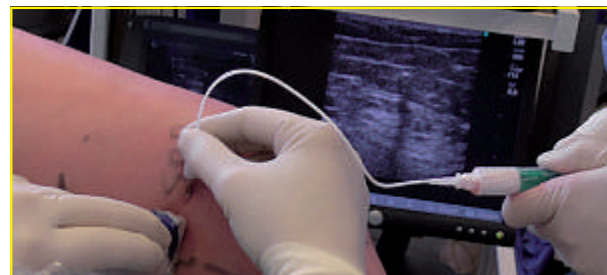


Fig. 5: Perpendicular puncture of the venous trunk with transverse ultrasound inspection of the trunk, injection of foam by the operating aid.

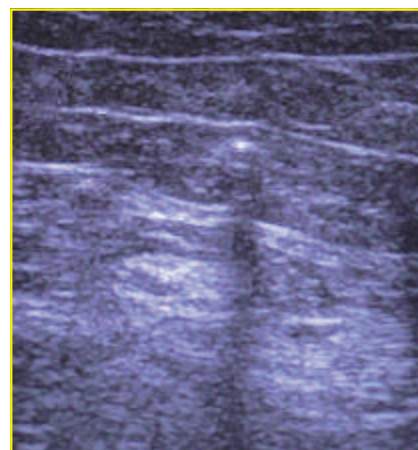


Fig. 6: Ultrasound inspection of the injection of foam.

Use of intraoperative ultrasound in open varicose vein surgery (excluding endovascular techniques).

Sclerosis of a saphenous trunk or a rectilinear accessory trunk can also be achieved by introducing under ultrasound a long catheter of the angiocath 4F type (*Super Torque, Johnson & Johnson & Johnson Company, Cordis Europa NV, Oosteinde 8, NL-9301 LJ Roden*) through the portion of the trunk externalized by a simple phlebectomy.

An epidural anesthesia catheter with an outside diameter of 1 mm may be useful when the trunk is narrowed (*Vygon, 95440, F-Ecouen*). The correct positioning of the catheter tip is controlled by intraoperative Doppler ultrasound.

The catheter is clearly visible with a 10 Mhz probe and the liquid injection allows a clear view of the swelling of the vein around the catheter, which ensures the perfect positioning of the catheter tip.

It is important to fill the catheter lumen with liquid (ClNa) before introducing it, on the one hand to see the reflux faster and on the other hand not to inject air before the foam; the same volume of liquid will be injected afterwards to empty the catheter of all the foam. Foam injection is usually performed in parallel with the catheter removal [8]. When a vein or varicose vein can be externalized by a phlebectomy incision, the introduction of foam can be easily done by a small catheter 18 Gauge (*Deltaven® Delta Med SpA-Via Rossa, 20 Viadana (Mn) Italy*).

The injection is carried out directly or through a communicating vein. The reflux is easily visible and the injection is easy by pinching the vein and catheter between 2 fingers to direct the foam injection (**Fig. 7, 8**). The progression of the foam is also monitored by ultrasound.

After these gestures, the table can be placed in the Trendelenburg position to continue the intervention.

| Local anaesthesia tumescent

The ultrasound scanner can also be used, especially in obese people, to facilitate tumescence during stripping in order to inject the tumescent liquid rigorously around the stripper already introduced into the saphenous trunk to be stripped. When using a pin-Stripper, it is rarely necessary to use the ultrasound because it feels very good under the skin.

| Stripper location

The ultrasound scanner can also be used to locate the end of the stripper in the inguinal region in order to facilitate its extraction by a mini incision when it is introduced from bottom to top (**Fig. 9**).

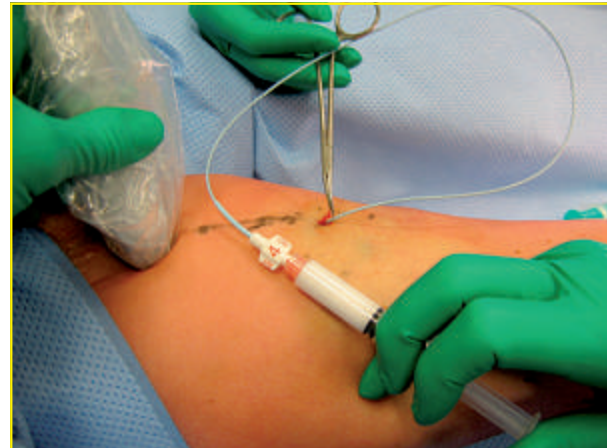

Fig. 7: Injection of foam by catheter introduced into a vein extracted by phlebectomy.

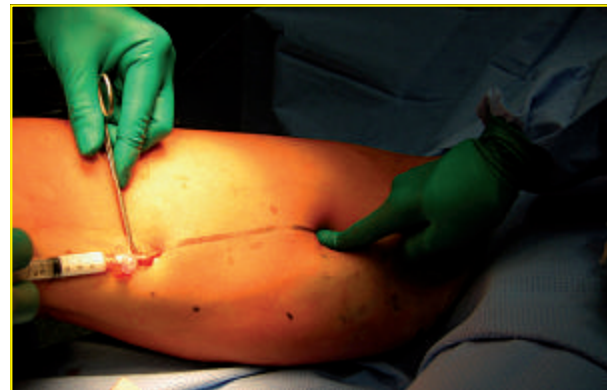

Fig. 8: Injection of foam by catheter introduced into a vein extracted by phlebectomy.

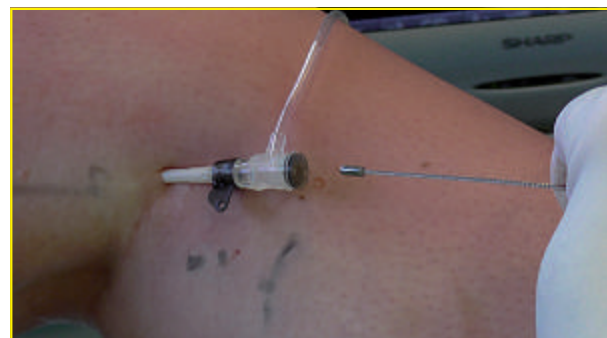

Fig. 9: Introduction of a single-use stripper into the saphenous trunk by a 19F introducer.

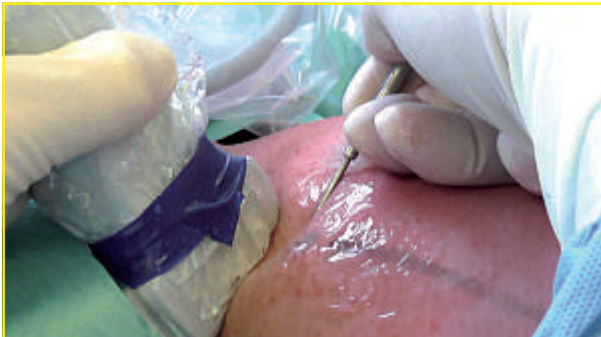

Fig. 10: Inguinal exteriorization of the saphenous trunk with ultrasound monitoring.

Echo-assisted phlebectomy

The extraction of the saphenous trunk below the butt can also be facilitated by ultrasound visualization as Stefano Ricci has described it well [9, 10].

About 3 cm below the sapheno femoral junction, the saphenous trunk is located under ultrasound where it runs along the long adductor muscle.

At this point the trunk rests on the muscle fascia away from arterial, nervous or lymphatic elements. The skin anaesthesia must be very superficial so as not to interfere with deeper ultrasound vision.

The trunk can be extracted by a mini incision and a curved clamp or dissector under ultrasound control (**Fig. 10**).

After sectioning and ligating the proximal part, the distal part is used for stripping or trunk sclerosis.

The percutaneous endoclip

Ultrasound will also be used to place percutaneous clips that may be useful in the Chiva method or to close veins during sclerosis.

These clips (*Amsel Occluder*) are not yet available for sale.

In pigs, 30 vessels from 1.8 to 12.7 mm were effectively closed by placing this clip introduced by percutaneous puncture under ultrasound guiding [11].

Indications requiring the use of intraoperative ultrasound

Intraoperative ultrasound is mainly used in the surgery of recurrences [12-14].

In 2011 and 2012, out of 160 and 162 recurrences, 62% required the use of intraoperative ultrasound for intraoperative sclerosis.

Today, almost all procedures for varicose recurrences involve foam sclerosis at the beginning of the procedure, which essentially involves phlebectomies.

Intraoperative sclerosis makes it possible to do what the surgical procedure cannot do: closure of lympho-ganglionic veins, neovascularization veins, truncal recanalizations.

It also makes it possible to simplify the surgical procedure: treatment of incontinent residual trunks, closing of perforators.

For first time surgery, simultaneously with phlebectomies, in order to avoid stripping and inguinal incision, ultrasound may be necessary to sclerose the trunk of an anterior accessory saphenous vein or a Giacomini vein with undrained retrograde reflux or to extract the end of the stripper introduced from below into the saphenous vein during the procedure.

Overall, the use of ultrasound in first time surgery is very rare.

Bibliography

- [1] Van der Velden S.K., De Maeseneer M.G., Pichot O., Nijsten T., van den Bos R.R. Postural diameter change of the saphenous trunk in chronic venous disease. *Eur J Vasc Endovasc Surg.* 2016; 51: 831-7.
- [2] Hopkins R.E., Bradley M. In-vitro visualization of biopsy needles with ultrasound: a comparative study of standard and echogenic needles using an ultrasound phantom. *Clin Radiol.* 2001; 56: 499-502.
- [3] Bondestam S., Kreula J. Needle tip echogenicity. A study with real time ultrasound. *Invest Radiol.* 1989; 24: 555-60.
- [4] Culp W.C., McCowan T.C., Goertzen T.C., Habbe T.G., Hummel M.M., LeVeon R.F., Anderson J.C. Relative ultrasonographic echogenicity of standard, dimpled, and polymeric-coated needles. *J Vasc Interv Radiol.* 2000; 11: 351-8.
- [5] Deam R.K., Kluger R., Barrington M.J., McCutcheon C.A. Investigation of a new echogenic needle for use with ultrasound peripheral nerve blocks. *Anaesth Intensive Care.* 2007; 35: 582-6.

Use of intraoperative ultrasound in open varicose vein surgery (excluding endovascular techniques).

- [6] Schafhalter-Zoppoth I., McCulloch C.E., Gray A.T. Ultrasound visibility of needles used for regional nerve block: an in vitro study. *Reg Anesth Pain Med.* 2004; 29: 480-8.
 - [7] Chin K.J., Perlas A., Chan V.W.S., Brul R. Needle visualization in ultrasound-guided regional anesthesia: Challenges and Solutions. *Regional anesthesia and Pain Medecine* 2008; 33: 532-44.
 - [8] Milleret R., Garandeau C. Sclérose des grandes veines saphènes à la mousse délivrée par cathéter écho-guidé sur veine vide : Alpha-Technique, Bilan des 1000 premiers traitements. *Phlébologie* 2006; 59: 53-8.
 - [9] Ricci S., Moro L., Antonelli Incalzi R. Ultrasound assisted great saphenous vein ligation and division: an office procedure. *Veins and Lymphatics* 2014; 3: 4428.
 - [10] Ricci S., Moro L., Ferrini A., Rossi Bartoli I., Antonelli Incalzi R. The E point: a new echographic great saphenous identification sign in specific anatomical variants and applications. *Phlebology.* 2016 Feb 22. pii: 0268355516633381. [Epub ahead of print]
 - [11] Miller A., Lilach N., Miller R., Kabnick L. A novel secure vessel occluder for minimally invasive and percutaneous treatments. *J Vasc Surg.* 2014; 59(6, Supplement):89S.
 - [12] Creton D., Uhl J.F. Sclérothérapie à la mousse dans la chirurgie des varices. Résultats précoces : 130 cas. *Phlébologie* 2005; 58: 343-8.
 - [13] Creton D., Uhl J.F. Foam sclerotherapy combined with surgical treatment for recurrent varicose veins: short term results. *Eur J Vasc Endovasc Surg.* 2007; 33: 619-24.
 - [14] Creton D., Uhl J.F. La sclérothérapie à la mousse dans la chirurgie des varices. *In: Gobin J.P., Benigni J.P. (eds), Sclérothérapie et Maladie veineuse chronique superficielle.* Eska éditions, 2007, Paris, pp. 167-73.
-